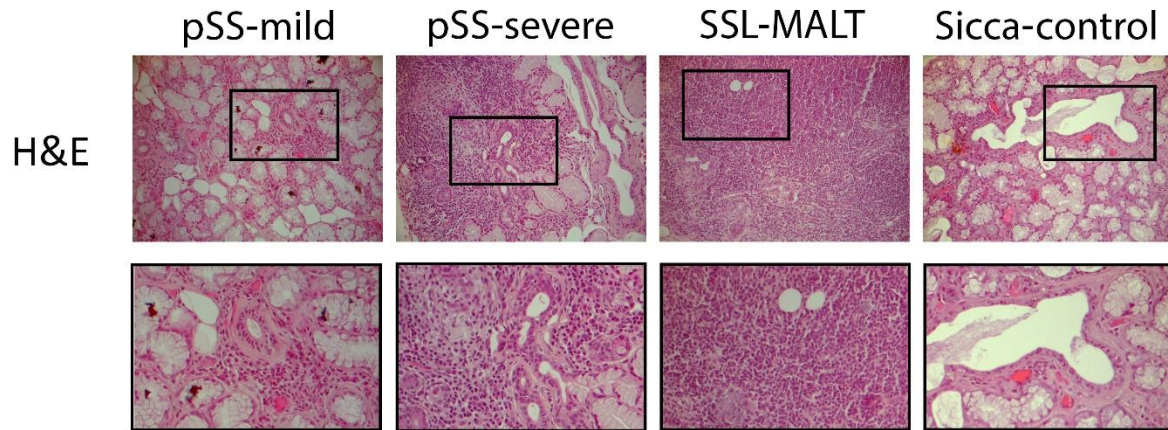


Supplementary Figure



Suppl. Figure S1. Representative pictures of Hematoxylin and Eosin staining of the MSGs of pSS patients with mild or severe MSG inflammatory infiltrates (pSS-mild and pSS-severe, respectively) or with NHL (SSL), as well as a sicca-complaining control (*sicca-control*). The lower panel represent detail of pictures presented in the upper panel (square). The pictures correspond to those presented in Figure 1. Original objective magnification: x20.