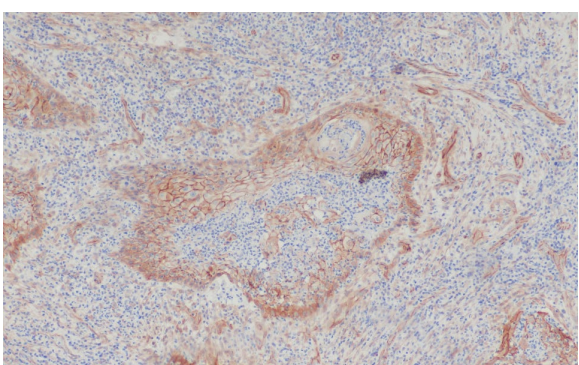
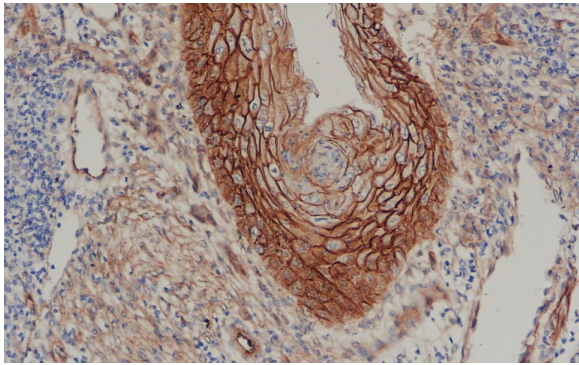
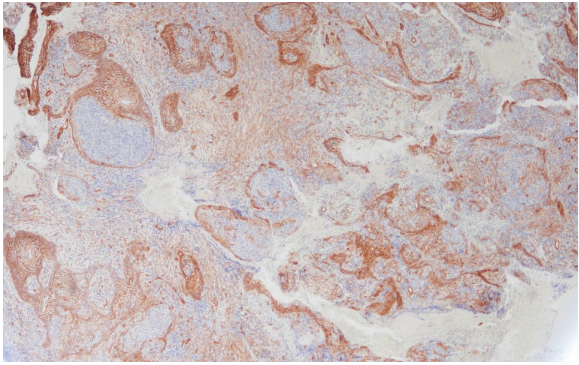
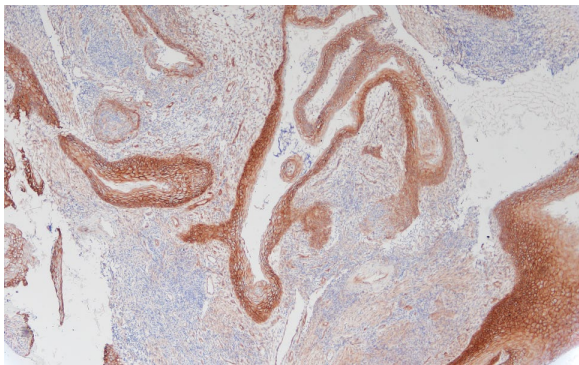


Supplementary Figure 1

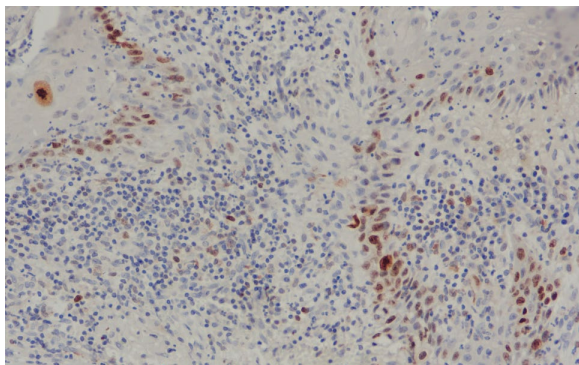
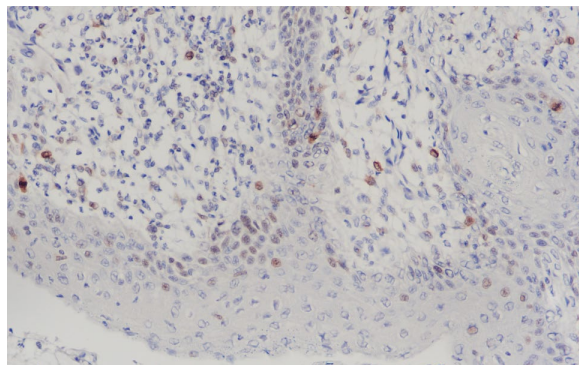
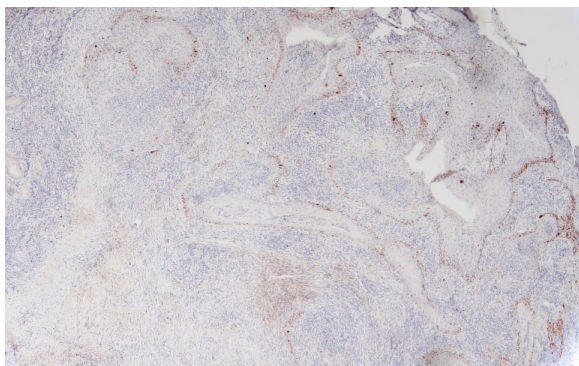
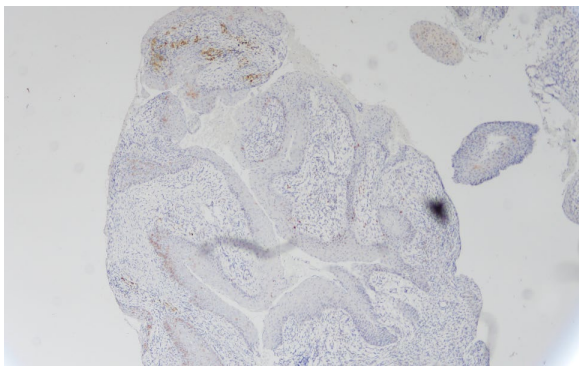
A: B-Catenin

Initial lesion

Recurrent lesion

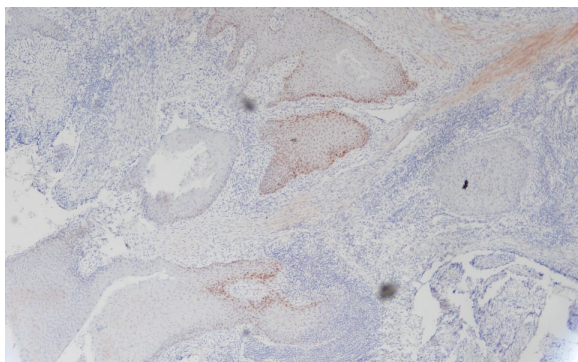


B: Ki67

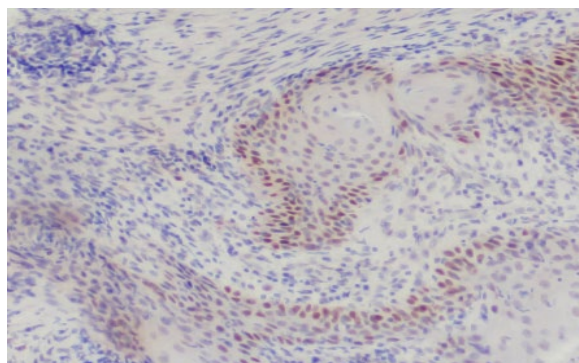
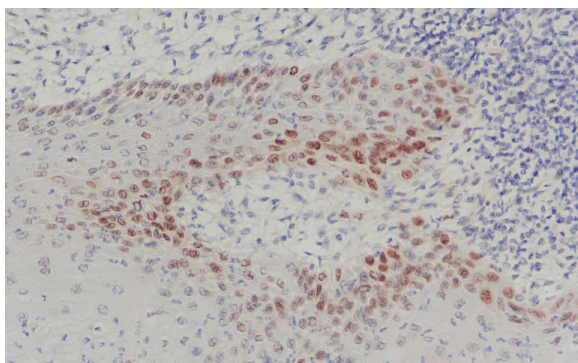
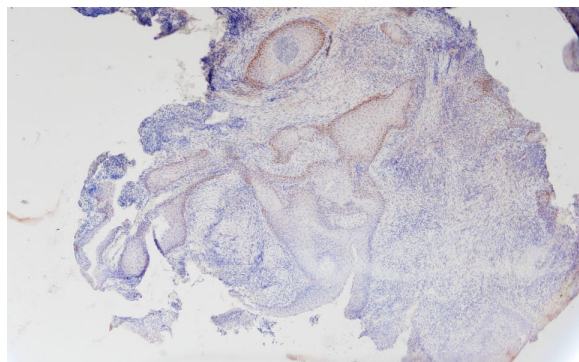


C: P53

Initial lesion



Recurrent lesion



Supplementary Figure 1. Immunohistochemistry expression of β -catenin (A), Ki67 (B) and P53 (C) in the initial and recurrent lesion. Membrane β -catenin delocalization (A) as well as an increase in the expression of Ki65 (B) and P53 (C) is observed in the recurrent lesion.