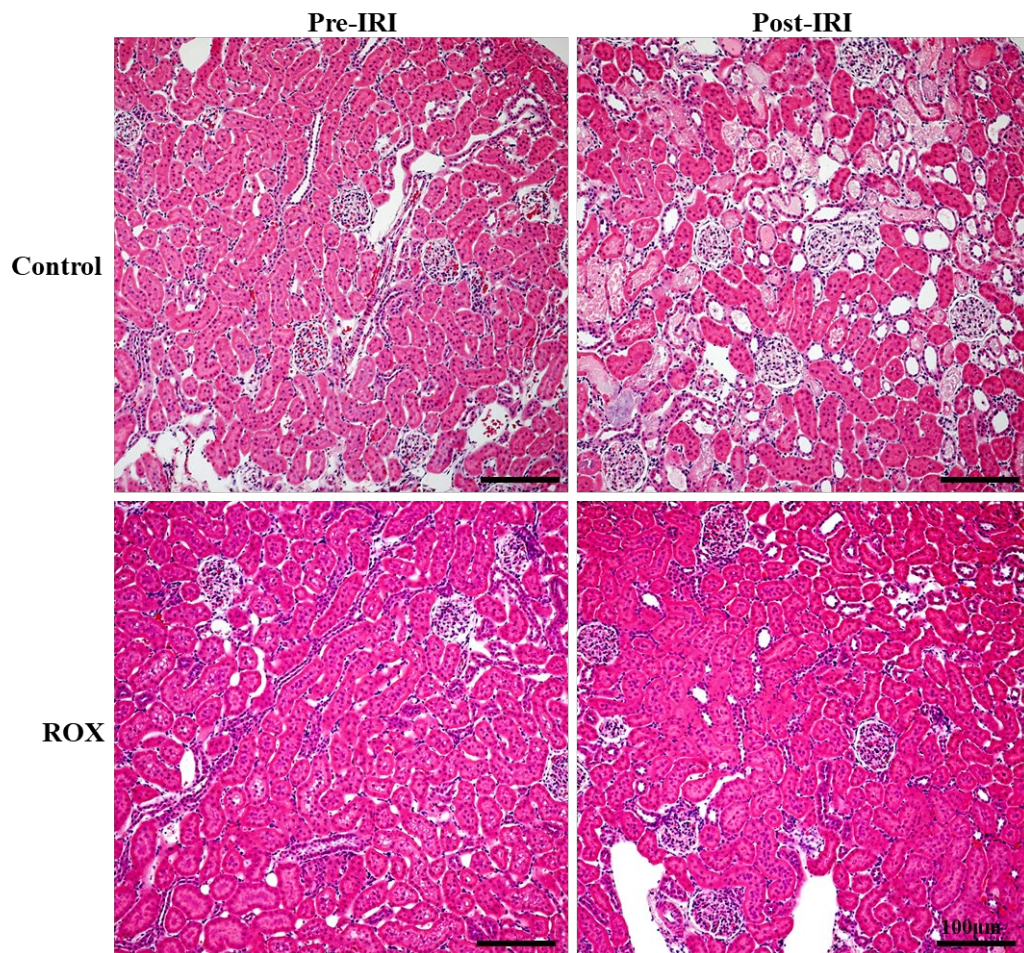


Supplementary file



Supplementary Figure S1. HE staining of kidney pre- and post-IRI.

Proximal tubules were damaged by IRI. Glomerulus was not damaged by IRI. 24 hr ROX decreased the damages in proximal tubules.