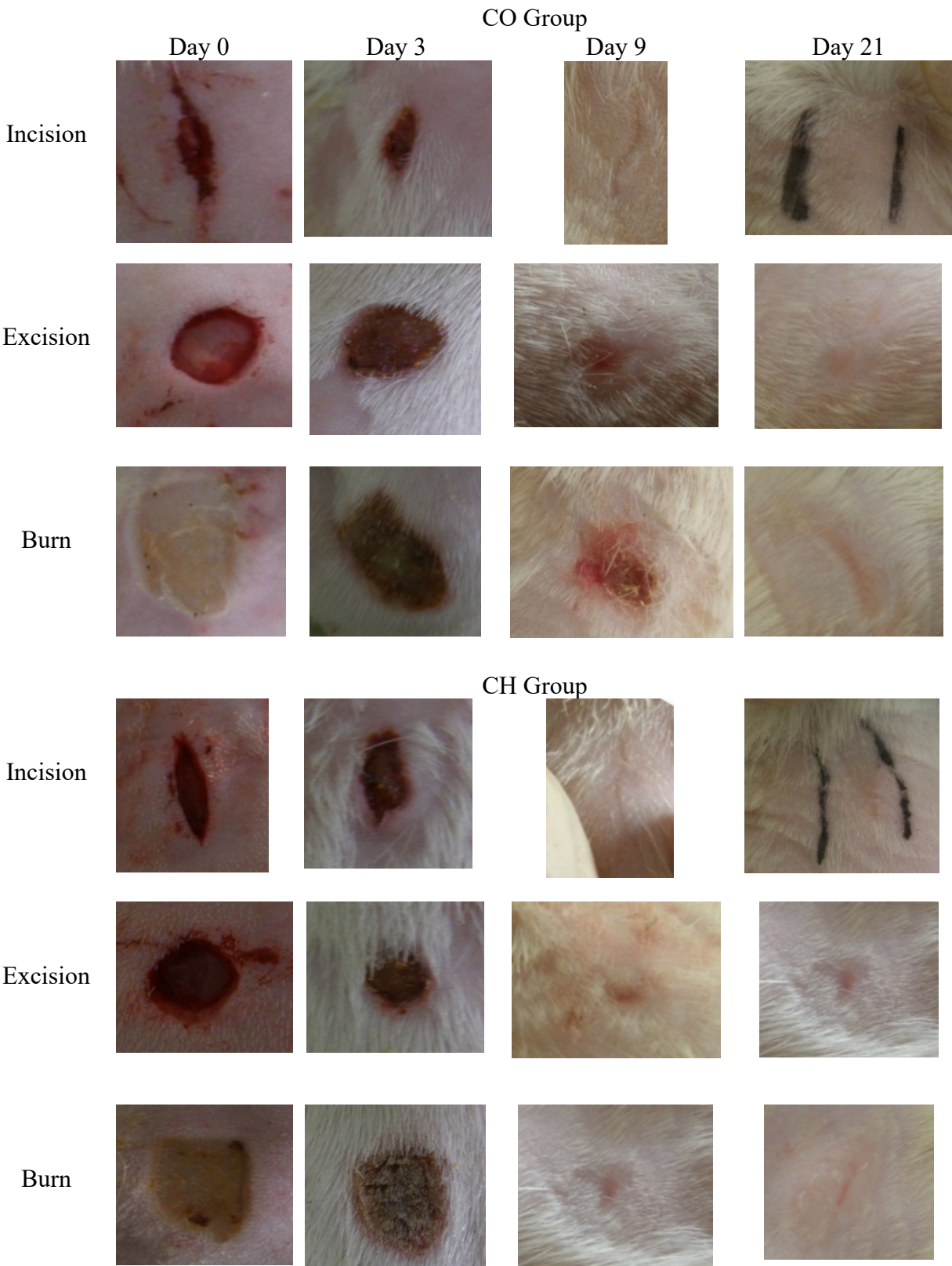
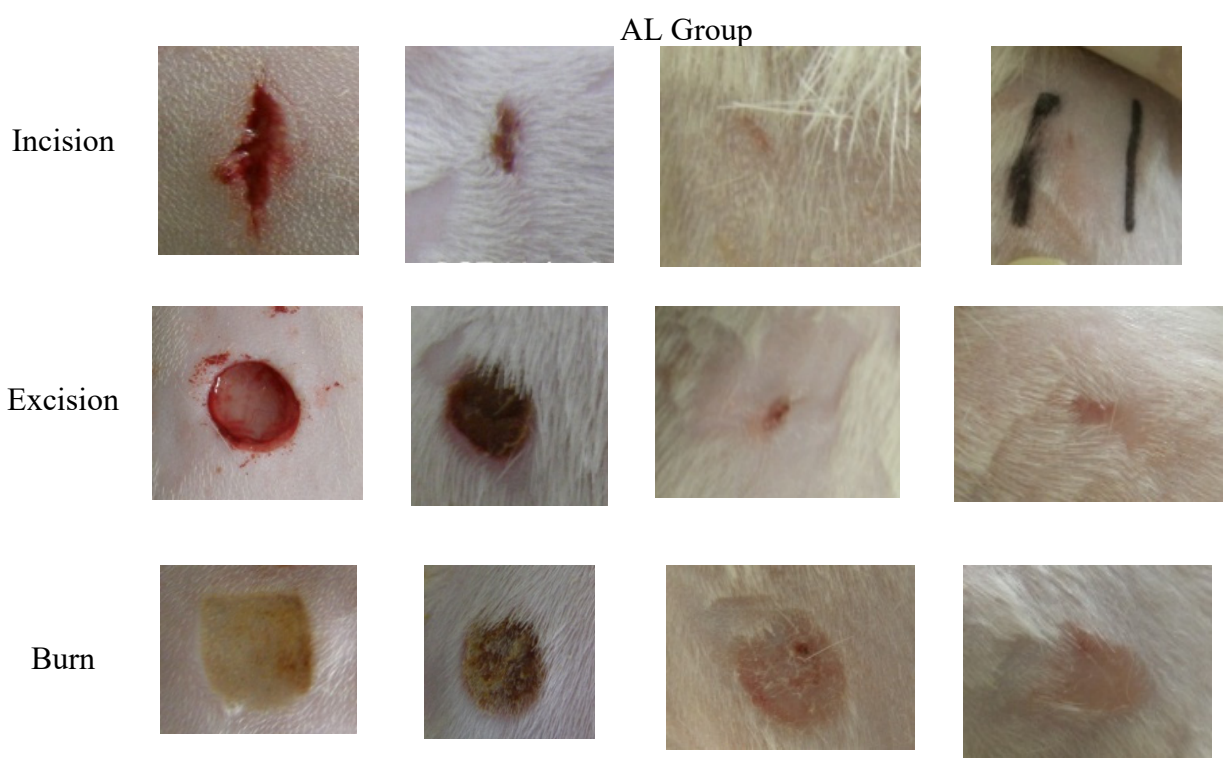
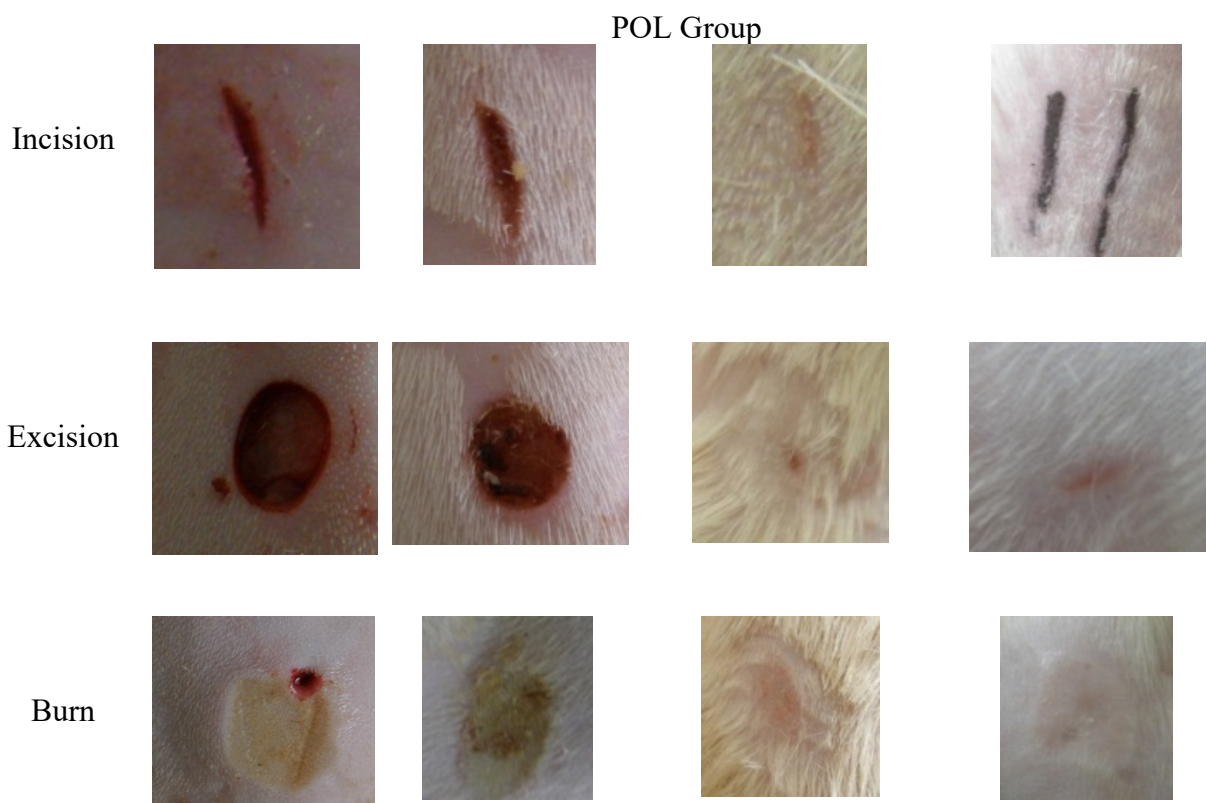


Figure S1. Macroscopic pictures of the cutaneous lesions.





CO group (treated with the collagen ointment), CH group (treated with the chitosan ointment), POL group (treated with the ointment based on the mixture of polymers), AL group (treated with the ointment based on the lyophilized egg white)