

## Cystic lymph node metastasis in papillary thyroid carcinoma

Edita Mišeikytė-Kaubrienė, Mantas Trakymas, Albertas Ulys

Department of Interventional Sonoscopy and Ultrasound Diagnostics, Institute of Oncology,  
Vilnius University, Lithuania

**Key words:** papillary thyroid cancer; lymph nodes; cystic lymph nodes; ultrasound; ultrasound-guided fine-needle aspiration biopsy.

**Summary.** *Background.* Thyroid cancer, especially papillary carcinoma, metastasizes most often into cervical lymph nodes. Cervical ultrasound and ultrasound-guided fine-needle aspiration biopsy are the most sensitive modalities in detecting locoregional neck recurrence. *Objective.* The aim of this study was to illustrate the ultrasound spectrum of lymph node metastases from papillary thyroid carcinoma.

*Patients and methods.* During 1998–2002 years due to suspicion of recurrence of thyroid cancer, 75 ultrasound-guided fine-needle aspiration biopsies of regional lymph nodes were performed. Ultrasound examination of 75 patients with thyroid cancer (56 women and 19 men; mean age of patients was  $54.67 \pm 12.89$  years) was performed. All biopsies were performed on nonpalpable lesions (lymph node short axis  $\leq 1.5$  cm).

*Results.* A total of 75 ultrasound-guided fine-needle aspiration biopsies of regional lymph nodes under suspicion of malignancy were performed. Only 5 (6.7%) of the 75 lymph nodes were cystic with internal septation. Other 70 (93.3%) lymph nodes were solid. Cytopathological results of 75 ultrasound-guided fine-needle aspiration biopsies from regional cervical lymph nodes were noninformative in 4 (5.3%) cases, benign – 40 (53.4%), suspicion – 4 (5.3%), and malignant – 27 (36.0%) cases. Eighteen patients underwent surgery for regional lymph nodes. All cystic metastases were confirmed to be papillary thyroid carcinoma on pathologic examination.

*Conclusion.* Ultrasound cannot exactly distinguish benign from malign lesions, but sonographic appearance can suggest malignancy and help in selection of the correct lymph nodes to aspirate with ultrasound-guided fine-needle aspiration biopsy. Cystic lymph node metastases may occur in papillary thyroid carcinoma. Cystic neck lesion patients with thyroid papillary carcinoma should always be verified with fine-needle aspiration biopsy.

### Background

Papillary thyroid carcinomas represent 85–90% of all thyroid carcinomas. Thyroid papillary cancer metastasizes most often into cervical lymph nodes. Cervical ultrasound and ultrasound-guided fine-needle aspiration biopsy are the most sensitive modalities in detecting locoregional neck recurrence. Early detection of metastases is of great clinical importance because it enables more successful surgery and radiation therapy treatments. Ultrasound is the imaging method of choice for detecting and characterizing cervical lymphadenopathy in patients with thyroid cancer. Additionally, it provides the ability to perform ultrasound-guided fine-needle aspiration biopsy, which provides information about the nature of the pathologic process (1). Normal cervical lymph nodes are rarely visualized by ultrasound. Malignant lymph nodes have typical ultra-

sonographic morphologic characteristic (2). Malignant lymph nodes are described as being round and of a heterogeneous structure with loss of the hilum – commonly hypoechoic with a loss of the hilum, sometimes with cystic degeneration or calcifications (3). Nodal metastases of papillary carcinomas can appear either as solid or cystic masses. Approximately 40% of all lymph node metastases from papillary thyroid carcinomas have tendency to cavitate a lymph node by cystic degeneration completely (4). Although solid metastases do not represent a diagnostic problem, cystic lymph node metastases might be misinterpreted as a benign cervical cystic mass (4, 5).

### Materials and methods

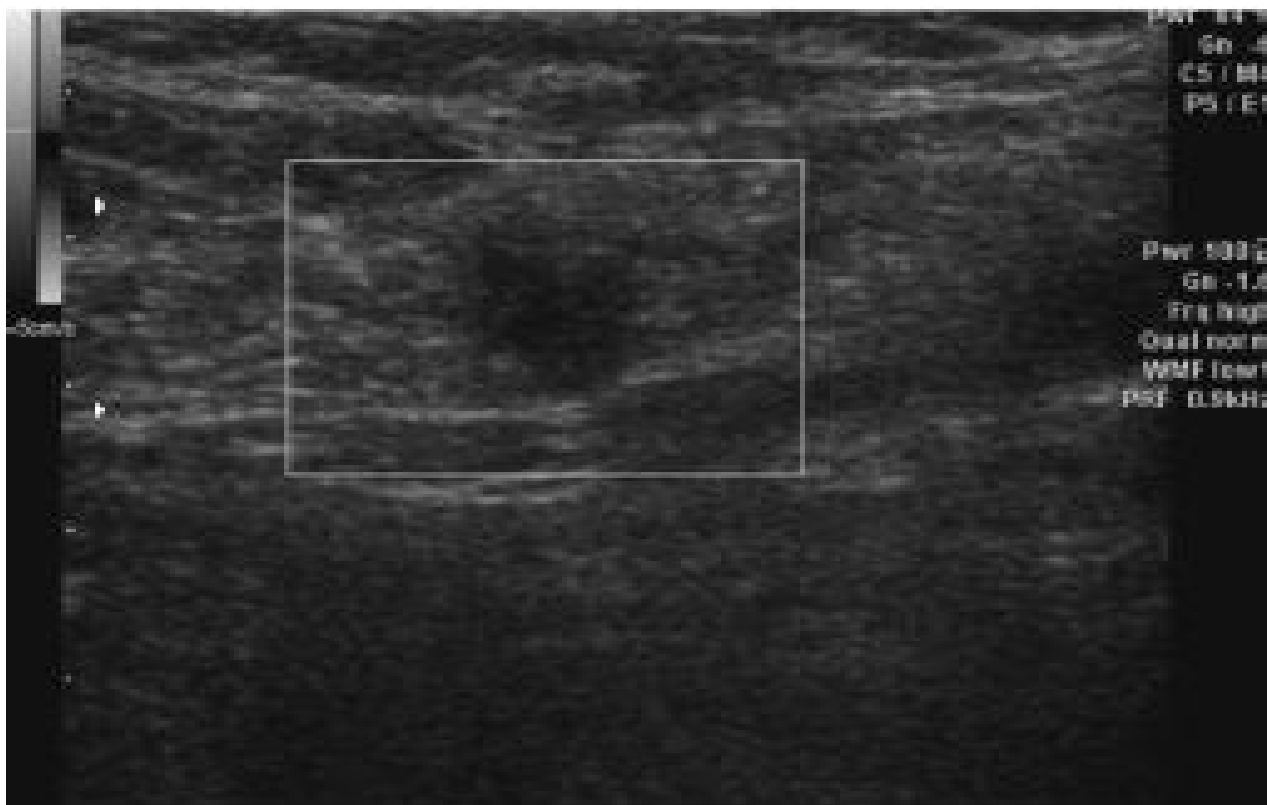
Study was performed during 1998–2002 at the Department of Interventional Sonoscopy and Ultrasound

Diagnostics of Institute of Oncology, Vilnius University. The following study inclusion criteria for the patients undergoing ultrasound examination with suspected thyroid cancer recurrence were used: patients after thyroidectomy for thyroid cancer, specific echogenic signs of malignancy in regional cervical lymph nodes at ultrasound examination, changes in regional cervical lymph nodes where not palpable (diameter <1.5 cm). Mean age of patients was  $54.67 \pm 12.89$  years (mean  $\pm$  standard deviation). A total 56 female and 19 male patients were investigated. All patients suffering from papillary and follicular thyroid cancer underwent thyroidectomy and  $I^{131}$  ablation. Ultrasound examination was performed using Voluson 730 (Kretztechnik AG) ultrasound system with SP 6–12 wide band linear probe. No special needle guide probes were used. Biopsy was performed using 21-gauge, 4.0 cm length needles. Syringes of 20 mL were used for aspiration. Aspiration biopsy material from regional cervical lymph nodes was prepared for cytology examination using conventional blood smear preparation method. Slides were air-dried and stained using Giemsa staining method. Adequacy of the aspirate was evaluated by cytopathologist according to its cellular composition quality and in correlation

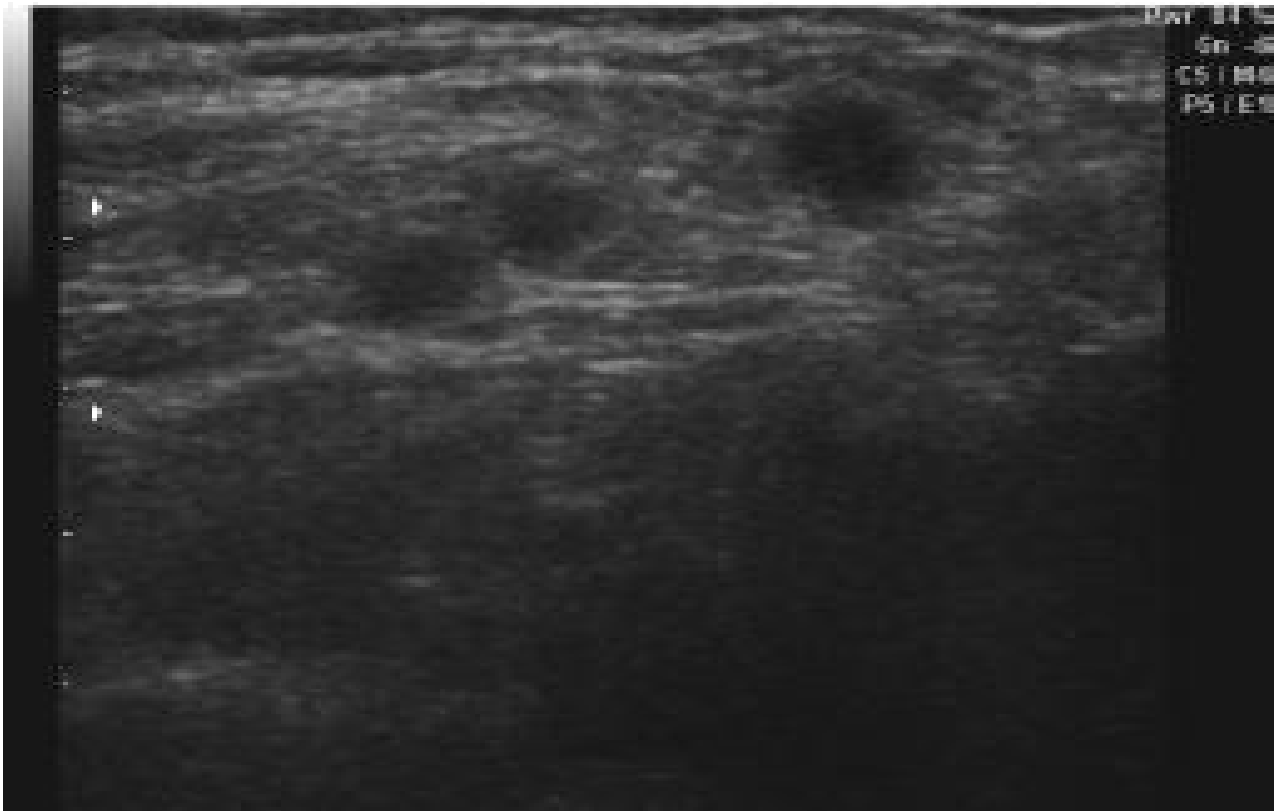
with clinical data. Cytological results of fine-needle aspiration biopsy from regional cervical lymph node were divided into following groups: noninformative specimen, benign changes, suspicion of the cancer, and malignant changes. All cytological and post-operative histological examinations were performed in National Center of Pathology. All patients undergoing operation and  $I^{131}$  ablation were treated in Institute of Oncology, Vilnius University. A total 75 ultrasound-guided fine-needle aspiration biopsies were performed when thyroid cancer recurrence was suspected.

### Results

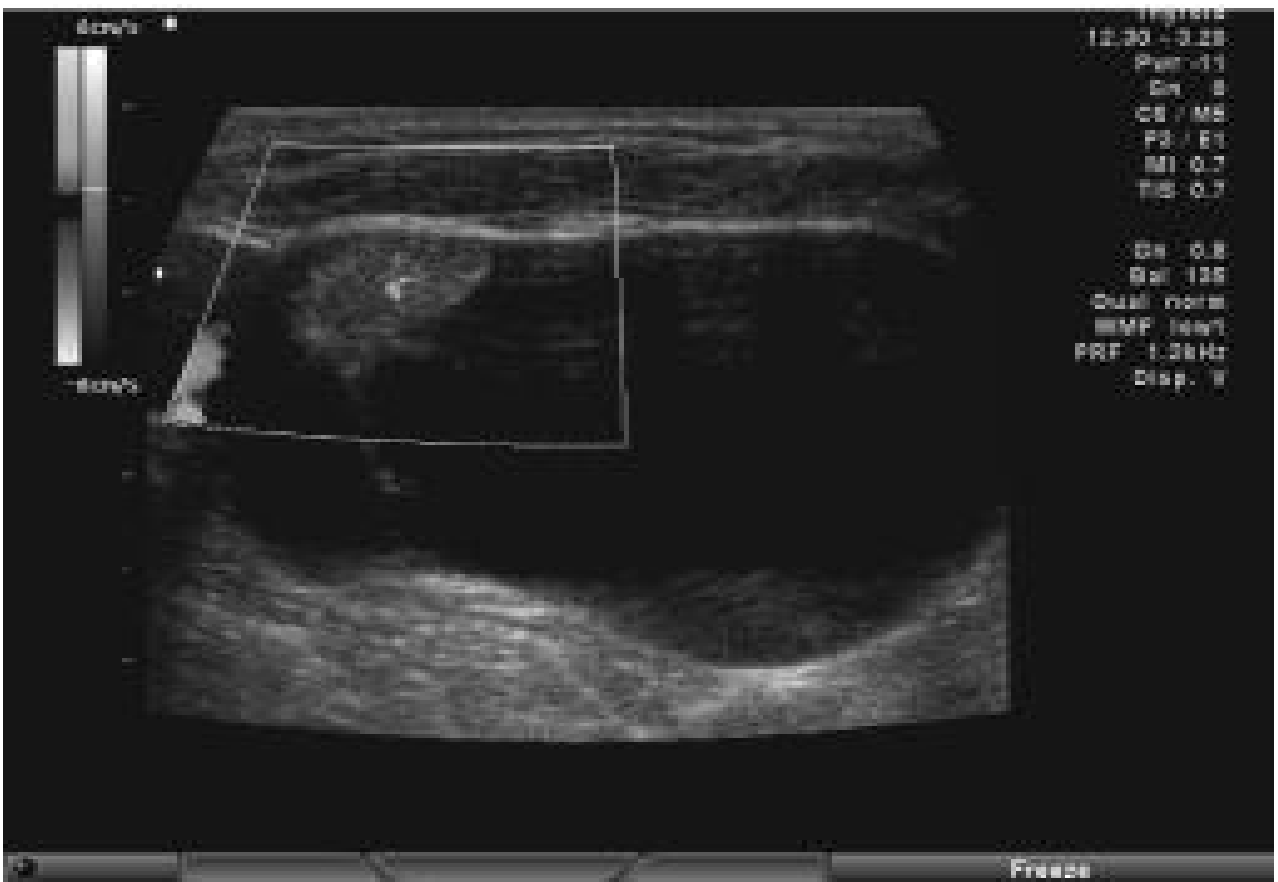
Primary diagnosis was papillary cancer in 60 (80%) cases, follicular – 4 (5.3%), medullary cancer in 10 (13.4%) cases, and 1 (1.3%) case of anaplastic cancer. All 75 nodal lesions were defined as metastases sonographically (Figs. 1–3). The lymph nodes were ipsilateral in 65 (86.7%) of 75 patients and bilateral in 10 (13.3%) patients. Lymph nodes ranged in size from 0.6 to 1.5 cm (mean, 1.2 cm) in long axis and from 0.5 to 1.4 cm (mean, 1.0 cm) in short axis, as calculated by ultrasound. Most of the lymph nodes (38 [50.7%]) were located in IV level, 26 (34.7%) of



**Fig. 1.** Sonogram of solid lymph node metastases



**Fig. 2.** Sonogram of solid lymph node metastase



**Fig. 3.** Sonogram of cystic lymph node metastases

75 in V level, 11 (14.6%) – in III level (lateral compartment). Cytopathological results of 75 ultrasound-guided fine-needle aspiration biopsies from regional cervical lymph nodes were non-informative in 4 (5.3%) cases, benign – 40 (53.4%), suspicion – 4 (5.3%) and malignant – 27 (36.0%) cases. Only 5 (6.7%) of the 75 lymph nodes were cystic with internal septation. Other 70 (93.3%) lymph nodes were solid. Calcifications were found in 10 (13.3%) nodes, of which 10 (100%) were metastases. A central echogenic hilum was visible in 4 (5.3%) of 40 benign nodes. However, in malignant nodes, a hilum was seen in only 1 (3.7%). Cytopathological results of all cystic lymph nodes were malignant – papillary metastases. The aspirated fluid of cystic lymph nodes was dark and viscous. No complications occurred during and after fine-needle aspiration biopsy. Radical lymphadenectomy was performed in 18 of these patients. Post-operative histological examination showed recurrence of differentiated thyroid tumor in regional cervical lymph nodes for 18 (100%) patients: 12 cases of papillary thyroid cancer, 1 case of follicular cancer, and 5 cases of medullary cancer. All cystic metastases were confirmed to be papillary thyroid carcinoma on pathologic examination. In 56 (74.7%) of 75 patients, adjunct radiotherapy was performed.

### Discussion

Metastatic lymph nodes may have a variety of appearances and fine-needle aspiration biopsy is often helpful for confirmation. Findings suggestive for metastases include round rather than oval shape, absence of an echogenic hilum, microcalcification within lymph nodes, cystic areas within lymph nodes, peripheral rather than central blood flow on color Doppler imaging (2, 6, 7). Normal lymph nodes are difficult to detect by ultrasound because of their high echogenicity, which is similar to that of the surrounding fat tissue (7). Because of their anatomic position, enlarged cervical lymph nodes are not easily palpable, especially when they are small and located behind sternocleidomastoid muscles, deep in the paratracheal region, or behind a carotid artery or jugular vein (7). Moreover, because of their biological behavior, radio-

iodine does not accumulate in these lymph nodes (8). Papillary and follicular thyroid cancer rarely metastasize to I level cervical lymph nodes; II level is affected in 52 % of cases, III level – 57%, IV level – 49% and V level – 41% (9). Some authors advocate using lymph node size to distinguish benign from malignant lymph nodes (10). The size ranges for benign and malignant nodes overlap, and differentiation of those lesions could not be based on size alone (11). In several studies, cystic portions within a cervical lymph node were considered highly suggestive for metastatic papillary thyroid carcinoma (6, 10). We detected cystic portion in 6.7% of metastatic lymph nodes. All of them were metastases of papillary carcinoma. Cystic metastatic lymph nodes or solid lymph node metastases are easy to differentiate with ultrasound. However, it is more difficult to differentiate cystic lesions at the region of neck from benign cervical cysts such as branchial cysts. Most of cystic lymph node metastases must be distinguished from noninfected branchial cysts (5). The main sonographic features for a distinction from noninfected branchial cysts include the internal septations, internal nodules, and thick outer wall. These sonographic features have been reported to be found rarely in noninfected branchial cysts (5). Histologically, the internal septations were caused by solid, papillary structures (12). Cystic like pattern was seen in seromas. Another way to differentiate cystic lymph node metastases from benign cystic lesions is to identify the primary thyroid tumor. Whereas, in young patients with no visible primary tumor, any cervical cystic lesion is more likely to be addressed as a benign branchial cyst (4, 12).

### Conclusion

Ultrasound cannot exactly distinguish benign from malignant lesions, but sonographic appearance can suggest malignancy and help in selection of the correct lymph nodes to aspirate with ultrasound-guided fine-needle aspiration biopsy. Cystic lymph node metastases may occur in papillary thyroid carcinoma. Cystic neck lesion patients with thyroid papillary carcinoma should always be verified with fine-needle aspiration biopsy.

## Cistiniai pokyčiai kaklo limfmazgiuose sergant papiliniu skydliaukės vėžiu

Edita Mišeikytė-Kaubrienė, Mantas Trakymas, Albertas Ulys

*Vilniaus universiteto Onkologijos instituto Intervencinės echoskopijos ir ultragarsinės diagnostikos skyrius*

**Raktažodžiai:** papilinis skydliaukės vėžys, limfmazgiai, cistiniai pokyčiai limfmazgiuose, ultragarsinis tyrimas, ultragarsu kontroliuojama aspiracinė biopsija plona adata.

**Santrauka.** Skydliaukės vėžys, ypač papilinė karcinoma, dažniausiai metastazuoja į kaklo limfmazgius. Kaklo ultragarsinis tyrimas ir ultragarsu kontroliuojama aspiracinė biopsija plona adata yra informatyviausi diagnostikos metodai nustatant skydliaukės vėžio atkrytį kaklo limfmazgiuose.

*Tyrimo tikslas.* Įvertinti papilinio skydliaukės vėžio metastazių kaklo limfmazgiuose ultragarsinio tyrimo metu randamus pokyčius.

*Tyrimo medžiaga ir metodai.* 1998–2002 m. 75 pacientams, sergantiems skydliaukės vėžiu, atliktas ultragarsinis tyrimas bei sritinių kaklo limfmazgių ultragarsu kontroliuojama aspiracinė biopsija plona adata (56 moterys ir 19 vyrų; amžiaus vidurkis – 54,67±12,89 metų). Visos biopsijos atliktos esant nepalpuojamiems pokyčiams kaklo limfmazgiuose (diametras ≤1,5 cm).

*Rezultatai.* Įtarus skydliaukės vėžio atkrytį kaklo limfmazgiuose, atliktos 75 ultragarsu kontroliuojamos aspiracinės biopsijos plona adata. 5 (6,7 proc.) iš 75 tirtų kaklo limfmazgių cistinės struktūros buvo su vidinėmis pertvaromis. 70 (93,3 proc.) tirtų limfmazgių buvo solidinės struktūros. Ultragarsu kontroliuojamos kaklo sritinių limfmazgių aspiracinės biopsijos plona adata duomenys: neinformatyvūs 4 (5,3 proc.) atvejai, nepiktybiniai – 40 (53,4 proc.), įtartas vėžys – 4 (5,3 proc.) piktybiniai – 27 (36,0 proc.) atvejai. Visuose cistiškai pakitusiuose limfmazgiuose ikioperaciniu laikotarpiu citologiškai nustatyta piktybinių pokyčių. 18 pacientų atliktos radikali limfadenektomijos. Visi tiriamieji, kuriems rasta cistinių pokyčių kaklo limfmazgiuose, operuoti ir pooperaciniu histologiniu tyrimu jiems patvirtintos papilinio skydliaukės vėžio metastazės kaklo limfmazgiuose.

*Išvados.* Ultragarsiniu tyrimu negalima nustatyti pokyčių kaklo limfmazgiuose prigimties. Tačiau, įvertinus echosemiotinius piktybiškumo požymius, galima atpažinti tuos limfmazgius, kai būtina atlikti ultragarsu kontroliuojamą aspiracinę biopsiją plona adata. Cistinių pokyčių kaklo limfmazgiuose priežastis gali būti papilinė skydliaukės karcinoma. Tokiais atvejais būtina ultragarsu kontroliuojama aspiracinė biopsija plona adata bei citologinis pokyčių įvertinimas.

---

Adresas susirašinti: E. Mišeikytė-Kaubrienė, VU Onkologijos instituto Intervencinės echoskopijos ir ultragarsinės diagnostikos skyrius, Santariškių 1, 08660 Vilnius. El. paštas: emkaubriene@yahoo.com

## References

1. Mišeikytė-Kaubrienė E, Ulys A, Trakymas M. Piktybinės ligos dažnumas įtariamo vėžio (*suspitio*) citologinėje grupėje (nepalpuojamų skydliaukės mazgų ultragarsu kontroliuojama aspiracinė biopsija plona adata). (The frequency of malignant disease in cytological group of suspected cancer (ultrasound-guided fine-needle aspiration biopsy of nonpalpable thyroid nodules).) *Medicina (Kaunas)* 2008;44(3):189-194.
2. Koischwitz D, Gritzmann N. Ultrasound of the neck. *Radiol Clin North Am* 2000;38(5):1029-45.
3. Takashima S, Sone S, Nomura N, Tomiyama N, Kobayashi T, Nakamura H. Nonpalpable lymph nodes of the neck: assessment with US and US-guided fine needle aspiration biopsy. *J Clin Ultrasound* 1997;25:283-92.
4. King AD, Ahuja AT, To EW, Tse GM, Metreweli C. Staging papillary carcinoma of the thyroid: magnetic resonance imaging vs. ultrasound of the neck. *Clin Radiol* 2000;55:222-6.
5. Ahuja A, Ng CF, King W, Metreweli C. Solitary cystic nodal metastasis from occult papillary carcinoma of the thyroid mimicking a branchial cyst: a potential pitfall. *Clin Radiol* 1998;53:61-3.
6. Sakai F, Kiyono K, Sone S, Kondo Y, Oguchi M, Watanabe T, et al. Ultrasonic evaluation of cervical metastatic lymphadenopathy. *J Ultrasound Med* 2002;7:305-10.
7. Kuna SK, Bracic I, Tesic V, Kuna K, Herceg GH, Dodig D. Ultrasonographic differentiation of benign from malignant neck lymphadenopathy in thyroid cancer. *J Ultrasound Med* 2006;25:1531-7.
8. Scott GS, Meier DA, Dickinson CZ. Cervical lymph node metastasis of thyroid papillary carcinoma imaged with fluorine-18-FDG, technetium-99m-perchnetate and iodine-131-sodium iodide. *J Nucl Med* 1995;36:1843-5.
9. Kupferman ME, Patterson M, Mandel SJ, LiVolsi V, Weber RS. Patterns of lateral neck metastasis in papillary thyroid carcinoma. *Arch Otolaryngol Head Neck Surg* 2004;130(7):857-60.
10. Rosário PW, de Faria S, Bicalho L, Alves MF, Borges MA, Purisch S, et al. Ultrasonographic differentiation between metastatic and benign lymph nodes in patients with papillary thyroid carcinoma. *J Ultrasound Med* 2005;24:1385-9.
11. Sutton RT, Reading CC, Charboneau JW, James EM, Grant CS, Hay ID. US-guided biopsy of neck masses in postoperative management of patients with thyroid cancer. *Radiology* 1988;168:769-72.
12. Wunderbaldinger P, Harisinghani MG, Hahn PF, Daniels GH, Turetschek K, Simeone J, et al. Cystic lymph node metastases in papillary thyroid carcinoma. *AJR Am J Roentgenol* 2002;178:693-7.

Received 23 November 2007, accepted 12 June 2008

*Straipsnis gautas 2007 11 23, priimtas 2008 06 12*