

KLINIKINIS ATVEJIS

Metastatic amelanotic nodular melanoma during pregnancy

Daiva Jasaitienė, Skaidra Valiukevičienė, Jurgita Makštienė¹, Edita Bronė Juodžbalienė²

Department of Skin and Venereal Diseases, ¹Department of Pathological Anatomy,

²Department of Oncology, Kaunas University of Medicine, Lithuania

Key words: amelanotic melanoma; metastatic melanoma; pregnancy; therapy.

Summary. This case report presents a very aggressive course of amelanotic nodular melanoma during pregnancy resulting in death five months after delivery. A 34 year-old Caucasian woman at 19th week of the second pregnancy was diagnosed having amelanotic nodular melanoma (tumor thickness – 2.5 mm) with metastases to the regional right inguinal lymph node. Amelanotic nodular melanoma represents malignant melanocytic tumor of the skin, which clinically mimics a variety of benign and malignant skin conditions and therefore commonly leads to delayed diagnosis. Though primary tumor was excised immediately, other treatment procedures as radical lymphadenectomy and chemotherapy were delayed, and immunotherapy was not given totally. At the 29th week of pregnancy, the woman via naturalem delivered a healthy female child, and the chemotherapy was started. Since pregnancy limits the prescription of immunotherapy and chemotherapy, the prognosis for melanoma during pregnancy detected later than in the second stage is poor and can be illustrated by our reported case. Such patients seems to be at higher risk to develop metastasis of melanoma in the internal organs and occasionally even in the fetus; therefore, they should be timely informed about that.

Introduction

Over the past few decades, the incidence of skin melanoma has been rising in almost all western-civilized developed countries, especially in predominantly white populations (1). A recent nationwide incidence trend analysis of the incidence of cutaneous melanoma in Lithuania has shown that the incidence and mortality considerably increased over time (2).

Invasive malignancy in pregnancy is not common, and an estimated occurrence rate is reported to be 0.94 per 1000 births (3). The types of cancer observed in pregnancy mirror those seen in nonpregnant women of the same age, and in the order of decreasing frequency, these cancers include carcinomas of the breast, cervix, and lung, melanoma, lymphoma, and leukemia (4). The estimated incidence of melanoma complicating pregnancy ranges from 0.1 to 2.8 cases per 1000 pregnancies (5). Though melanoma is not the most common cancer in pregnancy, it is most likely to metastasize to the placenta and fetus, accounting for 27 (31%) of the 87 cases published in the literature (4).

Case report

A 34-year-old Caucasian woman at the 19th week of the second pregnancy arrived for the evaluation of threatened miscarriage and swollen painful right inguinal lymph node. The histological and immunohistochemical (S100 and HMB45 positive) examination of the excised inguinal lymph node showed metastasis of melanoma.

During a full-body skin examination, a nonulcerated reddish elevated 0.5 cm in diameter tumor was detected on the upper part of the right buttock, which appeared several years before pregnancy on the healthy skin. Dermatoscopic examination showed a red nodule with numerous small vessels perpendicular to the skin surface seen as small dots without any signs of pigmentation (Fig. 1). Amelanotic nodular melanoma was suspected, and the tumor was excised.

Histological examination showed contiguous growth of atypical melanocytes in the dermis forming asymmetrical tumor mass attached closely to the epidermis (Fig. 2). Immunohistological examination of primary tumor (strongly positive S100, focally posi-

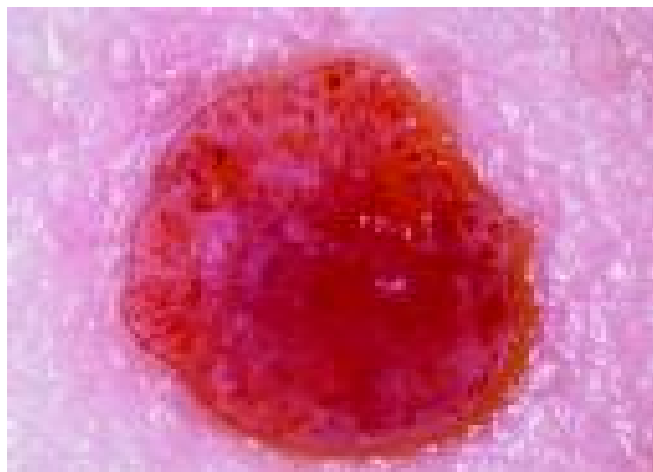

Fig. 1. Under the dermatoscope, the polymorphous vascular pattern with horizontally oriented truncated capillaries, vascular red globules, and scar-like areas suggest amelanotic malignant melanoma

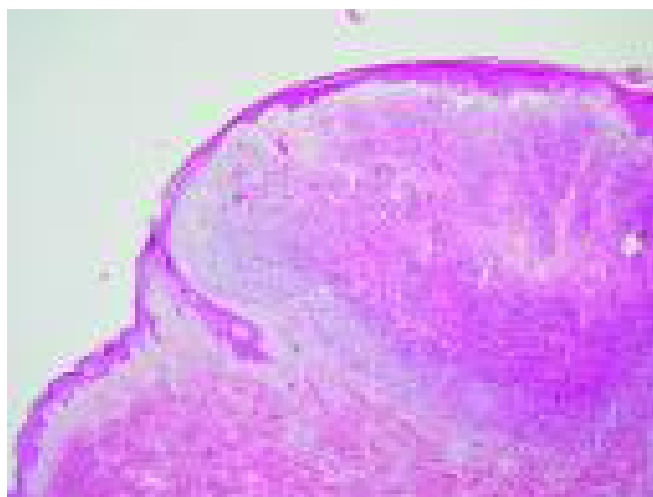


Fig. 2. Histological examination shows contiguous growth of atypical melanocytes in the dermis, forming asymmetrical tumor mass attached closely to the epidermis and invading the upper part of reticular dermis (H&E, original magnification $\times 25$)

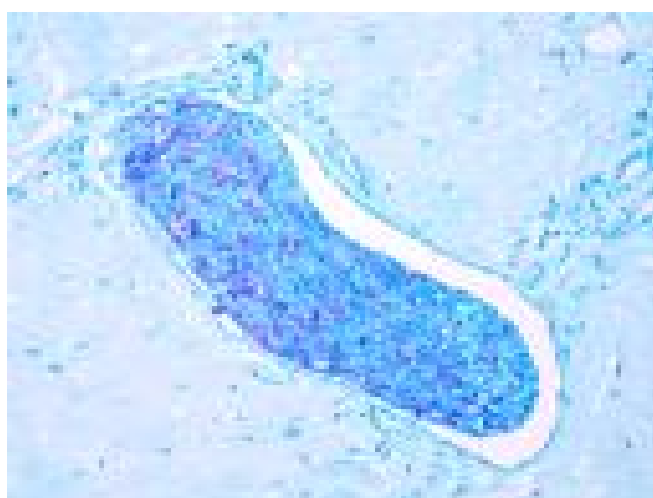

Fig. 3. Immunohistological examination shows a massive invasion of melanoma cells into the lumina of a vessel without any adjacent immunological response (HMB45, original magnification $\times 200$)

tive HMB45) confirmed the diagnosis of nodular melanoma (Breslow depth, 2.5 mm) with metastases in the regional lymph node. All specimens (stained with hematoxylin-eosin, S100, and HMB45) showed a massive invasion of the tumor cells into the vessels without immune response around invasive malignancy (Fig. 3).

The patient was familiarized with the poor prognosis of the disease, but she refused to discontinue pregnancy and to perform radical lymphadenectomy before the 28th week of pregnancy, in order not to harm the fetus. During the 25th week of pregnancy, the recurrence of metastases was detected in lymph nodes of the right inguinal area, and radical inguinal lymphadenectomy was performed. No signs of metastases to internal organs were found during magnetic resonance imaging screening at that time.

At the 29th week of pregnancy, multiple skin metastases occurred in the right inguinal region. Premature labor was induced, and the woman via *naturalem* delivered a healthy female child (weight, 1572 g; APGAR, 4–6 points). Careful macroscopic and histological examination of placenta did not show metastases of melanoma. The chemotherapy with dacarbazine was started two days after the delivery (250 mg/m² 1–5 day every 4 weeks 5 months). Unfortunately, this treatment did not stop the progression of the disease. Multiple metastases in the liver were detected within next 2 weeks after delivery, and multiple metastases of bones, skin, and subcutaneous tissue were found subsequently. Five months after delivery, the woman died due to exhaustion of vital functions.

Comments

Amelanotic nodular melanoma represents malignant melanocytic tumor of the skin, which clinically mimics a variety of benign and malignant skin conditions and therefore commonly leads to delayed diagnosis (6).

For many years, there has been concern that the hormonal and immunological changes that occur during pregnancy may be important in the development or progression of melanoma. The concern about the effect of pregnancy began in 1951, when Pack and Scharnagel reviewed 32 cases of melanoma diagnosed during pregnancy and reported extremely poor prognosis due to the rapid development of metastases (7). However, multiple well-controlled trials, published since the 1980s, have now consistently observed no significant effect on survival in women diagnosed with localized malignant melanoma during pregnancy (8, 9). Maternal and neonatal outcomes were also equi-

valent to those of pregnant women without melanoma. The prognosis for the fetus in a woman diagnosed with melanoma during pregnancy is dependent on her stage of disease (8, 9). Metastasis to the fetus occurs rarely. Case reports of fetal metastasis indicate that this event occurred only in women with advanced stages of melanoma with distant metastases (4, 8, 9). Concerning the clinical and/or histological differences that one may see in melanomas diagnosed during pregnancy, the only noteworthy difference observed in multiple studies is greater Breslow depth (9–12). Otherwise, other controlled trials and large population-based studies have not shown melanomas diagnosed during pregnancy to differ from nonpregnant controls in anatomic location of lesions or tumor thickness (8, 10). According to the accumulated data, there is a consensus suggesting that the only factor influencing the prognosis of melanoma during pregnancy is the stage of the disease, but not pregnancy itself, and there are no medical indications for discontinuing the pregnancy (8).

Although pregnant women with melanoma should be treated similarly to nonpregnant ones, pregnancy status limits the treatment options (9, 11, 13). Surgery is a definitive therapy for early-stage disease (stage I and II melanoma), and this does not differ between pregnant and nonpregnant women, whereas the treatment of pregnant women with stage III and IV melanoma is less clear and more difficult. The use of chemotherapy during pregnancy is still an issue for discussion among oncologists, while there is insufficient evidence to warrant the use of adjuvant chemotherapy or biologic therapy during pregnancy (14–16). In addition to that, radiological examinations and the possible use of sentinel lymph node biopsies are considerations that modify management options for pregnant women. Chest x-ray can be safely performed with appropriate shielding, but ultrasound and magnetic resonance investigation (MRI) would be preferred over computer tomography (CT) scans to minimize fetal radiation exposure (17, 18). However, MRI is often avoided in the first trimester because of overheating of tissues (17, 18). If the patient is in need of sentinel lymph node mapping and biopsy, then the technique and timing of the procedure vary widely according to the individual clinical situation (19–21). Therefore, early detection of thin melanomas should be the goal when treating women with pigmented lesions during childbearing age, as at any age.

The effect of prior pregnancies on the prognosis of melanoma has also been examined in case-controlled studies. The findings showed that prior pregnancies

either have no adverse effect on the prognosis of patients in whom melanoma developed after the woman completed pregnancy, or even exert a certain favorable influence on survival rates (9).

There are insufficient data to fully understand the role of hormones in the outcome of patients with melanoma. The gender-specific differences in the prognosis of melanoma are interpreted by the hypothesis that estrogens may be responsible for the inhibition of melanoma. However, the classical estrogen-receptor pathway cannot explain the effect of estrogens on the biological behavior of melanoma, since the reports in the literature regarding the expression of estrogen receptors are conflicting. Several studies have suggested that the endogenous estrogen metabolite 2-methoxyestradiol (2-ME) inhibits angiogenesis and suppresses tumor growth in many malignant tumors (22). The data suggest that 2-ME has antiproliferative and apoptotic activities mediated independently of estrogens receptors. Although various molecular targets have been proposed for 2-ME, the actual mechanism of its action is still undefined, and further research is necessary (23).

The mechanisms by which pregnancy at least in some cases may lead to increased thickness of melanoma remain unclear. Several hypotheses merit investigation: a variety of growth factors are present at increased levels during pregnancy, immunohormonal mechanisms may facilitate the growth of the tumor, and delay in diagnosis may contribute to the increased thickness of melanoma. Maternal immunological tolerance appears to be associated with the development of several specific mechanisms that protect the fetus from maternal cytotoxic immune attack. The apoptosis of T cells has been proposed as one of mechanisms for maintaining tolerance in the immune system. Activated T lymphocytes express Fas (a type-I transmembrane receptor) transducer a cell death signal when ligated by specific antibody or its natural ligand FasL (a type-II integral membrane protein, belonging to the

tumor necrosis factor/nerve growth factor gene family). Recent data suggest that Fas/FasL-mediated apoptosis through decreased concentration of their blocker soluble Fas could be a very elegant mechanism for local maternal immunotolerance of the fetal semi-allograft during pregnancy (24). Overactive expression of this and other specific mechanisms of immunotolerance in pregnancy can be responsible for the insufficient immune attack against malignancies. Our case demonstrated no local immune response to the invasive malignant tumor.

In summary, melanoma and pregnancy represent a difficult situation for the patient, her partner, and physicians. The wish to have a healthy child meets the potentially deadly cancer disease. Some recently published cases as well as our case illustrate that management of advanced disease during pregnancy is more complicated and meets a conflict between optimal maternal therapy and fetal or neonatal well being (13, 16, 25). Therapeutic, familial, and social considerations must be addressed and decided in an individualized manner. Pregnancy may be terminated or continued, and the management planned accordingly. Since pregnancy limits the prescription of immunotherapy and chemotherapy, the prognosis for melanoma during pregnancy detected later than in the second stage is poor and can be illustrated by our and other reported cases (13). Such patients seem to be at higher risk to develop metastasis of melanoma in the internal organs and occasionally even in the fetus; therefore, they should be timely informed about that. Prospective randomized clinical trials cannot be conducted in this field; therefore, relevant data could be generated from case reports and matched historical cohort studies.

Acknowledgement

We would like to thank Harald Gollnick, MD, Director of the Department of Dermatovenereology of Otto-von-Guericke University of Magdeburg in Germany, for the consultation making this case report.

Metastazinė amelanininė mazginė melanoma nėštumo metu

Daiva Jasaitienė, Skaidra Valiukevičienė, Jurgita Makštienė¹, Edita Bronė Juodžbalienė²

Kauno medicinos universiteto Odos ir venerinių ligų klinika, ¹Patologinės anatomijos klinika, ²Onkologijos klinika

Raktažodžiai: amelanininė melanoma, metastazinė melanoma, nėštumas, terapija.

Santrauka. Straipsnyje aprašoma agresyvi amelanininės mazginės melanomos eiga nėštumo metu. Amelanininė mazginė melanoma – piktybinis melanocitinės kilmės odos navikas, kuris panašus į daugelį kitų gerybinės ar piktybinės kilmės odos darinių, todėl dažnai nustatomas pavėluotai. 34 metų moteriai 19-tą nėštumo

savaiteį diagnozuota amelanininė mazginė melanoma (naviko storis – 2,5 mm) su metastazėmis dešinės kirkšnies limfmazgiuose. Nors pirminis navikas neatidėliojant buvo plačiai išoperuotas, kiti gydymo etapai dėl nėštumo buvo atidėti vėlesniam laikui (radikali limfadenektomija ir chemoterapija) arba visiškai netaikyti (imunoterapija). 29-tą nėštumo savaitę per natūralius gimdymo takus pacientė pagimdė sveiką moteriškosios lyties naujagimį ir jai buvo pradėtas chemoterapijos kursas. Nepaisant to, praėjus penkiems mėnesiams po gimdymo, nuo išplitusio piktybinio odos naviko sukeltų komplikacijų pacientė mirė. Kadangi nėštumo metu imunoterapijos ar chemoterapijos taikymas yra ribotas, esant didesnei nei antrai melanomos stadijai, ligos prognozė yra nepalanki. Tokioms pacientėms yra didesnė metastazių vidaus organuose rizika, rečiau ir vaisiui. Apie tai joms turėtų būti laiku suteikta informacija.

Adresas susirašinėti: D. Jasaitienė, KMU Odos ir venerinių ligų klinika, Eivenių 2, 50009 Kaunas
El. paštas: daiva@dr.com

References

- World Health Organization. The International Statistical Classification of Diseases and Related Health Problems, 10th revision. Geneva, Switzerland: World Health Organization; 1992.
- Stang A, Valiukeviciene S, Aleknaviciene B, Kurtinaitis J. Time trends of incidence, mortality, and relative survival of skin melanoma in Lithuania. *Eur J Cancer* 2006;42:660-7.
- Smith LH, Danielsen B, Allen ME, Cress R. Cancer associated with obstetric delivery: results of linkage with the California cancer registry. *Am J Obstet Gynecol* 2003;189:1128-35.
- Alexander A, Samlowski WE, Grossman D, Bruggers CS, Harris RM, Zone JJ, et al. Metastatic melanoma in pregnancy: risk of transplacental metastases in the infant. *J Clin Oncol* 2003;21:2179-86.
- O'Reilly S, Chakravarthy A. Other cancers in pregnancy. In: Trimble E, Trimble C, editors. *Cancer obstetrics and gynecology*. Philadelphia: Lippincott Williams and Wilkins; 1999. p. 249-59.
- Zalaudek I, Argenziano G, Kerl H, Soyer HP. Amelanotic/hypomelanotic melanoma – is dermatoscopy useful for diagnosis? *J Dtsch Dermatol Ges* 2003;1:369-73.
- Pack GT, Scharnagel IM. The prognosis for malignant melanoma in the pregnant woman. *Cancer* 1951;4:324-34.
- O'Meara AT, Cress R, Xing G, Danielsen B, Smith LH. Malignant melanoma in pregnancy. A population-based evaluation. *Cancer* 2005;103:1217-26.
- Driscoll MS, Grant-Kels JM. Hormones, nevi, and melanoma: an approach to the patient. *J Am Acad Dermatol* 2007;57:919-31.
- Lens MB, Rosdahl I, Ahlbom A, Farahmand BY, Synnerstad I, Boeryd B, et al. Effect of pregnancy on survival in women with cutaneous malignant melanoma. *J Clin Oncol* 2004;22:4369-75.
- Travers RL, Sober AJ, Berwick M, Mihm MCJr, Barnhill RL, Duncan LM. Increased thickness of pregnancy-associated melanoma. *Br J Dermatol* 1995;132:876-83.
- MacKie RM, Bufalino R, Morabito A, Sutherland C, Cascinelli N. Lack of effect of pregnancy on outcome of melanoma. For the World Health Organization Melanoma Programme. *Lancet* 1991;337:653-5.
- Beyeler M, Hafner J, Beinder E, Fauchere JC, Stoeckli SJ, Fehr M, et al. Special considerations for stage IV melanoma during pregnancy. *Arch Dermatol* 2005;141:1077-9.
- Johnson SRD. What should we tell patients about hormones after having melanoma? In: Newton Bishop JA, Gore M, editors. *Melanoma: critical debates*. Oxford: Blackwell Science; 2002. p. 275-6.
- Dipaola RS, Goodin S, Ratzell M, Florczyk M, Karp G, Ravikumar TS. Chemotherapy for metastatic melanoma during pregnancy. *Gynecol Oncol* 1997;66:526-30.
- Egberts F, Lischner S, Russo P, Kampen WU, Hauschild A. Diagnostic and therapeutic procedures for management of melanoma during pregnancy: risk for the fetus? *J Dtsch Dermatol Ges* 2006;4:717-20.
- Leyendecker JR, Gorengaut V, Brown JJ. MR imaging of maternal diseases of the abdomen and pelvis during pregnancy and the immediate postpartum period. *Radiographics* 2004;24(5):1301-16.
- Oto A, Ernst R, Jesse MK, Chaljub G, Saade G. Magnetic resonance imaging of the chest, abdomen, and pelvis in the evaluation of pregnant patients with neoplasms. *Am J Perinatol* 2007;24(4):243-50.
- Mondi MM, Cuenca RE, Ollila DW, Stewart JH 4th, Levine EA. Sentinel lymph node biopsy during pregnancy: initial clinical experience. *Ann Surg Oncol* 2007;14(1):218-21.
- Lloyd MS, Topping A, Allan R, Powell B. Contraindications to sentinel lymph node biopsy in cutaneous malignant melanoma. *Br J Plast Surg* 2004;57:725-7.
- Kaikaris V, Valiukevičienė S, Rimdeika R, Gollnick H, Ulrich J. Sentinel lymph node biopsy in melanoma patients: methods, indications, and clinical significance. *Medicina (Kaunas)* 2003;7:621-30.
- Fotsis T, Zhang Y, Pepper MS, Adlercreutz H, Montesano R, Nawroth PP, et al. The endogenous oestrogen metabolite 2-methoxyoestradiol inhibits angiogenesis and suppresses tumour growth. *Nature* 1994;368:237-9.
- LaVallee TM, Zhan XH, Herbstritt CJ, Kough EC, Green SJ, Pribluda VS. 2-Methoxyestradiol inhibits proliferation and induces apoptosis independently of estrogen receptors alpha and beta. *Cancer Res* 2002;62:3691-7.
- Hoshimoto K, Hayashi M, Ohkura T. Plasma levels of soluble Fas during normal pregnancy. *Gynecol Obstet Invest* 2001;51:96-8.
- Alexander A, Harris RM, Grossman D, Bruggers CS, Leachman SA. Vulvar melanoma: diffuse melanosis and metastasis to the placenta. *J Am Acad Dermatol* 2004;50:293-8.

Received 14 January 2008, accepted 11 June 2008
Straipsnis gautas 2008 01 14, priimtas 2008 06 11