

SUPPROTING INFORMATION

Topical application of phlorotannins from brown seaweed mitigates radiation dermatitis in a mouse model

Kyungmi Yang ^{1,2,†}, **Shin-Yeong Kim** ^{1,†}, **Ji-Hye Park** ^{2,3}, **Won-Gyun Ahn** ¹, **Sang Hoon Jung** ¹, **Dongryul Oh** ^{1,3}, **Hee Chul Park** ^{1,3,*} and **Changhoon Choi** ^{1,*}

¹ Department of Radiation Oncology, Samsung Medical Center, Seoul 06351, Republic of Korea; kyungmi.yang@samsung.com (K.Y.); kkdnsy@naver.com (S.-Y.K.); mementoamor@icloud.com (W.-G.A.); sang-hoon.jung@samsung.com (S.H.J.); dongryul.oh@samsung.com (D.O.)

² School of Medicine, Sungkyunkwan University, Seoul 06351, Republic of Korea; jh1024.park@samsung.com (J.-H.P.)

³ Department of Dermatology, Samsung Medical Center, Seoul 06351, Republic of Korea

† These authors contributed equally to this work.

* Correspondence: hee.ro.park@samsung.com (H.C.P.); chchoi93@gmail.com (C.C.); Tel.: +82-2-3110-2605 (H.C.P.); +82-6190-5331 (C.C.)

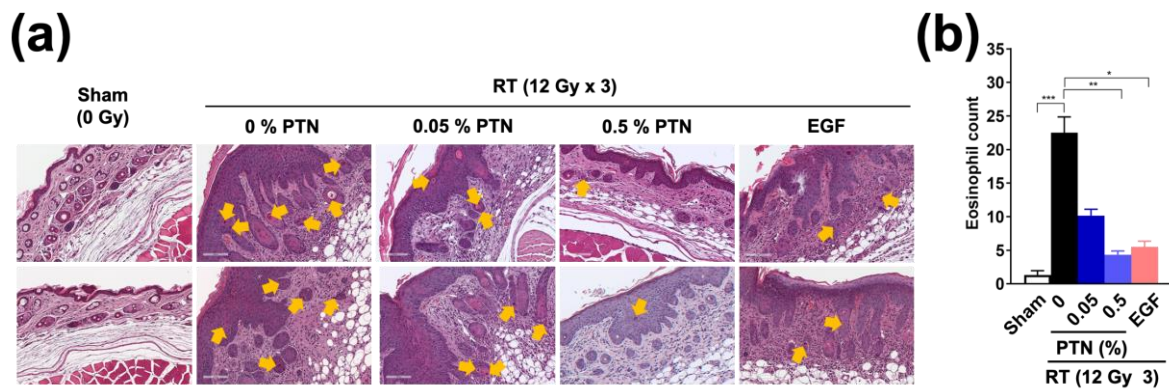


Figure 1. Effects of phlorotannins on infiltration of eosinophils in irradiated skin tissues. **(a)** Representative two images of H&E staining of irradiated skin tissues. Skin are was topically treated with 0%, 0.05%, and 0.5% PTNs or EGF. Skin tissues were collected at 14 days post-irradiation. Yellow arrows indicate eosinophils. **(b)** Quantification of eosinophils infiltrating in irradiate skin tissues. Data are means \pm SD (n = 6 per group); Difference was evaluated using a Kruskal-Wallis test, followed by Dunn's multiple comparison test. * $p < 0.05$; ** $p < 0.01$; *** $p < 0.001$.




Figure 2. Setup for mouse irradiation. **(a)** A treatment plan showing 30 cm \times 7 cm field size. **(b)** A photo image showing that right hind legs were located within the irradiation field.