

# Respiratory treatment in a patient with nemaline myopathy

Massimiliano Polastri,<sup>1</sup>  
 Gioacchino Schifino,<sup>2</sup>  
 Eva Tonveronachi,<sup>3</sup>  
 Francesco Tavalazzi<sup>3</sup>

<sup>1</sup>Department of Continuity of Care and Disability, Physical Medicine and Rehabilitation, St Orsola University Hospital; <sup>2</sup>Department of Clinical, Integrated and Experimental Medicine (DIMES), Alma Mater Studiorum University of Bologna; <sup>3</sup>Department of Cardiac-Thoracic-Vascular Diseases, Unit of Pneumology, St Orsola University Hospital, Bologna, Italy

## Abstract

Respiratory involvement of nemaline myopathy is evident on the diaphragm and intercostal muscles function. The present case study aimed to describe the characteristics of the respiratory physiotherapeutic treatment in a patient with nemaline myopathy. Here, we describe a case of a 43-year-old woman with nemaline myopathy undergoing pulmonary rehabilitation during short hospital admission for an acute exacerbation. At the time of hospitalisation, the patient was already under oxygen therapy (1 L/min) and noninvasive home ventilation using bi-level positive airway pressure with a nasal interface. Supplementary therapeutic exercises were implemented in addition to daily nasal noninvasive ventilation. At discharge, ultrasound examination revealed increased diaphragm trophism if compared with data obtained at hospital admission.

## Introduction

Nemaline myopathy (NM) is a congenital disease characterised by the presence of malformed contractile filaments in the muscle structure.<sup>1,2</sup> NM should be included in the differential diagnosis of dilatative cardiomyopathy.<sup>3</sup> Hypertrophic cardiomyopathy may be associated with NM in pediatric patients.<sup>4,5</sup> Primary symptoms of NM are a generalised weakness, hypotonia and diminished - if not absent - tendon reflexes.<sup>2</sup> NM is classified into six different forms that can overlap; diagnosis of NM can be made by muscle biopsy.<sup>2</sup> Respiratory involvement of NM is evident on the diaphragm and intercostal muscles function; moreover,

contractures and articular deformations are also usually present.<sup>2</sup> In preparing this case report, we followed the CARE criteria.<sup>6</sup> To date, no report has been published about the short-term effect of respiratory physiotherapeutic treatment, in patients with NM.

Here we describe a case of a woman with NM undergoing pulmonary rehabilitation during short hospital admission for an acute exacerbation.

## Case Report

The present study was a case report conducted at the St Orsola University Hospital, Pneumology Unit (Bologna, Italy). The patient was informed on the study nature, and she provided written informed consent.

A 43-year-old Caucasian female NM patient, with a body mass index of 11.9 (kg/m<sup>2</sup>) was admitted to our institution for an exacerbation due to cooling syndrome with fever (up to 38°C) and mucus retention. The patient typically presented physical characteristics of NM already reported in the literature, such as elongated face and muscle weakness.<sup>7</sup> The circumferences of the upper and lower limbs are shown in Table 1. These measurements were consistent with severe loss of muscular trophism, and sarcopenia: muscular strength was evaluated using the Medical Research Council (MRC) Scale,<sup>8,9</sup> as shown in Table 1. Both ankles were oriented in extreme plantar flexion, and bilateral pes cavus was also present. The patient underwent surgical correction of severe scoliosis at the age of 13 with Harrington instrumentation (Figure 1A).

At the hospital admission, the patient was already under oxygen therapy (1 L/min) and home noninvasive ventilation (NIV) using bi-level positive airway pressure (BiPAP) (spontaneous/timed modality) 2 h morning, 2 h afternoon, and overnight: inspiratory positive airway pressure (IPAP) 18 cmH<sub>2</sub>O; expiratory positive airway pressure (EPAP) 3 cmH<sub>2</sub>O; frequency 12 breaths/min; T<sub>Imin</sub> 0.6 s; T<sub>Imax</sub> 1.4 s, with nasal interface. Arterial blood gas analyses (ABGs) performed while on oxygen therapy showed respiratory acidosis and hypoxemia overcorrection (pO<sub>2</sub> 109 mmHg; pCO<sub>2</sub> 74.4 mmHg; pH 7.34). A further ABGs performed during a spontaneous breathing trial confirmed chronic respiratory failure with hypercapnia. Polygraph examination revealed a snoring time of 13.6 minutes (relative snoring time 3.2%) with 50 snoring episodes registered during the recording time (435 minutes): apnea-hypopnea index (AHI)=7.5; AHI

Correspondence: Massimiliano Polastri, Physical Medicine and Rehabilitation, St Orsola University Hospital, Via G. Massarenti 9, Bologna 40138, Italy.  
 Tel.: (+39).051.214.4980 - Fax: (+39).051.082.2185.  
 E-mail: gbptap1@gmail.com

Key words: Nemaline myopathy; respiratory therapy; scoliosis; physiotherapy techniques; noninvasive ventilation.

Contributions: MP, ET, conceptualization; MP, GS, writing; MP, GS, ET, FT, methodology, review and editing, approval final version.

Conflicts of interest: the authors declare they have no conflicts of interest.

Received for publication: 2 October 2019.  
 Revision received: 4 November 2019.  
 Accepted for publication: 5 November 2019.

This work is licensed under a Creative Commons Attribution NonCommercial 4.0 License (CC BY-NC 4.0).

©Copyright: the Author(s), 2019  
 Licensee PAGEPress, Italy  
 Clinics and Practice 2019; 9:1209  
 doi:10.4081/cp.2019.1209

supine=18.4; oxygen desaturation index (ODI)=14.5. During polygraphy the mean oxygen saturation was 92.1%, whereas the lowest was 72%; saturation cumulative time <90% / <80% was 13.1% and 1.2%, respectively.

The spirometry showed a clinical frame compatible with severe restrictive lung disease: forced vital capacity (FVC) 15%, forced expiratory volume in 1 second (FEV<sub>1</sub>) 17%. During the hospital stay, the patient had respiratory crises, which resulted in an increased breathing frequency (>30 breaths/min at rest), accompanied by episodes of bronchoconstriction and dyspnea. Thoracic X-ray imaging, as shown in Figure 1A, was suggestive of restrictive alterations of the pulmonary tissue, as initially confirmed by the spirometry. Pulmonary computerised axial tomography (CT-SCAN) imaging revealed the presence of dysventilation phenomena, and bronchiectasis (Figure 1B-C). Bedside ultrasound evaluation (MySono U6, Samsung Electronics, Seoul, South Korea) of the diaphragm was also performed both at the hospital admission and discharge, to evaluate the muscle thickness (Figure 1D-E). Measurements were performed using a linear probe in M-MODE function. Diaphragm thickness was obtained on the apposition zone,<sup>10</sup> between the anterior axil-

lary and the midaxillary lines at rest (functional residual capacity) and after a maximal inspiratory manoeuvre (total lung capacity). Diaphragm thickness fraction was calculated as follow:

Delta ( $\Delta$ ) thickness (TK) = [TK at (\*) total lung capacity (TLC) – TK\* functional residual capacity (FRC) / TK\*FRC] namely,  $\Delta TK = (TK * TLC - TK * FRC) / TK * FRC$ .

At hospital admission thickness fraction was: TK\*FRC: 0,19 cm (D2 in Figure 1D), TK\*TLC: 0,27 cm (D1 in Figure 1D),  $\Delta TK: (0,27-0,19) / 0,19 * 100 = 42\%$ .

### Noninvasive ventilation

The patient was treated with daily sessions of nasal NIV scheduled in the morning and over the night (Figure 2). Ventilation parameters were modified to improve both treatment efficiency and patient comfort. Eventually, EPAP was increased from 3 cmH<sub>2</sub>O to 4 cmH<sub>2</sub>O to achieve alveolar recruitment (EPAP parameters higher than 4 cmH<sub>2</sub>O were poorly tolerated). The backup frequency was increased from 12 breaths/min to 14 breaths/min. Moreover, the personal nasal interface was replaced by an oronasal one.

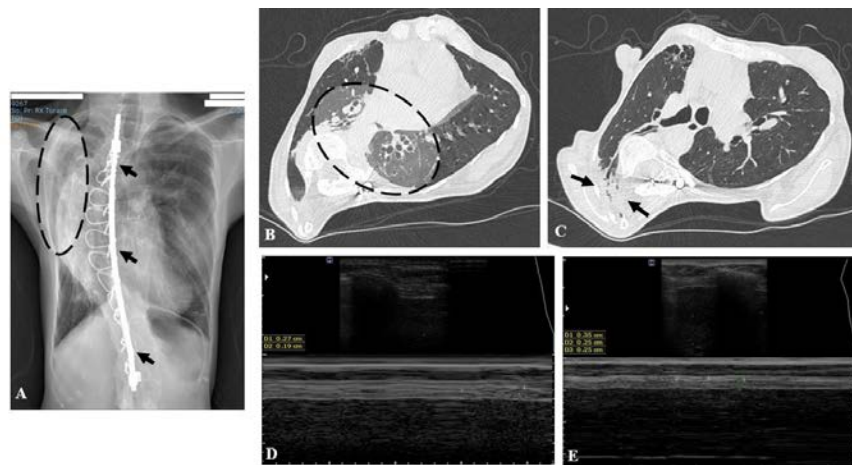
### Respiratory exercises

In addition to the already planned programme of daily nasal NIV, it was decided to take actions to counteract the lung tissues impairment diagnosed by the CT-SCAN examination. In this regard, supplementary therapeutic interventions were planned for obtaining chest expansion and to ameliorate alveolar hypoventilation.

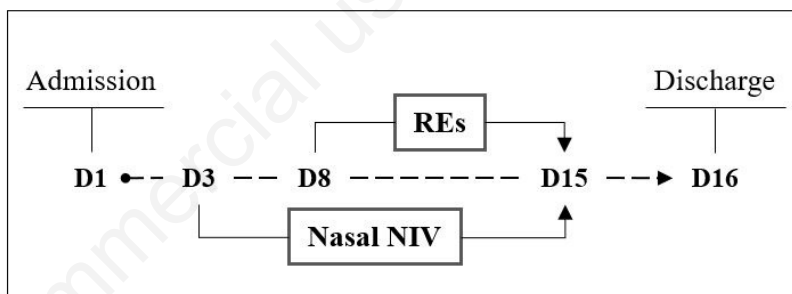
To this end, starting from the first days after hospital admission, the following daily interventions were carried out until the patient was discharged home (Figure 2): three different components constituted the physiotherapeutic treatment namely i) exercises executed with the physiotherapist, ii) supervised exercises, and iii) self-administered exercises. The physiotherapeutic programme lasted 8 daily sessions carried out in the morning Monday to Friday.

### Exercises executed with the physiotherapist

Previous reports described the use of a positive airway pressure device (EzPAP® system; Smiths Medical, St. Paul, MN, USA) to obtain lung expansion in different classes of patients.<sup>11,12</sup> In the present case, as previously highlighted, the rationale of the respiratory treatment was primarily oriented to enhance patient’s chest expansion to increase the tidal volume (VT), and counteract lungs dysventilation. To this end, the EzPAP® system has been used via mouth-



**Figure 1.** (A) Rib cage deformity and related asymmetry of the pulmonary fields in severe scoliosis treated with Harrington instrumentation (black arrows); inhomogeneous parenchymal consolidation (dotted area). (B) Asymmetry of the pulmonary fields, cylindrical bronchiectasis in the left lower lobe (dotted area). (C) Parenchymal consolidation of the dorsal segment of the right upper lobe (black arrows). (D) Ultrasound diaphragmatic evaluation, examination performed at patient’s admission: thickness at total lung capacity maneuver (D1); thickness at functional residual capacity maneuver (D2). (E) Examination performed at patient’s discharge: thickness at total lung capacity maneuver (D1); thickness at functional residual capacity maneuver (D2-D3).



**Figure 2.** Timeline. D, day; REs, respiratory exercises; NIV, noninvasive ventilation.

**Table 1.** Circumferences of the upper and lower limbs (cm), and bilateral muscular strength evaluation (MRC scale).

Limbs circumference	Side	
	Right	Left
<i>Lower</i>		
Quadriceps (proximal)	31	30
Quadriceps (middle)	28	27
Quadriceps (distal)	25	24
Leg (middle)	21	20
<i>Upper</i>		
Biceps (middle)	15	15.5
Wrist	11	12
Muscles	Grading	
Sternocleidomastoideus, deltoideus, biceps brachii, flexors and extensors of the head, flexors and extensors of the fingers, intrinsic muscle of the hand	4/5	
Triceps brachii	3/5	
Iliopsoas, quadriceps and biceps femoris, gastrocnemius, peroneus	4/5	
Tibialis anterior	2/5	
Extensor hallucis longus, long extensor digitorum	1/5	

MRC, Medical Research Council.

piece with a delivered pressure of about 10 cmH<sub>2</sub>O, which was considered a therapeutic value in light of the results described in other previously published studies.<sup>11,12</sup> To obtain the desired pressure, a flow of 8 L/min was necessary: the device was connected to a wall flowmeter, using a FiO<sub>2</sub> of 21% (air). A detailed description of the EzPAP® system has been already reported elsewhere.<sup>11,12</sup> Therapeutic sessions with EzPAP® system were carried out regularly in the morning, and they lasted about 15 minutes each and were interrupted in case the patient was uncomfortable with the treatment. Indeed, the patient reported a satisfying chest wall muscular involvement: this was an encouraging feedback that contributed to the treatment adherence.

### Supervised exercise

A second therapeutic step was planned to instruct the patient to perform diaphragmatic breathing to gain much more space at the lungs' basal levels. The patient exercised in a supine position with a hand placed in the epigastric region to perceive diaphragmatic movements. A pillow was placed under the patient's knees to obtain a more comfortable position. Diaphragmatic breathing lasted about 15 minutes.

### Self-administered exercises

During the first days, the patient was instructed to perform incentive spirometer exercises, to maximise improvements of VT. In the beginning, the patient was not able to produce enough inspiration effort to run the spirometer.

In addition, a positive expiratory pressure (PEP) device using a PEP bottle was tailored on the patient to pursue resistive breathing. The rationale for implementing this exercise was based on the possibility to increase functional residual capacity and VT.<sup>13</sup> No adverse effects related to the physiotherapeutic treatment were observed during the hospital stay, and the patient was discharged home without any additional procedures.

## Results

During the whole hospital stay, the patient was independent regarding postural passages, personal hygiene, reaching the standing station, and maintaining a sitting position in a chair; she was also able to ambulate for short distances within the room. The patient was able to perform two to three daily sessions of incentive spirometer exercises, which consisted of about 10 breaths each.

Nocturnal polysomnography excluded significant apneas (AHI 2.4, AHI supine 3.6); oximetry values were satisfactory (ODI 6). At the hospital discharge, there were no changes regarding the chest X-rays imaging, which showed a persistent parenchymal consolidation (Figure 1A).

Conversely, ultrasound examination performed at discharge showed improved diaphragm trophism if compared with hospital admission. In fact, diaphragmatic thickness fraction was as follow:

TK\*FRC: 0,25 cm (D2-D3 in Figure 1E),

TK\*TLC: 0,35 cm (D1 in Figure 1E),

$\Delta$ TK:  $(0,35-0,25) / 0,25 * 100 = 40\%$ .

Ultrasound examination showed that diaphragm trophism improved at FRC (+0,6 mm; +31%) and at TLC (+0,8 mm; +29%) as demonstrated by the following calculations:

TK\*FRC at discharge – TK\*FRC at admission: 0,25 cm – 0,19 cm = 0,6 mm;

TK\*TLC at discharge – TK\*TLC at admission: 0,35 cm – 0,27 cm = 0,8 mm.

## Discussion

Patients with NM may be affected by arthrogyrosis as reported in a study of 143 cases;<sup>14</sup> in the present case, the patient's symptoms were mainly related to the respiratory system and the musculoskeletal apparatus. Findings by Smith *et al.* (2011) demonstrated that it is possible to obtain improvements of the respiratory function using NIV coupled with respiratory training in a 16-year-old female with severe NM who underwent heart and kidney transplantation.<sup>15</sup> In that case, inspiratory muscle training was performed 5 days per week for 2 weeks showing consistent gains in maximal inspiratory pressure (+112% from baseline), together with reduced daily hours of assisted ventilation.

In another report, the authors found the same muscular depletion of both the upper and lower limbs together with respiratory impairment, as occurred in our case. Even in that patient, a 50-year-old man, diaphragmatic function was impaired - not improving over time -, and NIV was adopted as therapeutic support.<sup>7</sup> The use of NIV was confirmed as a crucial therapeutic intervention even in a case of a 47-year-old man with NM and associated dilated cardiomyopathy, presenting pulmonary congestion, pleural effusion and oxygen desaturation.<sup>16</sup> Furthermore, the use of NIV was effective to treat acute respiratory insufficiency in a 44-year-old-man with NM. In that case, NIV was also used in the long term, ameliorating respiratory function; FVC has passed by 1.53 L to 2.25 L over time. In addition,

the distance walked at the 10-m shuttle-walk test improved from 360 m to 440 m, and the intensity of perceived dyspnea has decreased from very severe to moderate, without implementing a specific physiotherapeutic regimen.<sup>17</sup>

Among the four cases mentioned above, only in one report physiotherapy (inspiratory muscle training) was combined with NIV,<sup>15</sup> - and in none of these - severe structural vertebral deformities were detected. In this regard, our study is unique as no previously published experiences have been described illustrating patients with NM and associated severe scoliosis. In addition, the current study represents a further example of a combined treatment using NIV and physiotherapy techniques. Nevertheless, the case illustrated here taught us that it was not possible to define if respiratory exercises were useful when associated with a programme of daily nasal NIV to treat respiratory insufficiency in a patient with NM. Many reasons can explain this hypothesis: first, NM usually affects the muscular system, and it is characterised by reduced motor performance. Second, the present case was complicated by the presence of severe structured scoliosis, limiting the basal lung expansion. Nevertheless, diaphragm trophism increased as documented at hospital discharge; this effect was related to the execution of physiotherapeutic treatment as no other therapeutic procedures were adopted. Since the exercise using the positive airway pressure was the most easily executable, and it was closely supervised during each session, it should be argued that diaphragm thickness increased in strict relation to it.

In the case reported here, the implementation of respiratory exercises contributed at improving the clinical frame, but no significant effects related to lung function were directly attributable to them; despite this, diaphragmatic function improved as demonstrated by the increased thickness fraction.

From the current study, it was not possible to define if diaphragm thickness increased as a result of one specific intervention or by combining multiple interventions. Also, it was not possible to establish if a different treatment duration could lead to better results. Another primary limitation of the current report could be the absence of correlation between diaphragm thickness and pulmonary function due to missing evaluation of the respiratory mechanics, through invasive techniques.

## Conclusions

Considering the results of the present case, the effectiveness of respiratory exercises flanked to NIV, in the treatment of respiratory symptoms associated with NM, remains unclear. Instead, from the current study it emerged that NIV was a unique therapeutic option to treat respiratory insufficiency in a patient with NM to support appropriate gas exchanges.

## References

1. Nance JR, Dowling JJ, Gibbs EM, Bönnemann CG. Congenital myopathies: an update. *Curr Neurol Neurosci Rep* 2012;12:165-74.
2. North KN, Ryan MM. Nemaline myopathy. In: Adam MP, Ardinger HH, Pagon RA, Wallace SE, Bean LJH, Stephens K, Amemiya A, eds. *GeneReview®* [internet]. Seattle, WA: University of Washington, Seattle; 1993-2019.
3. Müller-Höcker J, Schäfer S, Mendel B, et al. Nemaline cardiomyopathy in a young adult: an ultraimmunohistochemical study and review of the literature. *Ultrastruct Pathol* 2000;24:407-16.
4. Mir A, Lemier M, Ramaciotti C, et al. Hypertrophic cardiomyopathy in a neonate associated with nemaline myopathy. *Congenit Heart Dis* 2012;7:E37-41.
5. Nakajima M, Shima Y, Kumasaka S, et al. An infant with congenital nemaline myopathy and hypertrophic cardiomyopathy. *J Nippon Med Sch* 2008;75:350-3.
6. Gagnier JJ, Kienle G, Altman DG, et al. The CARE guidelines: consensus-based clinical case report guideline development. *J Clin Epidemiol* 2014;67:46-51.
7. Taglia A, D'Ambrosio P, Palladino A, Politano L. On a case of respiratory failure due to diaphragmatic paralysis and dilated cardiomyopathy in a patient with nemaline myopathy. *Acta Myol* 2012;31:201-3.
8. Medical Research Council. MRC Muscle Scale. Available from: <https://mrc.ukri.org/research/facilities-and-resources-for-researchers/mrc-scales/mrc-muscle-scale/> Accessed: 2 October 2019.
9. Paternostro-Sluga T, Grim-Stieger M, Posch M, et al. Reliability and validity of the Medical Research Council (MRC) scale and a modified scale for testing muscle strength in patients with radial palsy. *J Rehabil Med* 2008;40:665-71.
10. Ueki J, De Bruin PF, Pride NB. In vivo assessment of diaphragm contraction by ultrasound in normal subjects. *Thorax* 1995;50:1157-61.
11. Polastri M, Pantaleo A. Managing a left pleural effusion after aortic surgery. *Eur Rev Med Pharmacol Sci* 2012;16:78-80.
12. Polastri M, Savini C, Di Marco L, et al. Post-operative pleural effusion in a heart transplant recipient: a single-case study of physiotherapy treatment. *Int J Ther Rehabil* 2016;24:302-5.
13. Fagevik Olsén M, Lannefors L, Westerdahl E. Positive expiratory pressure - Common clinical applications and physiological effects. *Respir Med* 2015;109:297-307.
14. Ryan MM, Schnell C, Strickland CD, et al. Nemaline myopathy: a clinical study of 143 cases. *Ann Neurol* 2001;50:312-20.
15. Smith BK, Bleiweis MS, Zauhar J, Martin AD. Inspiratory muscle training in a child with nemaline myopathy and organ transplantation. *Pediatr Crit Care Med* 2011;12:e94-8.
16. Nagata R, Kamimura D, Suzuki Y, et al. A case of nemaline myopathy with associated dilated cardiomyopathy and respiratory failure. *Int Heart J* 2011;52:401-5.
17. Kelly E, Farrell MA, McElvaney NG. Adult-onset nemaline myopathy presenting as respiratory failure. *Respir Care* 2008;53:1490-4.