

Supplementary Materials: Intradermal Application of Crostamine Induces Inflammatory and Immunological Changes in Vivo

Ana Vitória Pupo Silvestrini, Luana Henrique de Macedo, Thiago Antônio Moretti de Andrade, Máira Felonato Mendes, Acácio Antônio Pígozo and Maurício Ventura Mazzi

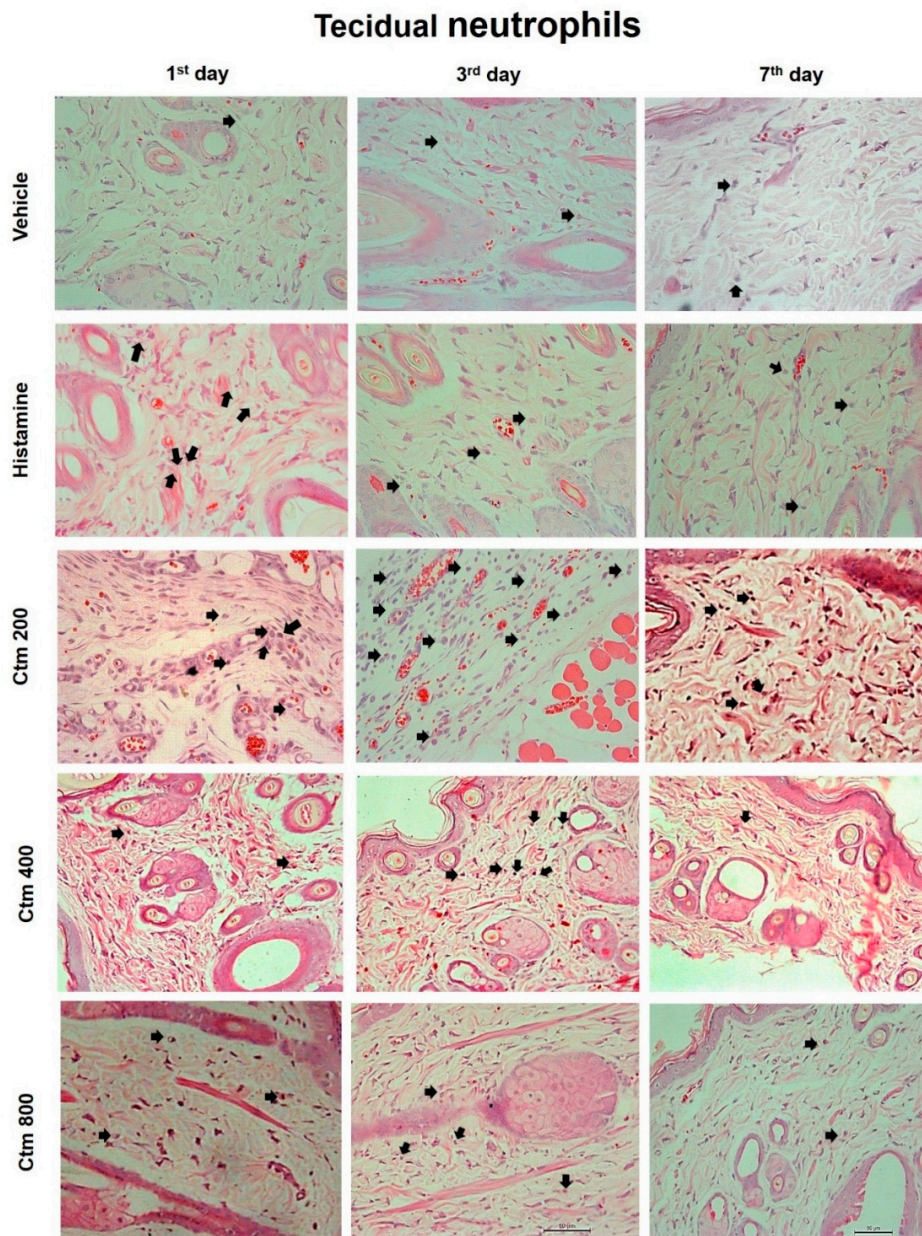


Figure S1. Increased tecidual neutrophils induced by intradermal injection of crostamine after 1, 3, and 7 days. Representative photomicrograph (HE-200 ×magnification) highlighting the inflammatory infiltrate (black arrow). The sections were stained with hematoxylin method and analyzed by light field microscopy.