

Supplementary Material: The Expression Profile and Textural Characteristics of C595-Reactive MUC1 in Pancreatic Ductal Adenocarcinoma for Targeted Radionuclide Therapy

Ashleigh Hull, Yanrui Li, Dylan Bartholomeusz, William Hsieh, Samantha Escarbe, Andrew Ruszkiewicz and Eva Bezak

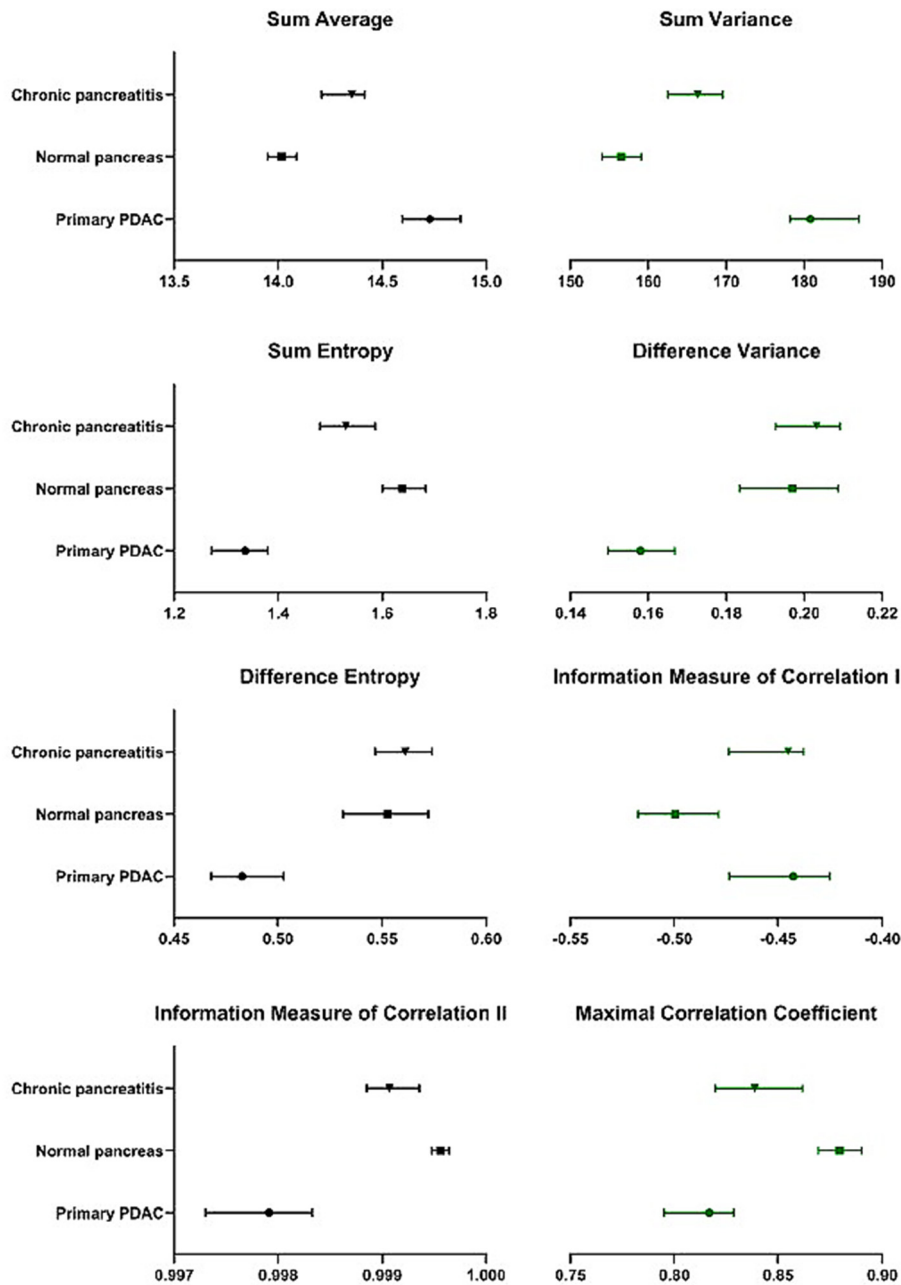


Figure S1. Median and 95% confidence intervals for derived Haralick features for PDAC, chronic pancreatitis and normal pancreas tissue samples.