

Review

Multimodal Management of Grade 1 and 2 Pancreatic Neuroendocrine Tumors

Ugo Marchese ^{1,*}, Martin Gaillard ¹, Anna Pellat ², Stylianos Tzedakis ¹, Einas Abou Ali ², Anthony Dohan ³, Maxime Barat ³, Philippe Soyer ³, David Fuks ¹ and Romain Coriat ²

- ¹ Department of Digestive, Hepatobiliary and Pancreatic Surgery, Cochin Teaching Hospital, AP-HP, Université de Paris, 27 rue du Faubourg Saint-Jacques, 75014 Paris, France; martin.gaillard@aphp.fr (M.G.); stylianos.tzedakis@aphp.fr (S.T.); david.fuks@aphp.fr (D.F.)
- ² Gastroenterology and Digestive Oncology Unit, Cochin Teaching Hospital, AP-HP, Université de Paris, 27 rue du Faubourg Saint-Jacques, 75014 Paris, France; anna.pellat@aphp.fr (A.P.); einas.abouali@aphp.fr (E.A.A.); romain.coriat@aphp.fr (R.C.)
- ³ Department of Radiology, Cochin Teaching Hospital, AP-HP, Université de Paris, 27 rue du Faubourg Saint-Jacques, 75014 Paris, France; anthony.dohan@aphp.fr (A.D.); maxime.barat@aphp.fr (M.B.); philippe.soyer@aphp.fr (P.S.)
- * Correspondence: ugo.marchese@aphp.fr; Tel.: +33-1-58-41-39-03

Simple Summary: As we are facing an increasing incidence of pancreatic neuroendocrine tumors (pNETs), it appears necessary to better classify this disease—and in 2017 the WHO classification introduced a new category of well differentiated grade 3 tumors. pNETs treatment requires some specific background and recent reviews on the multimodal management of this disease are missing. Indeed, those modalities constantly evolve and this review, focusing on Grade 1 and Grade 2 pNETs, aims to clarify both oncological and surgical treatment options from localized tumors to multi metastatic disease. Every aspect of the strategy are discussed in this review from the oncologist and the surgeon's point of view and with a special focus on a minimally invasive approach.



Citation: Marchese, U.; Gaillard, M.; Pellat, A.; Tzedakis, S.; Abou Ali, E.; Dohan, A.; Barat, M.; Soyer, P.; Fuks, D.; Coriat, R. Multimodal Management of Grade 1 and 2 Pancreatic Neuroendocrine Tumors. *Cancers* **2022**, *14*, 433. <https://doi.org/10.3390/cancers14020433>

Academic Editor: Luis Bujanda

Received: 2 December 2021

Accepted: 13 January 2022

Published: 15 January 2022

Publisher's Note: MDPI stays neutral with regard to jurisdictional claims in published maps and institutional affiliations.

Abstract: Pancreatic neuroendocrine tumors (p-NETs) are rare tumors with a recent growing incidence. In the 2017 WHO classification, p-NETs are classified into well-differentiated (i.e., p-NETs grade 1 to 3) and poorly differentiated neuroendocrine carcinomas (i.e., p-NECs). P-NETs G1 and G2 are often non-functioning tumors, of which the prognosis depends on the metastatic status. In the localized setting, p-NETs should be surgically managed, as no benefit for adjuvant chemotherapy has been demonstrated. Parenchymal sparing resection, including both duodenum and pancreas, are safe procedures in selected patients with reduced endocrine and exocrine long-term dysfunction. When the p-NET is benign or borderline malignant, this surgical option is associated with low rates of severe postoperative morbidity and in-hospital mortality. This narrative review offers comments, tips, and tricks from reviewing the available literature on these different options in order to clarify their indications. We also sum up the overall current data on p-NETs G1 and G2 management.

Keywords: pancreatic neuroendocrine tumor; pancreatectomy; pancreatic sparing surgery; enucleation; chemotherapy; therapeutic strategy



Copyright: © 2022 by the authors. Licensee MDPI, Basel, Switzerland. This article is an open access article distributed under the terms and conditions of the Creative Commons Attribution (CC BY) license (<https://creativecommons.org/licenses/by/4.0/>).

1. Introduction, Epidemiology and Staging

Neuroendocrine neoplasms (NENs) originate from neuroendocrine cells present throughout the endocrine system. Pancreatic neuroendocrine tumors (p-NETs) arise from pancreatic stem cells that can differentiate into exocrine and endocrine but also directly from neuroendocrine cells in the pancreas [1,2]. p-NETs were previously regarded as rare, but their incidence has increased over the last 20 years [3]. A Japanese study published in 2005 showed a high incidence of p-NETs (1.01 per 100,000) [4] compared to incidence usually considered in the United States (0.3–0.4 per 100,000) [5]. Peak age ranges from 50 to 70 years, and incidence increases with age.

Most p-NETs are non-functioning and symptoms usually stem from distant metastases or sometimes from mass effects [6,7].

In 2017, the World Health Organization (WHO) updated the grading system for the pathological classification of p-NENs, based on the Ki-67 index and mitotic counts [2]. Tumors with a Ki-67 index of $\leq 2\%$, 3–20% or $>20\%$ were classified as G1, G2 and G3, respectively. Until 2017, pancreatic carcinoid neoplasms were defined as G1/G2 p-NETs, while pancreatic neuroendocrine carcinoma (p-NEC) was defined as G3 (Table 1). The 2017 classification introduced a new entity of p-NETs, the p-NETs G3 [8]. While this group of well-differentiated G3 p-NETs respond poorly to platinum-based chemotherapy compared to low differentiated G3 p-NEC, they are associated with longer median survival [9]. This group of G3 p-NETs should be distinguished from G1/G2 p-NETs and will not be discussed in the present review.

Table 1. The 2019 World Health Organization (WHO) classification for neuroendocrine neoplasms (NEN) of the digestive tract.

Well-Differentiated	Ki-67 Index (%)
NET ¹ G1 (low-grade)	<3
NET G2 (intermediate-grade)	3–20
NET G3 (high-grade)	>20
Poorly differentiated NEN	
NEC ² G3 Small-cell type or Large-cell type	>20
Mixed neuroendocrine-nonneuroendocrine neoplasm (MiNEN)	

¹ NET: neuroendocrine tumor, ² NEC: neuroendocrine carcinoma.

The 5-year survival rate of patients with p-NETs is estimated to be 85% for all stages, 65–100% in localized, 35% in regional and 20% in metastatic diseases. The 5-year survival rate of patients increases when managed in dedicated centers [10]. According to the Surveillance, Epidemiology, and End Results (SEER) database, 53% of patients with NETs present with localized disease, 20% have locoregional disease, and 27% have distant metastases at the time of diagnosis [5]. Individuals with a family history of NETs in a first-degree relative have a 3.6-fold increased risk of disease [11]. No environmental risk factors have been identified yet.

Preoperative endoscopic ultrasonography with biopsy for histopathological confirmation is mandatory. Preoperative staging should also include morphological evaluation and, whenever possible, functional evaluation by ⁶⁸gallium-positron emission tomography/CT (PET/CT). However, all tumors do not express a significant number of somatostatin type 2 receptors (SSTR). Therefore, DOTA-TOC PET/CT should always be associated with preoperative CT or magnetic resonance imaging (MRI). PET/CT with specific tracers such as ¹¹C-5HTP, ¹⁸F-DOPA or ¹⁸F-FDG can further optimize the staging of the disease [12–14]. Endoscopy associated with biochemical analysis of relevant biomarkers such as pCgA are often helpful in these situations.

Approximately 10% of p-NETs are due to an inherited syndrome, which includes multiple endocrine neoplasia type 1 (MEN1), von Hippel-Lindau disease (VHL), neurofibromatosis type 1 (NF1), and tuberous sclerosis complex (TSC) [15]. In patients with sporadic p-NETs, 20 to 40% express somatic mutation of *MEN1* or other specific mutations such as *DAXX*, *ATRX* and *TSC2* [16,17].

2. Multimodal Management of Localized Disease

2.1. Indications

Localized NETs' treatment strategy depends on tumor diameter, tumor location, and patient condition. If feasible, surgery is the best option and is often the best treatment for most localized p-NETs, except for incidental lesions. Indeed, the incidence of early p-NETs has increased significantly [18]. Several series and a review published by Partelli S et al. in 2017 [19] suggested that patients with incidental tumors less than 2 cm in diameter experienced a limited risk of tumor recurrence and were all alive at 5 years. The European Neuroendocrine Tumor Society (ENETS) guidelines then proposed a “watch and wait” policy in asymptomatic patients with sporadic < 2 cm low-grade (G1) p-NETs [20]. Histopathological confirmation is mandatory in this situation [21], but no consensus has emerged regarding the follow-up protocol. A first computed tomography (CT) or magnetic resonance imaging (MRI) examination at 6 months from diagnosis followed by CT or MRI examination every year seems to be a safe option.

Surgery including either standard or atypical pancreatic resections represents the gold standard for p-NETs > 2 cm in symptomatic forms in the case of functional tumors and/or in G2 tumors. Carcinoid syndrome cannot appear in localized form as it is related to serotonin secretion from liver metastases (LM) but not from the primary pancreatic tumor. Indeed, the hormones released into the portal vessels are metabolized by the liver. Lymphadenectomy's impact on patients' oncological outcomes is still unclear [22]. The rate of mortality after pancreatic standard resections in high volume centers remains acceptable (<5%), even if the postoperative complication rates remain high (40–50%) [23,24]. These radical pancreatectomies are associated with a significant rate of long-term exocrine and endocrine insufficiencies [25]. There is no place for adjuvant chemotherapy in this setting.

2.2. Minimally Invasive Approach

In 1994, the first descriptions of minimally invasive pancreatic procedures were reported, consisting of laparoscopic pylorus-preserving pancreatoduodenectomy and laparoscopic pancreatic distal resection [26].

Because of the rarity of p-NETs, no specific comparative studies have reported the perioperative outcomes of minimally invasive surgery in this indication. A review by Drymoussis et al. including 11 studies published between 1994 and 2012 on laparoscopic and open pancreatic procedures in 906 patients with p-NETs reported that in the laparoscopic group, there was a reduced overall complication rate and length of stay but no differences in mortality, operative time or pancreatic fistula rates [27]. Only two patients undergoing pancreaticoduodenectomy were included, while most of the resections were distal pancreatectomy and enucleation. Most series reported a 10 to 40% conversion rate.

From the perspective of pancreatic adenocarcinoma and given oncological results, including surgical margins and harvested lymph nodes, the laparoscopic approach in distal pancreatectomy (LDP) allows for similar results with an open approach [28]. In a nationwide analysis, De Rooij et al. showed the superiority of the LDP for benign and malignant pancreatic tumors regarding the occurrence of major complications and the length of hospital stay [29]. The same group conducted a prospective controlled randomized trial to compare LDP to the open procedure (LEOPARD-Trial) that demonstrated the benefits of the minimally invasive approach [30]. However, the LEOPARD trial for distal pancreatectomy included not only p-NETs but also other pancreatic diseases such as adenocarcinoma.

Standard pancreatoduodenectomy remains necessary when enucleation cannot be considered. Laparoscopic pancreaticoduodenectomy (LPD) has seen much slower adoption than other laparoscopic procedures as it represents a true technical challenge, especially when it comes to reconstruction. Concerns remain regarding the long learning curve of LPD, potential higher morbidity and mortality rates, and the need to perform a high number of procedures (more than 40 procedures) to achieve equivalent outcomes to the open approach [31]. Since 2017, three trials and one meta-analysis have compared the short-term outcomes of LPDc versus open pancreaticoduodenectomy [32–34]. No dif-

ferences were observed, except for lower blood loss and longer operative time with the laparoscopic approach.

Recently, the multicenter randomized LEOPARD-2 trial had to be stopped prematurely because of safety concerns regarding a higher mortality rate after LPD, although overall 90-day mortality (five of 50 patients (10%) in the LPD group vs. one of 49 (2%) in the open pancreatoduodenectomy group; risk ratio (RR): 4.90 (95% CI: 0.59–40.44); $p = 0.20$) and severe complication rate (14 (28%) in the LPD group vs. 12 (24%) in the open pancreatoduodenectomy group; RR: 1.14 (95% CI: 0.59–2.22); $p = 0.69$) were not significantly different [35]. In light of these results, LPD seems to remain a technical step too complex to allow for the safe diffusion of this technique. In this setting, the French Health Agency has recently both promoted the LDP and banned LPD outside a prospective trial inclusion. There is a high probability that several national health agencies will take a similar decision if no series invalidate these disappointing results.

Finally, total pancreaticoduodenectomy could be an option for multifocal p-NETs as they might occur in patients with MEN1 and VHL syndrome. In these selected patients, laparoscopic total pancreatectomy has been successfully performed [36]. However, there are no data comparing laparoscopic to open total pancreatectomy in p-NETs.

2.3. Robotic Approach

The first robotic-assisted distal pancreatectomy for the treatment of p-NETs was reported in 2002 using the DaVinci[®] (Intuitive Surgical, Sunnyvale, CA, USA) robotic surgical system [37]. Robotic assistance was helpful to increase the spleen preservation rate in distal pancreatectomy due to better depth perception owing to the use of three-dimensional representation, tremor elimination and seven degrees freedom of movement [38,39].

In a retrospective study, Zhang et al. compared 43 patients who underwent robotic distal pancreatectomy with 31 patients who underwent laparoscopic distal pancreatectomy for the treatment of p-NETs [40]. Again, a higher rate of spleen preservation was observed in the robotic group (79.1% vs. 48.4%; $p = 0.006$) as well as a number of lymph nodes harvested for G2 and G3 p-NETs (3.5 vs. 2; $p = 0.034$). Daouadi et al. also confirmed these findings in a retrospective analysis of 124 patients and noticed a reduced conversion rate in robotic-assisted distal pancreatectomy (0% vs. 16% in the laparoscopic approach; $p < 0.05$) and reduced operating time (293 ± 93 (SD) min vs. 372 ± 141 (SD) min; $p < 0.01$) [41]. On the contrary, a longer robot operative time was observed by Ryan et al. when compared with the laparoscopic approach (221.4 vs. 173.6 min; $p = 0.026$) in a prospective observational study [42], and similar results were reported by Lai et al. [43]. However, when splenectomy is mandatory, robotic assistance has not demonstrated advantages for distal pancreatectomy [44].

Even if the experience remains limited, a few centers have reported a perioperative mortality rate from 0 to 5% and a pancreatic fistula rate from 0 to 35% after robotic-assisted pancreatoduodenectomy [45,46]. These results are similar to those obtained with open surgery. Interestingly, the learning curve was significantly improved after the first 20 performed procedures; however, improvement concerning pancreatic fistula appears only after 40 performed procedures and operative time after 80 procedures [46]. Conversion rate after completion of the learning curve was 3.3%, mortality was 3.3% and grade B/C pancreatic fistula rate was 6.9%.

2.4. Enucleation

Patients with functional p-NETs usually have small tumors at the time of diagnosis, particularly pancreatic insulinomas, which are benign in 80–90% of patients. Considering the usually small size of tumors at diagnosis, parenchyma-preserving limited pancreatic resection such as pancreatic enucleation should be considered [47,48]. According to guidelines, pancreatic enucleation is an excellent option if the tumor is exophytic or located close to the surface and with a minimum distance of 2–3 mm to the main pancreatic duct [49].

Concerning nonfunctional pNETs: on the one hand, non-functional p-NETs are supposed to present more aggressive behavior, especially tumors larger than 2 cm, and radical resection with lymphadenectomy should be performed [17]. On the other hand, many recent data support the feasibility of the “watch and wait” policy for asymptomatic nonfunctional p-NETs < 2 cm as it was first proposed in MEN1 patients. Indication of enucleation is unclear and even if pancreatic enucleation allows us to spare the pancreatic parenchyma and function, it has not proven its positive impact on postoperative outcomes and should not be proposed as an alternative to radical resection for patients who are candidates for surgery.

However, the distinction between benign and malignant p-NETs based on tumor diameter should be drawn cautiously, as even small tumors can be aggressive with lymph node involvement [49]. Conversely, some groups have claimed that local lymphadenectomy should not be considered routinely, even for G1 non-functional p-NETs [50] since no clear oncological benefit is demonstrated.

Minimally invasive experience in pancreatic enucleation included mostly small series. Along with a retrospective series of 15 laparoscopic pancreatic enucleations and 22 open pancreatic enucleations, Zhang et al. observed similar mortality and morbidity. Up to 20% of the patient in the laparoscopic group had a pancreatic fistula grade B/C versus 36.4% in the open group ($p = 0.874$) [51]. They also observed a significantly shorter operating time (118.2 ± 33.1 (SD) min vs. 155.2 ± 44.3 (SD) min; $p = 0.004$), lower estimated blood loss (80.0 ± 71.2 (SD) mL vs. 195.5 ± 103.4 (SD) mL; $p = 0.001$), shorter first flatus time (1.8 ± 1.0 (SD) days vs. 3.4 ± 1.8 (SD) days; $p = 0.004$) and shorter hospital stay (2.4 ± 1.0 (SD) vs. 4.4 ± 2.0 (SD) days; $p = 0.001$). During the follow-up (median 47 months), no local recurrence or distant metastases occurred in either group [52]. It should be noted that there is a relevant risk for pancreatic fistula after pancreatic enucleation. Karaliotas et al. showed similar pancreatic fistula rates in open group and in laparoscopic group pancreatic enucleation (29% vs. 20%, respectively; $p = 0.65$) [53] but the pancreatic fistula rate was lower in the laparoscopic group in Sa Cunha et al.’s series (14% vs. 100%, respectively; $p = 0.015$) [54]. Therefore, the superiority of laparoscopic pancreatic enucleation should be confirmed by further trials.

2.5. Non-Sporadic p-NETs

Indication of surgery for nonfunctional pNETs is conditioned mostly by the size of the lesion > 2 cm [55]. The same strategy can be proposed for gastrinoma but regardless of their size, the resection of insulinomas, VIPomas, and glucagonomas is recommended [56]. In the particular setting of MEN1, virtually all patients may present with multiple lesions and additional non-functional p-NETs and it can be challenging because of possible difficulties in identifying multiple tumors within the pancreatic parenchyma. Spleen preserving distal pancreatectomy or pancreatic enucleation is a successful approach in 83 to 100% of patients with a single p-NET [57,58].

P-NETs also occur in patients with VHL disease, a hereditary, multi-organ tumor disease, with hemangioblastomas, pheochromocytomas and renal clear cell carcinomas [59]. P-NETs are found in 8% to 17% of patients with VHL disease. They are usually non-functional but should be distinguished from cystic benign pancreatic lesions that are frequent in this disease. They are considered less invasive than non-functional p-NETs without VHL because they are usually discovered before symptoms appear, during surveillance of VHL disease [60]. A cut-off of 30 mm or more is used to decide on surgical resection given the risk of metastases [61].

3. Multimodal Strategy for Advanced p-NETs

3.1. Medical Treatment Options

Medical treatment can either be proposed in the neoadjuvant setting for patients with important initial tumor burden or for unresectable advanced p-NETs. In the meantime, no clear data support the medical treatment of p-NETs in a neoadjuvant setting and

this strategy should be considered cautiously. Several types of treatments are currently available and the choice of molecule needs to consider the patient's general state as well as the tumor's aggressiveness.

3.2. Cytotoxic Chemotherapy

Chemotherapy is the usual first-line treatment in aggressive metastatic p-NETs with important hepatic tumor burden. Various combinations of chemotherapy are validated in G1/G2 p-NETs. Streptozocin (SPTZ) combined to fluorouracil and doxorubicine (DOX) showed positive results in the treatment of well-differentiated p-NETs with a response rate of 39% [62]. Several studies have also shown the efficacy of SPTZ associated with 5-fluorouracil (5-FU) or DOX [63–65]. Because of toxicity, the combination of SPTZ and 5-FU is now favored. The combination of temozolomide and capecitabine (TEMCAP) showed a 70% response rate and a median progression-free survival (PFS) of 18 months in a population of 30 patients [66]. Preliminary results of a recent phase II trial involving 144 patients with p-NETs comparing temozolomide alone to TEMCAP showed improved OS and PFS with TEMCAP [67]. A retrospective analysis comparing TEMCAP to 5-FU and dacarbazine (DTIC) suggested longer PFS with 5-FU-DTIC, although the TEMCAP regimen was often preferred due to its oral administration [68]. Finally, an oxaliplatin-based regimen can be proposed as an alternative based on interesting results in small populations of p-NETs [69,70].

There is little data regarding the efficacy of chemotherapy in the second-line setting. One single-center study found a 17% response rate in 18 patients with progressive disease treated with gemcitabine and oxaliplatin (GEMOX) [71]. In clinical practice, previous regimens are also used in the second-line setting in the case of progressive disease under another type of treatment.

3.3. Somatostatin Analogs (SSA)

SSA are often used to control p-NET-related symptoms (secretory syndrome). The phase III CLARINET trial comparing lanreotide vs. placebo in metastatic nonfunctional G1/G2 enteropancreatic NET validated SSA efficacy in these patients. Lanreotide was associated with significantly prolonged PFS (median not reached vs. median of 18 months, $p < 0.001$; hazard ratio (HR) for progression or death of 0.47; 95% CI: 0.30–0.73) [72]. SSA are mainly proposed in the first-line setting of advanced p-NETs with low hepatic tumor burden and slow disease progression.

3.4. Targeted Therapy

A number of targeted therapeutic agents, especially those inhibiting molecules involving angiogenesis or growth factor receptor-related signal pathways have been evaluated in p-NETs [73,74]. Sunitinib and everolimus are currently the two drugs approved in both the USA and Europe to treat patients with well-differentiated p-NETs in the second-line setting.

3.4.1. Agents for Antiangiogenesis

P-NETs are hypervascular tumors associated with intense expression of vascular endothelial growth factor (VEGF), VEGF receptor (VEGFR) and platelet derived growth factor receptor (PDGFR) [75–77].

Sunitinib is a tyrosine kinase inhibitor (TKI), which targets multiple receptors such as PDGFR and VEGFR [78]. In 2011, a phase III randomized controlled trial confirmed that sunitinib was efficient at increasing PFS (11.4 months vs. 5.5 months; $p < 0.001$) and objective response rates (9.3% vs. 0%; $p = 0.007$) in a population of progressive p-NETs [79]. The most frequent grade 3/4 adverse events with sunitinib were neutropenia (12%), hypertension (10%) and fatigue (5%) [79].

Sorafenib, another TKI, showed interesting results in the treatment of chemoresistant metastatic enteropancreatic NETs. Partial responses (PR) were observed in 22% of patients with p-NETs. [80].

Pazopanib, another TKI, was evaluated in a phase-2 study. Pazopanib was administered to 52 patients with advanced low-grade NETs who received pazopanib (800 mg/day orally) and octreotide. In the p-NETs group, five patients had PR (RECIST), and the median PFS was 11.7 months [81].

Bevacizumab is a monoclonal antibody directed against VEGF. Combination therapies with bevacizumab have also been investigated in p-NETs. In 34 patients with advanced NETs, the combination of bevacizumab and temozolomide showed a 33% response rate in 15 patients with p-NETs [82]. In the non-randomized BETTER trial, bevacizumab associated with 5-FU and SPTZ showed a significant disease control rate (56% PR and 44% stabilization) in patients with progressive metastatic p-NETs [83]. The ongoing randomized BETTER2 trial will evaluate the effect of bevacizumab combined with chemotherapy in the first-line setting (NCT03351296).

Finally, lenvatinib, a multikinase inhibitor, has shown promising results in a phase II trial in patients with advanced p-NETs. The overall response rate was 44.2% in the pre-treated p-NET population [84].

3.4.2. mTOR Inhibitors

mTOR is an intracellular protein kinase that participates in PI3K/Akt signal transduction. Everolimus had shown promising antitumor activity in two phase II trials involving p-NETs [85,86]. Later, in a double-blind phase III trial, everolimus reduced the estimated risk of progression or death by 65% and significantly increased the median PFS from 5.4 to 11 months (HR, 0.35; $p < 0.001$) in patients with low- or intermediate-grade progressive p-NETs [87]. The estimates of 18-month PFS were 34% for patients treated with everolimus compared to 9% for patients receiving a placebo [87]. Given those results the rapamycin analog everolimus is approved for the treatment of p-NETs.

3.5. Peptide Receptor Radionuclide Therapy (PRRT)

The efficacy of PRRT (Lutetium-177 (177Lu)-Dotatate) combined with SSA was proven in the prospective phase III NETTER-1 trial in 229 patients with advanced well-differentiated midgut NET [88]. Positive results with PRRT were also found in a retrospective study for advanced G1/G2 p-NETs [89]. Indeed, there was an overall response of 55% and a median PFS of 30 months in a population of 133 advanced p-NETs. Overall, PRRT can be proposed in the second-line setting for advanced p-NETs.

3.6. External Radiotherapy

Several retrospective studies have suggested that external beam radiotherapy and stereotactic body radiotherapy is well tolerated and showed encouraging activity with a good local control on the primary tumors [90,91] but also in metastatic locations of the disease [92,93] and should be considered for further investigation.

4. Surgical Management of Advanced p-NETs

Surgical treatment of advanced and/or metastatic NETs remains controversial. Concerning p-NETs, surgery should always be included in a multimodal approach among different treatments available, including somatostatin analogs, PRRT, targeted therapies (everolimus and sunitinib), and chemotherapy [94]. Even if the impact of liver metastases (LM) resection on survival remains unclear, the resection of both LM and primary tumor should be discussed, especially for well differentiated p-NETs if R0 resection could be achieved [95–97]. In order to control hormonal symptoms, some patients presenting with functioning tumors will be considered for cytoreductive surgical procedures. In the meantime, if the risk–benefit balance seems favorable to surgery regarding patient comorbidities, borderline equivalent or even locally advanced patients will be candidates for pancreatic resection extended to adjacent organs [98]. The ENETS guidelines' criteria to recommend surgical treatment of LM coming from digestive NETs include the differentiation of the lesions (Ki67 < 5%), the absence of extra-abdominal disease or peritoneal carcinomatosis

and the absence of right cardiac insufficiency [99]. Surgery should also be considered in selected cases of symptomatic oligo-metastatic extra-hepatic disease [100].

4.1. Surgery of Liver Metastases

At diagnosis, curative resection cannot be achieved in more than 80% of patients with LM [101]. If surgical cytoreduction of at least 90% of LMs is possible using either surgery or percutaneous ablative procedures, those procedures should be proposed [102–104] and are associated with an improvement in both functional and non-functional symptoms in 90 to 100% of patients and 5-years and 10-years overall survival around 46–86% and 35–79%, respectively [105–116]. For LM < 2 cm, radiofrequency ablation is safe and provides effective control of symptoms with a low recurrence rate. [117,118]. Elias et al. reported that preoperative imaging is not sufficiently sensitive and misses half of the liver metastasis [119] but new imaging techniques such as gallium TEP/CT will probably provide better results in preoperative patient screening.

4.2. Management of Primary Tumor

Despite the high risk of recurrence, combined pancreatic and metastatic treatment remains the best option whenever possible to obtain long-term survival [120,121]. However, resection of pancreatic tumors in the presence of unresectable LM should be selectively considered in patients with symptomatic non-functioning p-NETs [122,123] and in low-risk patients with life-threatening symptoms [124]. Regarding p-NETs, in a systematic review including one prospective study and two retrospective studies, a greater 5-year survival rate was observed in patients who had their primary tumor resected [125–128].

4.3. Liver-Directed Therapies

In the metastatic setting, liver-directed intra-arterial therapies can be performed alone or in combination with surgery. These therapies include trans-arterial embolization, trans-arterial chemoembolization (with doxorubicin or streptozotocin), as well as radioembolization. Although the data mostly comes from retrospective small-sample sized studies, liver-directed therapies have shown good clinical and morphological responses for well-differentiated G1 and G2 NET, especially when the liver burden is important or in the presence of a secretory syndrome [129,130]. To date, data are still lacking to recommend one intra-arterial therapy over another, but there seems to be a trend of superiority for chemoembolization in p-NETs [130].

4.4. Minimally Invasive Approach

The role of minimally invasive hepatic resection in p-NETs with liver metastases follows the same principles as in open resection [131–134]. The minimally invasive approach reduces the length of stay, allows faster postoperative recovery and easier iterative hepatectomy if necessary [135].

From a scientific point of view, only a few series focused on laparoscopic resection for NET with liver metastases showing similar outcomes in the laparoscopic group compared to the open group [136,137].

Detectability remains an important matter of concern when treating metastatic NETs with minimally invasive surgery. In the future, intraoperative contrast-enhanced ultrasound imaging could be of significant assistance [138].

4.5. Liver Transplantation

A review of the European Liver Transplant Registry (ELTR) data showed that transplant experience in NET patients is limited [139–142]. Some expert centers have suggested the use of strict inclusion criteria to consider liver transplantation in metastatic NETs such as (i) well-differentiated NETs (Ki-67 < 5%); (ii) portosystemic tumor drainage; (iii) young patients < 55 years; (iv) stable disease for at least 6 months; (v) pre-transplant R0 primary tumor resection; (vi) hepatic tumor involvement < 50% of the liver volume; and (vii) absence

of extra-hepatic disease [143]. In the European series published by Le Treut et al. [144], 17% of patients died from early or late complications of liver transplantation and the 5-year OS rate was 52% with a disease-specific survival rate of 30%. These results suggest that liver transplantation should be considered an option in highly selected patients with liver metastases from p-NETs that are not accessible to other treatments.

5. Conclusions

P-NETs are a heterogeneous type of pancreatic tumor associated with good prognosis compared to pancreatic adenocarcinoma. Due to the rarity of the disease, many questions are still unanswered regarding the optimal treatment strategy for p-NETs. Indeed, comparative studies are scarce in the literature. In the case of localized disease, minimally invasive surgery, including parenchymal sparing procedure, should be preferred. Laparoscopic surgery provides a real advantage while preserving surgical oncological principles and, in the future, robotic-assisted surgery could overcome the laparoscopic approach. Functioning p-NETs are usually detected early because of specific symptoms. On the contrary, in the case of a non-functioning P-NETs a high range of patients show synchronous metastases at diagnosis mainly located in the liver. However, whenever possible, surgical resection should be attempted in combination with liver-directed therapy. In the setting of aggressive unresectable disease, combining therapies with SSA or cytotoxic chemotherapy should be considered first. Sunitinib, everolimus and PRRT also play a relevant role in the second-line treatment of p-NETs. Early clinical trial results support the idea that small-molecule-targeted therapies are efficient in the treatment of p-NETs. In the future, biomarker identification should predict responses to specific therapies, which can be used to guide the selection of treatments.

We propose the following therapeutic algorithm for the management of p-NET G1/G2 (Figure 1).

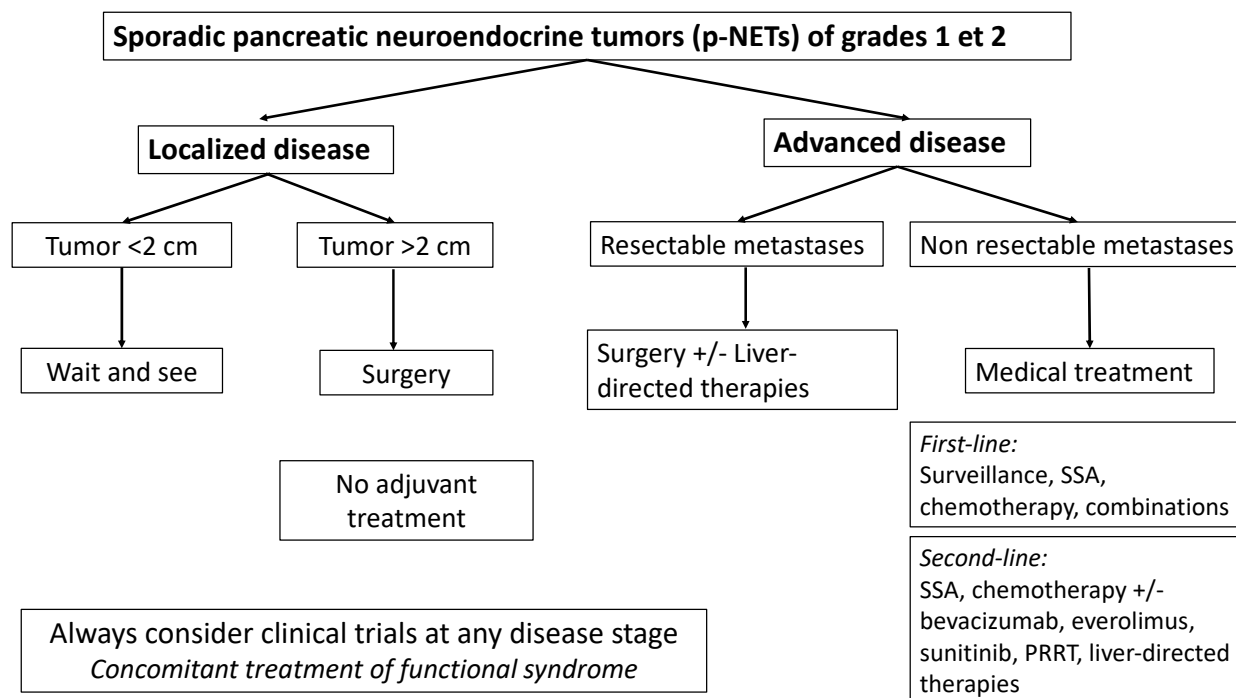


Figure 1. Proposed therapeutic algorithm for sporadic, well-differentiated grade 1 and 2 pancreatic neuroendocrine tumors (p-NETs). SSA: somatostatin analogues, PRRT: Peptide receptor radionuclide therapy.

Author Contributions: Conceptualization, U.M. and D.F.; methodology, A.P.; validation, D.F. and A.D.; resources, M.B., S.T., and E.A.A.; writing—original draft preparation, U.M.; writing—review and editing, M.G., A.P., P.S., and D.F.; supervision, R.C.; project administration, D.F. All authors have read and agreed to the published version of the manuscript.

Funding: This research received no external funding.

Conflicts of Interest: The authors declare no conflict of interest.

References

- Ehehalt, F.; Saeger, H.D.; Schmidt, C.M.; Grützmann, R. Neuroendocrine Tumors of the Pancreas. *Oncologist* **2009**, *14*, 456–467. [[CrossRef](#)]
- Klöppel, G.; Hruban, R.H. *WHO Classification of Tumours of Endocrine Organs*; International Agency for Research on Cancer: Lyon, France, 2017.
- Dasari, A.; Shen, C.; Halperin, D.; Zhao, B.; Zhou, S.; Xu, Y.; Shih, T.; Yao, J.C. Trends in the Incidence, Prevalence, and Survival Outcomes in Patients With Neuroendocrine Tumors in the United States. *JAMA Oncol.* **2017**, *3*, 1335–1342. [[CrossRef](#)] [[PubMed](#)]
- Ito, T.; Lee, L.; Hijioka, M.; Kawabe, K.; Kato, M.; Nakamura, K.; Ueda, K.; Ohtsuka, T.; Igarashi, H. The Up-to-Date Review of Epidemiological Pancreatic Neuroendocrine Tumors in Japan. *J. Hepatobiliary Pancreat. Sci.* **2015**, *22*, 574–577. [[CrossRef](#)] [[PubMed](#)]
- Man, D.; Wu, J.; Shen, Z.; Zhu, X. Prognosis of patients with neuroendocrine tumor: A SEER database analysis. *Cancer Manag. Res.* **2018**, *10*, 5629–5638. [[CrossRef](#)]
- Díez, M.; Teulé, A.; Salazar, R. Gastroenteropancreatic Neuroendocrine Tumors: Diagnosis and Treatment. *Ann. Gastroenterol.* **2013**, *26*, 29–36.
- Ter-Minassian, M.; Chan, J.A.; Hooshmand, S.M.; Brais, L.K.; Daskalova, A.; Heafield, R.; Buchanan, L.; Qian, Z.R.; Fuchs, C.S.; Lin, X.; et al. Clinical Presentation, Recurrence, and Survival in Patients with Neuroendocrine Tumors: Results from a Prospective Institutional Database. *Endocr. Relat. Cancer* **2013**, *20*, 187–196. [[CrossRef](#)] [[PubMed](#)]
- Azoulay, A.; Cros, J.; Vullierme, M.P.; de Mestier, L.; Couvelard, A.; Hentic, O.; Ruszniewski, P.; Sauvanet, A.; Vilgrain, V.; Ronot, M. Morphological imaging and CT histogram analysis to differentiate pancreatic neuroendocrine tumor grade 3 from neuroendocrine carcinoma. *Diagn. Interv. Imaging.* **2020**, *101*, 821–830. [[CrossRef](#)]
- Pellat, A.; Cottreau, A.S.; Palmieri, L.-J.; Soyer, P.; Marchese, U.; Brezault, C.; Coriat, R. Digestive Well-Differentiated Grade 3 Neuroendocrine Tumors: Current Management and Future Directions. *Cancers* **2021**, *13*, 2448. [[CrossRef](#)]
- Yang, M.; Zeng, L.; Ke, N.; Tan, C.; Tian, B.; Liu, X.; Xiang, B.; Zhang, Y. World Health Organization Grading Classification for Pancreatic Neuroendocrine Neoplasms: A Comprehensive Analysis from a Large Chinese Institution. *BMC Cancer* **2020**, *20*, 906. [[CrossRef](#)] [[PubMed](#)]
- Hassan, M.M.; Phan, A.; Li, D.; Dagohoy, C.G.; Leary, C.; Yao, J.C. Family History of Cancer and Associated Risk of Developing Neuroendocrine Tumors: A Case-Control Study. *Cancer Epidemiol. Biomarkers Prev.* **2008**, *17*, 959–965. [[CrossRef](#)]
- Kartalis, N.; Mucelli, R.M.P.; Sundin, A. Recent Developments in Imaging of Pancreatic Neuroendocrine Tumors. *Ann. Gastroenterol.* **2015**, *28*, 193–202. [[PubMed](#)]
- Balogova, S.; Talbot, J.-N.; Nataf, V.; Michaud, L.; Huchet, V.; Kerrou, K.; Montravers, F. 18F-Fluorodihydroxyphenylalanine vs. Other Radiopharmaceuticals for Imaging Neuroendocrine Tumours According to Their Type. *Eur. J. Nucl. Med. Mol. Imaging* **2013**, *40*, 943–966. [[CrossRef](#)]
- Schreiter, N.F.; Nogami, M.; Steffen, I.; Pape, U.-F.; Hamm, B.; Brenner, W.; Röttgen, R. Evaluation of the Potential of PET-MRI Fusion for Detection of Liver Metastases in Patients with Neuroendocrine Tumours. *Eur. Radiol.* **2012**, *22*, 458–467. [[CrossRef](#)] [[PubMed](#)]
- Geurts, J.L. Inherited Syndromes Involving Pancreatic Neuroendocrine Tumors. *J. Gastrointest. Oncol.* **2020**, *11*, 559–566. [[CrossRef](#)] [[PubMed](#)]
- Chou, W.-C.; Lin, P.-H.; Yeh, Y.-C.; Shyr, Y.-M.; Fang, W.-L.; Wang, S.-E.; Liu, C.-Y.; Chang, P.M.-H.; Chen, M.-H.; Hung, Y.-P.; et al. Genes Involved in Angiogenesis and MTOR Pathways Are Frequently Mutated in Asian Patients with Pancreatic Neuroendocrine Tumors. *Int. J. Biol. Sci.* **2016**, *12*, 1523–1532. [[CrossRef](#)]
- Jiao, Y.; Shi, C.; Edil, B.H.; de Wilde, R.F.; Klimstra, D.S.; Maitra, A.; Schulick, R.D.; Tang, L.H.; Wolfgang, C.L.; Choti, M.A.; et al. DAXX/ATRX, MEN1 and MTOR Pathway Genes Are Frequently Altered in Pancreatic Neuroendocrine Tumors. *Science* **2011**, *331*, 1199–1203. [[CrossRef](#)]
- Cheema, A.; Weber, J.; Strosberg, J.R. Incidental Detection of Pancreatic Neuroendocrine Tumors: An Analysis of Incidence and Outcomes. *Ann. Surg. Oncol.* **2012**, *19*, 2932–2936. [[CrossRef](#)] [[PubMed](#)]
- Partelli, S.; Ciocchi, R.; Crippa, S.; Cardinali, L.; Fendrich, V.; Bartsch, D.K.; Falconi, M. Systematic review of active surveillance versus surgical management of asymptomatic small non-functioning pancreatic neuroendocrine neoplasms. *Br. J. Surg.* **2017**, *104*, 34–41. [[CrossRef](#)] [[PubMed](#)]
- Partelli, S.; Ramage, J.K.; Massironi, S.; Zerbi, A.; Kim, H.B.; Niccoli, P.; Panzuto, F.; Landoni, L.; Tomazic, A.; Ibrahim, T.; et al. Management of Asymptomatic Sporadic Nonfunctioning Pancreatic Neuroendocrine Neoplasms (ASPEN) \leq 2 Cm: Study Protocol for a Prospective Observational Study. *Front. Med. (Lausanne)* **2020**, *7*, 598438. [[CrossRef](#)]

21. Larghi, A.; Capurso, G.; Carnuccio, A.; Ricci, R.; Alfieri, S.; Galasso, D.; Lugli, F.; Bianchi, A.; Panzuto, F.; De Marinis, L.; et al. Ki-67 Grading of Nonfunctioning Pancreatic Neuroendocrine Tumors on Histologic Samples Obtained by EUS-Guided Fine-Needle Tissue Acquisition: A Prospective Study. *Gastrointest. Endosc.* **2012**, *76*, 570–577. [[CrossRef](#)]
22. Lopez-Aguilar, A.G.; Zaidi, M.Y.; Beal, E.W.; Dillhoff, M.; Cannon, J.G.D.; Poultsides, G.A.; Kanji, Z.S.; Rocha, F.G.; Marincola Smith, P.; Idrees, K.; et al. Defining the Role of Lymphadenectomy for Pancreatic Neuroendocrine Tumors: An Eight-Institution Study of 695 Patients from the US Neuroendocrine Tumor Study Group. *Ann. Surg. Oncol.* **2019**, *26*, 2517–2524. [[CrossRef](#)] [[PubMed](#)]
23. Bliss, L.A.; Yang, C.J.; Chau, Z.; Ng, S.C.; McFadden, D.W.; Kent, T.S.; Moser, A.J.; Callery, M.P.; Tseng, J.F. Patient Selection and the Volume Effect in Pancreatic Surgery: Unequal Benefits? *HPB* **2014**, *16*, 899–906. [[CrossRef](#)] [[PubMed](#)]
24. El Amrani, M.; Clément, G.; Lenne, X.; Laueriere, C.; Turpin, A.; Theis, D.; Pruvot, F.-R.; Truant, S. Should All Pancreatic Surgery Be Centralized Regardless of Patients' Comorbidity? *HPB (Oxford)* **2020**, *22*, 1057–1066. [[CrossRef](#)]
25. Kahl, S.; Malfertheiner, P. Exocrine and Endocrine Pancreatic Insufficiency after Pancreatic Surgery. *Best Pract. Res. Clin. Gastroenterol.* **2004**, *18*, 947–955. [[CrossRef](#)]
26. Kamilaris, C.D.C.; Stratakis, C.A. Multiple Endocrine Neoplasia Type 1 (MEN1): An Update and the Significance of Early Genetic and Clinical Diagnosis. *Front. Endocrinol. (Lausanne)* **2019**, *10*, 339. [[CrossRef](#)]
27. Drymoussis, P.; Raptis, D.A.; Spalding, D.; Fernandez-Cruz, L.; Menon, D.; Breitenstein, S.; Davidson, B.; Frilling, A. Laparoscopic versus Open Pancreas Resection for Pancreatic Neuroendocrine Tumours: A Systematic Review and Meta-Analysis. *HPB (Oxford)* **2014**, *16*, 397–406. [[CrossRef](#)] [[PubMed](#)]
28. Van Hilst, J.; Korrel, M.; de Rooij, T.; Lof, S.; Busch, O.R.; Groot Koerkamp, B.; Kooby, D.A.; van Dieren, S.; Abu Hilal, M.; Besselink, M.G.; et al. Oncologic Outcomes of Minimally Invasive versus Open Distal Pancreatectomy for Pancreatic Ductal Adenocarcinoma: A Systematic Review and Meta-Analysis. *Eur. J. Surg. Oncol.* **2019**, *45*, 719–727. [[CrossRef](#)]
29. De Rooij, T.; Jilesen, A.P.; Boerma, D.; Bonsing, B.A.; Bosscha, K.; van Dam, R.M.; van Dieren, S.; Dijkgraaf, M.G.; van Eijck, C.H.; Gerhards, M.F.; et al. A Nationwide Comparison of Laparoscopic and Open Distal Pancreatectomy for Benign and Malignant Disease. *J. Am. Coll. Surg.* **2015**, *220*, 263–270.e1. [[CrossRef](#)]
30. De Rooij, T.; van Hilst, J.; van Santvoort, H.; Boerma, D.; van den Boezem, P.; Daams, F.; van Dam, R.; Dejong, C.; van Duyn, E.; Dijkgraaf, M.; et al. Minimally Invasive Versus Open Distal Pancreatectomy (LEOPARD): A Multicenter Patient-Blinded Randomized Controlled Trial. *Ann. Surg.* **2019**, *269*, 2–9. [[CrossRef](#)]
31. Tyutyunnik, P.; Klomp maker, S.; Lombardo, C.; Lapshyn, H.; Menonna, F.; Napoli, N.; Wellner, U.; Izrailov, R.; Baychorov, M.; Besselink, M.G.; et al. Learning Curve of Three European Centers in Laparoscopic, Hybrid Laparoscopic, and Robotic Pancreatoduodenectomy. *Surg. Endosc.* **2022**, *36*, 1515–1526. [[CrossRef](#)]
32. De Rooij, T.; Lu, M.Z.; Steen, M.W.; Gerhards, M.F.; Dijkgraaf, M.G.; Busch, O.R.; Lips, D.J.; Festen, S.; Besselink, M.G. Dutch Pancreatic Cancer Group Minimally Invasive Versus Open Pancreatoduodenectomy: Systematic Review and Meta-Analysis of Comparative Cohort and Registry Studies. *Ann. Surg.* **2016**, *264*, 257–267. [[CrossRef](#)]
33. Klomp maker, S.; van Hilst, J.; Wellner, U.F.; Busch, O.R.; Coratti, A.; D'Hondt, M.; Dokmak, S.; Festen, S.; Kerem, M.; Khatkov, I.; et al. Outcomes After Minimally-Invasive Versus Open Pancreatoduodenectomy: A Pan-European Propensity Score Matched Study. *Ann. Surg.* **2020**, *271*, 356–363. [[CrossRef](#)]
34. Yan, J.-F.; Pan, Y.; Chen, K.; Zhu, H.-P.; Chen, Q.-L. Minimally Invasive Pancreatoduodenectomy Is Associated with Lower Morbidity Compared to Open Pancreatoduodenectomy: An Updated Meta-Analysis of Randomized Controlled Trials and High-Quality Nonrandomized Studies. *Medicine (Baltimore)* **2019**, *98*, e16730. [[CrossRef](#)]
35. Van Hilst, J.; de Rooij, T.; Bosscha, K.; Brinkman, D.J.; van Dieren, S.; Dijkgraaf, M.G.; Gerhards, M.F.; de Hingh, I.H.; Karsten, T.M.; Lips, D.J.; et al. Laparoscopic versus Open Pancreatoduodenectomy for Pancreatic or Periapillary Tumours (LEOPARD-2): A Multicentre, Patient-Blinded, Randomised Controlled Phase 2/3 Trial. *Lancet Gastroenterol. Hepatol.* **2019**, *4*, 199–207. [[CrossRef](#)]
36. Zakaria, H.M.; Stauffer, J.A.; Raimondo, M.; Woodward, T.A.; Wallace, M.B.; Asbun, H.J. Total Pancreatectomy: Short- and Long-Term Outcomes at a High-Volume Pancreas Center. *World J. Gastrointest. Surg.* **2016**, *8*, 634–642. [[CrossRef](#)] [[PubMed](#)]
37. Melvin, W.S.; Needleman, B.J.; Krause, K.R.; Schneider, C.; Wolf, R.K.; Michler, R.E.; Ellison, E.C. Computer-Enhanced Robotic Telesurgery. Initial Experience in Foregut Surgery. *Surg. Endosc.* **2002**, *16*, 1790–1792. [[CrossRef](#)] [[PubMed](#)]
38. Yang, S.J.; Hwang, H.K.; Kang, C.M.; Lee, W.J. Revisiting the Potential Advantage of Robotic Surgical System in Spleen-Preserving Distal Pancreatectomy over Conventional Laparoscopic Approach. *Ann. Transl. Med.* **2020**, *8*, 188. [[CrossRef](#)]
39. Chen, S.; Zhan, Q.; Chen, J.; Jin, J.; Deng, X.; Chen, H.; Shen, B.; Peng, C.; Li, H. Robotic Approach Improves Spleen-Preserving Rate and Shortens Postoperative Hospital Stay of Laparoscopic Distal Pancreatectomy: A Matched Cohort Study. *Surg. Endosc.* **2015**, *29*, 3507–3518. [[CrossRef](#)]
40. Zhang, J.; Jin, J.; Chen, S.; Gu, J.; Zhu, Y.; Qin, K.; Zhan, Q.; Cheng, D.; Chen, H.; Deng, X.; et al. Minimally Invasive Distal Pancreatectomy for PNETs: Laparoscopic or Robotic Approach? *Oncotarget* **2017**, *8*, 33872–33883. [[CrossRef](#)]
41. Daouadi, M.; Zureikat, A.H.; Zenati, M.S.; Choudry, H.; Tsung, A.; Bartlett, D.L.; Hughes, S.J.; Lee, K.K.; Moser, A.J.; Zeh, H.J. Robot-Assisted Minimally Invasive Distal Pancreatectomy Is Superior to the Laparoscopic Technique. *Ann. Surg.* **2013**, *257*, 128–132. [[CrossRef](#)]
42. Ryan, C.E.; Ross, S.B.; Sukharamwala, P.B.; Sadowitz, B.D.; Wood, T.W.; Rosemurgy, A.S. Distal Pancreatectomy and Splenectomy: A Robotic or LESS Approach. *JSLs* **2015**, *19*, e2014.00246. [[CrossRef](#)]
43. Lai, E.C.H.; Tang, C.N. Robotic Distal Pancreatectomy versus Conventional Laparoscopic Distal Pancreatectomy: A Comparative Study for Short-Term Outcomes. *Front. Med.* **2015**, *9*, 356–360. [[CrossRef](#)] [[PubMed](#)]

44. Zhou, N.; Chen, J.; Liu, Q.; Zhang, X.; Wang, Z.; Ren, S.; Chen, X. Outcomes of Pancreatoduodenectomy with Robotic Surgery versus Open Surgery. *Int. J. Med. Robot.* **2011**, *7*, 131–137. [[CrossRef](#)]
45. Rosemurgy, A.; Ross, S.; Bourdeau, T.; Craigg, D.; Spence, J.; Alvioli, J.; Sucandy, I. Robotic Pancreaticoduodenectomy Is the Future: Here and Now. *J. Am. Coll. Surg.* **2019**, *228*, 613–624. [[CrossRef](#)]
46. Boone, B.A.; Zenati, M.; Hogg, M.E.; Steve, J.; Moser, A.J.; Bartlett, D.L.; Zeh, H.J.; Zureikat, A.H. Assessment of Quality Outcomes for Robotic Pancreaticoduodenectomy: Identification of the Learning Curve. *JAMA Surg.* **2015**, *150*, 416–422. [[CrossRef](#)]
47. Hackert, T.; Hinz, U.; Fritz, S.; Strobel, O.; Schneider, L.; Hartwig, W.; Büchler, M.W.; Werner, J. Enucleation in Pancreatic Surgery: Indications, Technique, and Outcome Compared to Standard Pancreatic Resections. *Langenbecks Arch. Surg.* **2011**, *396*, 1197. [[CrossRef](#)]
48. Marchese, U.; Tzedakis, S.; Abou Ali, E.; Turrini, O.; Delpero, J.-R.; Coriat, R.; Fuks, D. Parenchymal Sparing Resection: Options in Duodenal and Pancreatic Surgery. *J. Clin. Med.* **2021**, *10*, 1479. [[CrossRef](#)] [[PubMed](#)]
49. Santucci, N.; Gaujoux, S.; Binquet, C.; Reichling, C.; Lifante, J.-C.; Carnaille, B.; Pattou, F.; Mirallié, E.; Facy, O.; Mathonnet, M.; et al. Pancreatoduodenectomy for Neuroendocrine Tumors in Patients with Multiple Endocrine Neoplasia Type 1: An AFCE (Association Francophone de Chirurgie Endocrinienne) and GTE (Groupe d'étude Des Tumeurs Endocrines) Study. *World J. Surg.* **2021**, *45*, 1794–1802. [[CrossRef](#)]
50. Herrera, M.F.; Åkerström, G.; Angelos, P.; Grant, C.S.; Hoff, A.O.; Pantoja, J.P.; Pérez-Johnston, R.; Sahani, D.V.; Wong, R.J.; Randolph, G. AACE/ACE Disease State Clinical Review: Pancreatic Neuroendocrine Incidentalomas. *Endocr. Pract.* **2015**, *21*, 546–553. [[CrossRef](#)]
51. Yoo, Y.J.; Yang, S.J.; Hwang, H.K.; Kang, C.M.; Kim, H.; Lee, W.J. Overestimated Oncologic Significance of Lymph Node Metastasis in G1 Nonfunctioning Neuroendocrine Tumor in the Left Side of the Pancreas. *Medicine (Baltimore)* **2015**, *94*, e1404. [[CrossRef](#)] [[PubMed](#)]
52. Zhang, R.-C.; Zhou, Y.-C.; Mou, Y.-P.; Huang, C.-J.; Jin, W.-W.; Yan, J.-F.; Wang, Y.-X.; Liao, Y. Laparoscopic versus Open Enucleation for Pancreatic Neoplasms: Clinical Outcomes and Pancreatic Function Analysis. *Surg. Endosc.* **2016**, *30*, 2657–2665. [[CrossRef](#)]
53. Karaliotas, C.; Sgourakis, G. Laparoscopic versus Open Enucleation for Solitary Insulinoma in the Body and Tail of the Pancreas. *J. Gastrointest. Surg.* **2009**, *13*, 1869. [[CrossRef](#)] [[PubMed](#)]
54. Sa Cunha, A.; Beau, C.; Rault, A.; Catargi, B.; Collet, D.; Masson, B. Laparoscopic versus Open Approach for Solitary Insulinoma. *Surg. Endosc.* **2007**, *21*, 103–108. [[CrossRef](#)] [[PubMed](#)]
55. Triponez, F.; Sadowski, S.M.; Pattou, F.; Cardot-Bauters, C.; Mirallié, E.; Le Bras, M.; Sebag, F.; Niccoli, P.; Deguelte, S.; Cadiot, G.; et al. Long-term Follow-up of MEN1 Patients Who Do Not Have Initial Surgery for Small ≤ 2 cm Nonfunctioning Pancreatic Neuroendocrine Tumors, an AFCE and GTE Study: Association Francophone de Chirurgie Endocrinienne & Groupe d'Etude des Tumeurs Endocrines. *Ann. Surg.* **2018**, *268*, 158–164. [[CrossRef](#)]
56. Niederle, B.; Selberherr, A.; Bartsch, D.K.; Brandi, M.L.; Doherty, G.M.; Falconi, M.; Goudet, P.; Halfdanarson, T.R.; Ito, T.; Jensen, R.T.; et al. Multiple Endocrine Neoplasia Type 1 and the Pancreas: Diagnosis and Treatment of Functioning and Non-Functioning Pancreatic and Duodenal Neuroendocrine Neoplasia within the MEN1 Syndrome—An International Consensus Statement. *Neuroendocrinology* **2021**, *111*, 609–630. [[CrossRef](#)] [[PubMed](#)]
57. Van Beek, D.J.; Nell, S.; Verkooijen, H.M.; Borel Rinkes, I.H.M.; Valk, G.D.; (on behalf of the DutchMEN study group); Vriens, M.R.; International MEN1 Insulinoma Study Group. Surgery for Multiple Endocrine Neoplasia Type 1-Related Insulinoma: Long-Term Outcomes in a Large International Cohort. *Br. J. Surg.* **2020**, *107*, 1489–1499. [[CrossRef](#)] [[PubMed](#)]
58. Bartsch, D.K.; Albers, M.; Knoop, R.; Kann, P.H.; Fendrich, V.; Waldmann, J. Enucleation and Limited Pancreatic Resection Provide Long-Term Cure for Insulinoma in Multiple Endocrine Neoplasia Type 1. *Neuroendocrinology* **2013**, *98*, 290–298. [[CrossRef](#)] [[PubMed](#)]
59. Alexakis, N.; Connor, S.; Ghaneh, P.; Lombard, M.; Smart, H.; Evans, J.; Hughes, M.; Garvey, C.; Vora, J.; Vinjamuri, S.; et al. Hereditary pancreatic endocrine tumours. *Pancreatology* **2004**, *4*, 417–433. [[CrossRef](#)]
60. Tirosh, A.; Sadowski, S.M.; Linehan, W.M.; Libutti, S.K.; Patel, D.; Nilubol, N.; Kebebew, E. Association of VHL Genotype With Pancreatic Neuroendocrine Tumor Phenotype in Patients With von Hippel-Lindau Disease. *JAMA Oncol.* **2018**, *4*, 124–126. [[CrossRef](#)]
61. Tamura, K.; Nishimori, I.; Ito, T.; Yamasaki, I.; Igarashi, H.; Shuin, T. Diagnosis and Management of Pancreatic Neuroendocrine Tumor in von Hippel-Lindau Disease. *World J. Gastroenterol.* **2010**, *16*, 4515–4518. [[CrossRef](#)]
62. Kouvaraki, M.A.; Ajani, J.A.; Hoff, P.; Wolff, R.; Evans, D.B.; Lozano, R.; Yao, J.C. Fluorouracil, Doxorubicin, and Streptozocin in the Treatment of Patients with Locally Advanced and Metastatic Pancreatic Endocrine Carcinomas. *J. Clin. Oncol.* **2004**, *22*, 4762–4771. [[CrossRef](#)]
63. Moertel, C.G.; Lefkopoulo, M.; Lipsitz, S.; Hahn, R.G.; Klaassen, D. Streptozocin-Doxorubicin, Streptozocin-Fluorouracil or Chlorozotocin in the Treatment of Advanced Islet-Cell Carcinoma. *N. Engl. J. Med.* **1992**, *326*, 519–523. [[CrossRef](#)]
64. Dilz, L.M.; Denecke, T.; Steffen, I.G.; Prasad, V.; von Weikersthal, L.F.; Pape, U.F.; Wiedenmann, B.; Pavel, M. Streptozocin/5-fluorouracil chemotherapy is associated with durable response in patients with advanced pancreatic neuroendocrine tumours. *Eur. J. Cancer* **2015**, *51*, 1253–1262. [[CrossRef](#)]

65. Antonodimitrakis, P.C.; Sundin, A.; Wassberg, C.; Granberg, D.; Skogseid, B.; Eriksson, B. Streptozocin and 5-Fluorouracil for the Treatment of Pancreatic Neuroendocrine Tumors: Efficacy, Prognostic Factors and Toxicity. *Neuroendocrinology* **2016**, *103*, 345–353. [[CrossRef](#)] [[PubMed](#)]
66. Strosberg, J.R.; Fine, R.L.; Choi, J.; Nasir, A.; Coppola, D.; Chen, D.-T.; Helm, J.; Kvols, L. First-Line Chemotherapy with Capecitabine and Temozolomide in Patients with Metastatic Pancreatic Endocrine Carcinomas. *Cancer* **2011**, *117*, 268–275. [[CrossRef](#)]
67. Kunz, P.L.; Catalano, P.J.; Nimeiri, H.; Fisher, G.A.; Longacre, T.A.; Suarez, C.J.; Yao, J.C.; Kulke, M.H.; Hendifar, A.E.; Shanks, J.C.; et al. A Randomized Study of Temozolomide or Temozolomide and Capecitabine in Patients with Advanced Pancreatic Neuroendocrine Tumors: A Trial of the ECOG-ACRIN Cancer Research Group (E2211). *JCO* **2018**, *36*, 4004. [[CrossRef](#)]
68. De Mestier, L.; Walter, T.; Brixi, H.; Evrard, C.; Legoux, J.L.; De Boissieu, P.; Hentic, O.; Cros, J.; Hammel, P.; Tougeron, D.; et al. Comparison of Temozolomide-Capecitabine to 5-Fluorouracil-Dacarbazine in 247 Patients with Advanced Digestive Neuroendocrine Tumors Using Propensity Score Analyses. *Neuroendocrinology* **2019**, *108*, 343–353. [[CrossRef](#)]
69. Bajetta, E.; Rimassa, L.; Carnaghi, C.; Seregni, E.; Ferrari, L.; Di Bartolomeo, M.; Regalia, E.; Cassata, A.; Procopio, G.; Mariani, L. 5-Fluorouracil, Dacarbazine, and Epirubicin in the Treatment of Patients with Neuroendocrine Tumors. *Cancer* **1998**, *83*, 372–378. [[CrossRef](#)]
70. Dussol, A.S.; Joly, M.O.; Vercherat, C.; Forestier, J.; Hervieu, V.; Scoazec, J.; Lombard-Bohas, C.; Walter, T. Gemcitabine and oxaliplatin or alkylating agents for neuroendocrine tumors: Comparison of efficacy and search for predictive factors guiding treatment choice. *Cancer* **2015**, *121*, 3428–3434. [[CrossRef](#)]
71. Cassier, P.A.; Walter, T.; Eymard, B.; Ardisson, P.; Perol, M.; Paillet, C.; Chayvialle, J.-A.; Scoazec, J.-Y.; Hervieu, V.; Bohas, C.L. Gemcitabine and Oxaliplatin Combination Chemotherapy for Metastatic Well-Differentiated Neuroendocrine Carcinomas: A Single-Center Experience. *Cancer* **2009**, *115*, 3392–3399. [[CrossRef](#)] [[PubMed](#)]
72. Caplin, M.E.; Pavel, M.; Ćwikła, J.B.; Phan, A.T.; Raderer, M.; Sedláčková, E.; Cadiot, G.; Wolin, E.M.; Capdevila, J.; Wall, L.; et al. Lanreotide in Metastatic Enteropancreatic Neuroendocrine Tumors. *N. Engl. J. Med.* **2014**, *371*, 224–233. [[CrossRef](#)]
73. Yao, J.C. Neuroendocrine Tumors. Molecular Targeted Therapy for Carcinoid and Islet-Cell Carcinoma. *Best Pract. Res. Clin. Endocrinol. Metab.* **2007**, *21*, 163–172. [[CrossRef](#)]
74. Plöckinger, U.; Wiedenmann, B. Treatment of gastroenteropancreatic neuroendocrine tumors. *Virchows Arch.* **2007**, *451* (Suppl. 1), S71–S80. [[CrossRef](#)]
75. Terris, B.; Scoazec, J.Y.; Rubbia, L.; Bregeaud, L.; Pepper, M.S.; Ruszniewski, P.; Belghiti, J.; Fléjou, J.; Degott, C. Expression of Vascular Endothelial Growth Factor in Digestive Neuroendocrine Tumours. *Histopathology* **1998**, *32*, 133–138. [[CrossRef](#)] [[PubMed](#)]
76. Zhang, J.; Jia, Z.; Li, Q.; Wang, L.; Rashid, A.; Zhu, Z.; Evans, D.B.; Vauthey, J.-N.; Xie, K.; Yao, J.C. Elevated Expression of Vascular Endothelial Growth Factor Correlates with Increased Angiogenesis and Decreased Progression-Free Survival among Patients with Low-Grade Neuroendocrine Tumors. *Cancer* **2007**, *109*, 1478–1486. [[CrossRef](#)] [[PubMed](#)]
77. Fjällskog, M.-L.H.; Lejonklou, M.H.; Oberg, K.E.; Eriksson, B.K.; Janson, E.T. Expression of Molecular Targets for Tyrosine Kinase Receptor Antagonists in Malignant Endocrine Pancreatic Tumors. *Clin. Cancer Res.* **2003**, *9*, 1469–1473.
78. Mena, A.C.; Pulido, E.G.; Guillén-Ponce, C. Understanding the Molecular-Based Mechanism of Action of the Tyrosine Kinase Inhibitor: Sunitinib. *Anticancer Drugs* **2010**, *21* (Suppl. 1), S3–S11. [[CrossRef](#)]
79. Raymond, E.; Dahan, L.; Raoul, J.-L.; Bang, Y.-J.; Borbath, I.; Lombard-Bohas, C.; Valle, J.; Metrakos, P.; Smith, D.; Vinik, A.; et al. Sunitinib Malate for the Treatment of Pancreatic Neuroendocrine Tumors. *N. Engl. J. Med.* **2011**, *364*, 501–513. [[CrossRef](#)]
80. Hobday, T.J.; Rubin, J.; Holen, K.; Picus, J.; Donehower, R.; Marschke, R.; Maples, W.; Lloyd, R.; Mahoney, M.; Erlichman, C. MC044h, a Phase II Trial of Sorafenib in Patients (Pts) with Metastatic Neuroendocrine Tumors (NET): A Phase II Consortium (P2C) Study. *JCO* **2007**, *25*, 4504. [[CrossRef](#)]
81. Phan, A.T.; Halperin, D.M.; Chan, J.A.; Fogelman, D.R.; Hess, K.R.; Malinowski, P.; Regan, E.; Ng, C.S.; Yao, J.C.; Kulke, M.H. Pazopanib and Depot Octreotide in Advanced, Well-Differentiated Neuroendocrine Tumours: A Multicentre, Single-Group, Phase 2 Study. *Lancet Oncol.* **2015**, *16*, 695–703. [[CrossRef](#)]
82. Chan, J.A.; Stuart, K.; Earle, C.C.; Clark, J.W.; Bhargava, P.; Miksad, R.; Blaszkowsky, L.; Enzinger, P.C.; Meyerhardt, J.A.; Zheng, H.; et al. Prospective study of bevacizumab plus temozolomide in patients with advanced neuroendocrine tumors. *J. Clin. Oncol.* **2012**, *30*, 2963–2968. [[CrossRef](#)] [[PubMed](#)]
83. Ducreux, M.; Dahan, L.; Smith, D.; O’Toole, D.; Lepère, C.; Dromain, C.; Vilgrain, V.; Baudin, E.; Lombard-Bohas, C.; Scoazec, J.-Y.; et al. Bevacizumab Combined with 5-FU/Streptozocin in Patients with Progressive Metastatic Well-Differentiated Pancreatic Endocrine Tumours (BETTER Trial)—a Phase II Non-Randomised Trial. *Eur. J. Cancer* **2014**, *50*, 3098–3106. [[CrossRef](#)]
84. Capdevila, J.; Fazio, N.; Lopez, C.; Teulé, A.; Valle, J.W.; Tafuto, S.; Custodio, A.; Reed, N.; Raderer, M.; Grande, E.; et al. Lenvatinib in Patients With Advanced Grade 1/2 Pancreatic and Gastrointestinal Neuroendocrine Tumors: Results of the Phase II TALENT Trial (GETNE1509). *J. Clin. Oncol.* **2021**, *39*, 2304–2312. [[CrossRef](#)] [[PubMed](#)]
85. Yao, J.C.; Phan, A.T.; Chang, D.Z.; Wolff, R.A.; Hess, K.; Gupta, S.; Jacobs, C.; Mares, J.E.; Landgraf, A.N.; Rashid, A.; et al. Efficacy of RAD001 (Everolimus) and Octreotide LAR in Advanced Low- to Intermediate-Grade Neuroendocrine Tumors: Results of a Phase II Study. *J. Clin. Oncol.* **2008**, *26*, 4311–4318. [[CrossRef](#)]

86. Yao, J.C.; Lombard-Bohas, C.; Baudin, E.; Kvols, L.K.; Rougier, P.; Ruzsniwski, P.; Hoosen, S.; St Peter, J.; Haas, T.; Lebwahl, D.; et al. Daily Oral Everolimus Activity in Patients with Metastatic Pancreatic Neuroendocrine Tumors after Failure of Cytotoxic Chemotherapy: A Phase II Trial. *J. Clin. Oncol.* **2010**, *28*, 69–76. [[CrossRef](#)]
87. Yao, J.C.; Shah, M.H.; Ito, T.; Bohas, C.L.; Wolin, E.M.; Van Cutsem, E.; Hobday, T.J.; Okusaka, T.; Capdevila, J.; de Vries, E.G.E.; et al. Everolimus for Advanced Pancreatic Neuroendocrine Tumors. *N. Engl. J. Med.* **2011**, *364*, 514–523. [[CrossRef](#)]
88. Strosberg, J.; El-Haddad, G.; Wolin, E.; Hendifar, A.; Yao, J.; Chasen, B.; Mittra, E.; Kunz, P.L.; Kulke, M.H.; Jacene, H.; et al. Phase 3 Trial of ¹⁷⁷Lu-Dotatate for Midgut Neuroendocrine Tumors. *N. Engl. J. Med.* **2017**, *376*, 125–135. [[CrossRef](#)]
89. Brabander, T.; van der Zwan, W.A.; Teunissen, J.J.M.; Kam, B.L.R.; Feelders, R.A.; de Herder, W.W.; van Eijck, C.H.J.; Franssen, G.J.H.; Krenning, E.P.; Kwekkeboom, D.J. Long-Term Efficacy, Survival, and Safety of [177Lu-DOTA0,Tyr3]Octreotate in Patients with Gastroenteropancreatic and Bronchial Neuroendocrine Tumors. *Clin. Cancer Res.* **2017**, *23*, 4617–4624. [[CrossRef](#)]
90. Chan, D.L.; Thompson, R.; Lam, M.; Pavlakis, N.; Hallet, J.; Law, C.; Singh, S.; Myrehaug, S. External Beam Radiotherapy in the Treatment of Gastroenteropancreatic Neuroendocrine Tumours: A Systematic Review. *Clin. Oncol. (R Coll Radiol.)* **2018**, *30*, 400–408. [[CrossRef](#)] [[PubMed](#)]
91. Iwata, T.; Ueno, H.; Itami, J.; Ito, Y.; Inaba, K.; Morizane, C.; Kondo, S.; Sakamoto, Y.; Shiba, S.; Sasaki, M.; et al. Efficacy of radiotherapy for primary tumor in patients with unresectable pancreatic neuroendocrine tumors. *JPN J. Clin. Oncol.* **2017**, *47*, 826–831. [[CrossRef](#)] [[PubMed](#)]
92. Sandhu, N.; Benson, K.R.K.; Kumar, K.A.; Eyben, R.V.; Chang, D.T.; Gibbs, I.C.; Hancock, S.L.; Meola, A.; Chang, S.D.; Li, G.; et al. Local control and toxicity outcomes of stereotactic radiosurgery for spinal metastases of gastrointestinal origin. *J. Neurosurgery Spine* **2020**, *33*, 87–94. [[CrossRef](#)] [[PubMed](#)]
93. Kamieniarz, L.; Armeni, E.; O'Mahony, L.F.; Leigh, C.; Miah, L.; Narayan, A.; Bhatt, A.; Cox, N.; Mandair, D.; Navalkisoor, S.; et al. Orbital metastases from neuroendocrine neoplasms: Clinical implications and outcomes. *Endocrine* **2020**, *67*, 485–493. [[CrossRef](#)] [[PubMed](#)]
94. Norton, J.A.; Warren, R.S.; Kelly, M.G.; Zuraek, M.B.; Jensen, R.T. Aggressive Surgery for Metastatic Liver Neuroendocrine Tumors. *Surgery* **2003**, *134*, 1057–1063; discussion 1063–1065. [[CrossRef](#)]
95. Elias, D.; Lasser, P.; Ducreux, M.; Duvillard, P.; Ouellet, J.-F.; Dromain, C.; Schlumberger, M.; Pocard, M.; Boige, V.; Miquel, C.; et al. Liver Resection (and Associated Extrahepatic Resections) for Metastatic Well-Differentiated Endocrine Tumors: A 15-Year Single Center Prospective Study. *Surgery* **2003**, *133*, 375–382. [[CrossRef](#)]
96. Watzka, F.M.; Fottner, C.; Miederer, M.; Schad, A.; Weber, M.M.; Otto, G.; Lang, H.; Musholt, T.J. Surgical Therapy of Neuroendocrine Neoplasm with Hepatic Metastasis: Patient Selection and Prognosis. *Langenbecks Arch. Surg.* **2015**, *400*, 349–358. [[CrossRef](#)]
97. Mayo, S.C.; de Jong, M.C.; Pulitano, C.; Clary, B.M.; Reddy, S.K.; Gamblin, T.C.; Celinski, S.A.; Kooby, D.A.; Staley, C.A.; Stokes, J.B.; et al. Surgical Management of Hepatic Neuroendocrine Tumor Metastasis: Results from an International Multi-Institutional Analysis. *Ann. Surg. Oncol.* **2010**, *17*, 3129–3136. [[CrossRef](#)]
98. Maxwell, J.E.; Sherman, S.K.; O'Dorisio, T.M.; Bellizzi, A.M.; Howe, J.R. Liver-Directed Surgery of Neuroendocrine Metastases: What Is the Optimal Strategy? *Surgery* **2016**, *159*, 320–333. [[CrossRef](#)]
99. Gaujoux, S.; Gonen, M.; Tang, L.; Klimstra, D.; Brennan, M.F.; D'Angelica, M.; Dematteo, R.; Allen, P.J.; Jarnagin, W.; Fong, Y. Synchronous Resection of Primary and Liver Metastases for Neuroendocrine Tumors. *Ann. Surg. Oncol.* **2012**, *19*, 4270–4277. [[CrossRef](#)] [[PubMed](#)]
100. Zerbi, A.; Capitanio, V.; Boninsegna, L.; Delle Fave, G.; Pasquali, C.; Rindi, G.; Campana, D.; Falconi, M.; AISP-Network Study Group. Treatment of Malignant Pancreatic Neuroendocrine Neoplasms: Middle-Term (2-Year) Outcomes of a Prospective Observational Multicentre Study. *HPB (Oxford)* **2013**, *15*, 935–943. [[CrossRef](#)]
101. Elias, D.; Lefevre, J.H.; Duvillard, P.; Goéré, D.; Dromain, C.; Dumont, F.; Baudin, E. Hepatic Metastases from Neuroendocrine Tumors with a “Thin Slice” Pathological Examination: They Are Many More than You Think. *Ann. Surg.* **2010**, *251*, 307–310. [[CrossRef](#)] [[PubMed](#)]
102. Norlén, O.; Stålberg, P.; Zedenius, J.; Hellman, P. Outcome after Resection and Radiofrequency Ablation of Liver Metastases from Small Intestinal Neuroendocrine Tumours. *Br. J. Surg.* **2013**, *100*, 1505–1514. [[CrossRef](#)]
103. Osborne, D.A.; Zervos, E.E.; Strosberg, J.; Strosberg, J.; Boe, B.A.; Malafa, M.; Rosemurgy, A.S.; Yeatman, T.J.; Carey, L.; Duhaine, L.; et al. Improved Outcome with Cytoreduction versus Embolization for Symptomatic Hepatic Metastases of Carcinoid and Neuroendocrine Tumors. *Ann. Surg. Oncol.* **2006**, *13*, 572–581. [[CrossRef](#)] [[PubMed](#)]
104. Cusati, D.; Zhang, L.; Harmsen, W.S.; Hu, A.; Farnell, M.B.; Nagorney, D.M.; Donohue, J.H.; Que, F.G.; Reid-Lombardo, K.M.; Kendrick, M.L. Metastatic Nonfunctioning Pancreatic Neuroendocrine Carcinoma to Liver: Surgical Treatment and Outcomes. *J. Am. Coll. Surg.* **2012**, *215*, 117–124; discussion 124–125. [[CrossRef](#)] [[PubMed](#)]
105. Steinmüller, T.; Kianmanesh, R.; Falconi, M.; Scarpa, A.; Taal, B.; Kwekkeboom, D.J.; Lopes, J.M.; Perren, A.; Nikou, G.; Yao, J.; et al. Consensus Guidelines for the Management of Patients with Liver Metastases from Digestive (Neuro)Endocrine Tumors: Foregut, Midgut, Hindgut, and Unknown Primary. *Neuroendocrinology* **2008**, *87*, 47–62. [[CrossRef](#)] [[PubMed](#)]
106. Kandil, E.; Noureldine, S.I.; Koffron, A.; Yao, L.; Saggi, B.; Buell, J.F. Outcomes of Laparoscopic and Open Resection for Neuroendocrine Liver Metastases. *Surgery* **2012**, *152*, 1225–1231. [[CrossRef](#)]
107. Kimura, W.; Tezuka, K.; Hirai, I. Surgical Management of Pancreatic Neuroendocrine Tumors. *Surg. Today* **2011**, *41*, 1332–1343. [[CrossRef](#)]

108. Hanazaki, K.; Sakurai, A.; Munekage, M.; Ichikawa, K.; Namikawa, T.; Okabayashi, T.; Imamura, M. Surgery for a Gastroenteropancreatic Neuroendocrine Tumor (GEPNET) in Multiple Endocrine Neoplasia Type 1. *Surg. Today* **2013**, *43*, 229–236. [[CrossRef](#)]
109. Pavel, M.; O'Toole, D.; Costa, F.; Capdevila, J.; Gross, D.; Kianmanesh, R.; Krenning, E.; Knigge, U.; Salazar, R.; Pape, U.-F.; et al. ENETS Consensus Guidelines Update for the Management of Distant Metastatic Disease of Intestinal, Pancreatic, Bronchial Neuroendocrine Neoplasms (NEN) and NEN of Unknown Primary Site. *Neuroendocrinology* **2016**, *103*, 172–185. [[CrossRef](#)]
110. Mayo, S.C.; de Jong, M.C.; Bloomston, M.; Pulitano, C.; Clary, B.M.; Reddy, S.K.; Clark Gamblin, T.; Celinski, S.A.; Kooby, D.A.; Staley, C.A.; et al. Surgery versus Intra-Arterial Therapy for Neuroendocrine Liver Metastasis: A Multicenter International Analysis. *Ann. Surg. Oncol.* **2011**, *18*, 3657–3665. [[CrossRef](#)]
111. Bettini, R.; Mantovani, W.; Boninsegna, L.; Crippa, S.; Capelli, P.; Bassi, C.; Scarpa, A.; Pederzoli, P.; Falconi, M. Primary Tumour Resection in Metastatic Nonfunctioning Pancreatic Endocrine Carcinomas. *Dig. Liver Dis.* **2009**, *41*, 49–55. [[CrossRef](#)]
112. Scigliano, S.; Lebtahi, R.; Maire, F.; Stievenart, J.L.; Kianmanesh, R.; Sauvanet, A.; Vullierme, M.P.; Couvelard, A.; Belghiti, J.; Ruszniewski, P.; et al. Clinical and Imaging Follow-up after Exhaustive Liver Resection of Endocrine Metastases: A 15-Year Monocentric Experience. *Endocr. Relat. Cancer* **2009**, *16*, 977–990. [[CrossRef](#)] [[PubMed](#)]
113. Eriksson, B.; Klöppel, G.; Krenning, E.; Ahlman, H.; Plöckinger, U.; Wiedenmann, B.; Arnold, R.; Auernhammer, C.; Körner, M.; Rindi, G.; et al. Consensus Guidelines for the Management of Patients with Digestive Neuroendocrine Tumors—Well-Differentiated Jejunal-Ileal Tumor/Carcinoma. *Neuroendocrinology* **2008**, *87*, 8–19. [[CrossRef](#)]
114. Falconi, M.; Bartsch, D.K.; Eriksson, B.; Klöppel, G.; Lopes, J.M.; O'Connor, J.M.; Salazar, R.; Taal, B.G.; Vullierme, M.P.; O'Toole, D.; et al. ENETS Consensus Guidelines for the Management of Patients with Digestive Neuroendocrine Neoplasms of the Digestive System: Well-Differentiated Pancreatic Non-Functioning Tumors. *Neuroendocrinology* **2012**, *95*, 120–134. [[CrossRef](#)]
115. Capurso, G.; Rinzivillo, M.; Bettini, R.; Boninsegna, L.; Delle Fave, G.; Falconi, M. Systematic Review of Resection of Primary Midgut Carcinoid Tumour in Patients with Unresectable Liver Metastases. *Br. J. Surg.* **2012**, *99*, 1480–1486. [[CrossRef](#)] [[PubMed](#)]
116. Capurso, G.; Bettini, R.; Rinzivillo, M.; Boninsegna, L.; Delle Fave, G.; Falconi, M. Role of Resection of the Primary Pancreatic Neuroendocrine Tumour Only in Patients with Unresectable Metastatic Liver Disease: A Systematic Review. *Neuroendocrinology* **2011**, *93*, 223–229. [[CrossRef](#)]
117. Nguyen, S.Q.; Angel, L.P.; Divino, C.M.; Schluender, S.; Warner, R.R.P. Surgery in Malignant Pancreatic Neuroendocrine Tumors. *J. Surg. Oncol.* **2007**, *96*, 397–403. [[CrossRef](#)] [[PubMed](#)]
118. Solorzano, C.C.; Lee, J.E.; Pisters, P.W.; Vauthey, J.N.; Ayers, G.D.; Jean, M.E.; Gagel, R.F.; Ajani, J.A.; Wolff, R.A.; Evans, D.B. Nonfunctioning Islet Cell Carcinoma of the Pancreas: Survival Results in a Contemporary Series of 163 Patients. *Surgery* **2001**, *130*, 1078–1085. [[CrossRef](#)] [[PubMed](#)]
119. Grazi, G.L.; Cescon, M.; Pierangeli, F.; Ercolani, G.; Gardini, A.; Cavallari, A.; Mazziotti, A. Highly Aggressive Policy of Hepatic Resections for Neuroendocrine Liver Metastases. *Hepatogastroenterology* **2000**, *47*, 481–486. [[PubMed](#)]
120. Pascher, A.; Steinmüller, T.; Radke, C.; Hosten, N.; Wiedenmann, B.; Neuhaus, P.; Bechstein, W.O. Primary and Secondary Hepatic Manifestation of Neuroendocrine Tumors. *Langenbecks Arch. Surg.* **2000**, *385*, 265–270. [[CrossRef](#)]
121. Nave, H.; Mössinger, E.; Feist, H.; Lang, H.; Raab, H. Surgery as Primary Treatment in Patients with Liver Metastases from Carcinoid Tumors: A Retrospective, Unicentric Study over 13 Years. *Surgery* **2001**, *129*, 170–175. [[CrossRef](#)]
122. Jaeck, D.; Oussoultzoglou, E.; Bachellier, P.; Lemarque, P.; Weber, J.C.; Nakano, H.; Wolf, P. Hepatic Metastases of Gastroenteropancreatic Neuroendocrine Tumors: Safe Hepatic Surgery. *World J. Surg.* **2001**, *25*, 689–692. [[CrossRef](#)]
123. Yao, K.A.; Talamonti, M.S.; Nemcek, A.; Angelos, P.; Chrisman, H.; Skarda, J.; Benson, A.B.; Rao, S.; Joehl, R.J. Indications and Results of Liver Resection and Hepatic Chemoembolization for Metastatic Gastrointestinal Neuroendocrine Tumors. *Surgery* **2001**, *130*, 677–682; discussion 682–685. [[CrossRef](#)] [[PubMed](#)]
124. Norton, J.A.; Kivlen, M.; Li, M.; Schneider, D.; Chuter, T.; Jensen, R.T. Morbidity and Mortality of Aggressive Resection in Patients with Advanced Neuroendocrine Tumors. *Arch. Surg.* **2003**, *138*, 859–866. [[CrossRef](#)]
125. Touzios, J.G.; Kiely, J.M.; Pitt, S.C.; Rilling, W.S.; Quebbeman, E.J.; Wilson, S.D.; Pitt, H.A. Neuroendocrine Hepatic Metastases: Does Aggressive Management Improve Survival? *Ann. Surg.* **2005**, *241*, 776–783; discussion 783–785. [[CrossRef](#)]
126. Musunuru, S.; Chen, H.; Rajpal, S.; Stephani, N.; McDermott, J.C.; Holen, K.; Rikkers, L.F.; Weber, S.M. Metastatic Neuroendocrine Hepatic Tumors: Resection Improves Survival. *Arch. Surg.* **2006**, *141*, 1000–1004; discussion 1005. [[CrossRef](#)]
127. Mazzaferro, V.; Pulvirenti, A.; Coppa, J. Neuroendocrine Tumors Metastatic to the Liver: How to Select Patients for Liver Transplantation? *J. Hepatol.* **2007**, *47*, 460–466. [[CrossRef](#)]
128. Gomez, D.; Malik, H.Z.; Al-Mukthar, A.; Menon, K.V.; Toogood, G.J.; Lodge, J.P.A.; Prasad, K.R. Hepatic Resection for Metastatic Gastrointestinal and Pancreatic Neuroendocrine Tumours: Outcome and Prognostic Predictors. *HPB (Oxford)* **2007**, *9*, 345–351. [[CrossRef](#)]
129. Zappa, M.; Abdel-Rehim, M.; Hentic, O.; Vullierme, M.-P.; Ruszniewski, P.; Vilgrain, V. Liver-Directed Therapies in Liver Metastases from Neuroendocrine Tumors of the Gastrointestinal Tract. *Target. Oncol.* **2012**, *7*, 107–116. [[CrossRef](#)] [[PubMed](#)]
130. De Baere, T.; Deschamps, F.; Tselikas, L.; Ducreux, M.; Planchard, D.; Pearson, E.; Berdelou, A.; Leboulleux, S.; Elias, D.; Baudin, E. GEP-NETS Update: Interventional Radiology: Role in the Treatment of Liver Metastases from GEP-NETS. *Eur. J. Endocrinol.* **2015**, *172*, R151–R166. [[CrossRef](#)] [[PubMed](#)]
131. Glazer, E.S.; Tseng, J.F.; Al-Refaie, W.; Solorzano, C.C.; Liu, P.; Willborn, K.A.; Abdalla, E.K.; Vauthey, J.-N.; Curley, S.A. Long-Term Survival after Surgical Management of Neuroendocrine Hepatic Metastases. *HPB (Oxford)* **2010**, *12*, 427–433. [[CrossRef](#)]

132. Frilling, A.; Clift, A.K. Therapeutic Strategies for Neuroendocrine Liver Metastases. *Cancer* **2015**, *121*, 1172–1186. [[CrossRef](#)] [[PubMed](#)]
133. Kandil, E.; Saeed, A.; Buell, J. Surgical Approaches for Liver Metastases in Carcinoid Tumors. *Gland. Surg.* **2015**, *4*, 442–446. [[CrossRef](#)]
134. Fairweather, M.; Swanson, R.; Wang, J.; Brais, L.K.; Dutton, T.; Kulke, M.H.; Clancy, T.E. Management of Neuroendocrine Tumor Liver Metastases: Long-Term Outcomes and Prognostic Factors from a Large Prospective Database. *Ann. Surg. Oncol.* **2017**, *24*, 2319–2325. [[CrossRef](#)]
135. Spolverato, G.; Bagante, F.; Aldrighetti, L.; Poultsides, G.A.; Bauer, T.W.; Fields, R.C.; Maithel, S.K.; Marques, H.P.; Weiss, M.; Pawlik, T.M. Management and Outcomes of Patients with Recurrent Neuroendocrine Liver Metastasis after Curative Surgery: An International Multi-Institutional Analysis. *J. Surg. Oncol.* **2017**, *116*, 298–306. [[CrossRef](#)]
136. Abu Hilal, M.; Di Fabio, F.; Abu Salameh, M.; Pearce, N.W. Oncological Efficiency Analysis of Laparoscopic Liver Resection for Primary and Metastatic Cancer: A Single-Center UK Experience. *Arch. Surg.* **2012**, *147*, 42–48. [[CrossRef](#)]
137. Cipriani, F.; Rawashdeh, M.; Stanton, L.; Armstrong, T.; Takhar, A.; Pearce, N.W.; Primrose, J.; Abu Hilal, M. Propensity Score-Based Analysis of Outcomes of Laparoscopic versus Open Liver Resection for Colorectal Metastases. *Br. J. Surg.* **2016**, *103*, 1504–1512. [[CrossRef](#)]
138. Massironi, S.; Conte, D.; Sciola, V.; Pirola, L.; Paggi, S.; Fraquelli, M.; Ciafardini, C.; Spampatti, M.P.; Peracchi, M. Contrast-Enhanced Ultrasonography in Evaluating Hepatic Metastases from Neuroendocrine Tumours. *Dig. Liver Dis.* **2010**, *42*, 635–641. [[CrossRef](#)] [[PubMed](#)]
139. Bonaccorsi-Riani, E.; Apestegui, C.; Jouret-Mourin, A.; Sempoux, C.; Goffette, P.; Ciccarelli, O.; Borbath, I.; Hubert, C.; Gigot, J.F.; Hassoun, Z.; et al. Liver Transplantation and Neuroendocrine Tumors: Lessons from a Single Centre Experience and from the Literature Review. *Transpl. Int.* **2010**, *23*, 668–678. [[CrossRef](#)]
140. Soyer, P.; Roche, A.; Elias, D.; Levesque, M. Hepatic Metastases from Colorectal Cancer: Influence of Hepatic Volumetric Analysis on Surgical Decision Making. *Radiology* **1992**, *184*, 695–697. [[CrossRef](#)]
141. Lehnert, T. Liver Transplantation for Metastatic Neuroendocrine Carcinoma: An Analysis of 103 Patients. *Transplantation* **1998**, *66*, 1307–1312. [[CrossRef](#)] [[PubMed](#)]
142. Le Treut, Y.P.; Delpero, J.R.; Dousset, B.; Cherqui, D.; Segol, P.; Manton, G.; Hannoun, L.; Benhamou, G.; Launois, B.; Boillot, O.; et al. Results of Liver Transplantation in the Treatment of Metastatic Neuroendocrine Tumors. A 31-Case French Multicentric Report. *Ann. Surg.* **1997**, *225*, 355–364. [[CrossRef](#)] [[PubMed](#)]
143. Coppa, J.; Pulvirenti, A.; Schiavo, M.; Romito, R.; Collini, P.; Di Bartolomeo, M.; Fabbri, A.; Regalia, E.; Mazzaferro, V. Resection versus Transplantation for Liver Metastases from Neuroendocrine Tumors. *Transpl. Proc.* **2001**, *33*, 1537–1539. [[CrossRef](#)]
144. Le Treut, Y.P.; Grégoire, E.; Klempnauer, J.; Belghiti, J.; Jouve, E.; Lerut, J.; Castaing, D.; Soubrane, O.; Boillot, O.; Manton, G.; et al. Liver Transplantation for Neuroendocrine Tumors in Europe—Results and Trends in Patient Selection: A 213-Case European Liver Transplant Registry Study. *Ann. Surg.* **2013**, *257*, 807–815. [[CrossRef](#)] [[PubMed](#)]