

Supplementary Figure S1

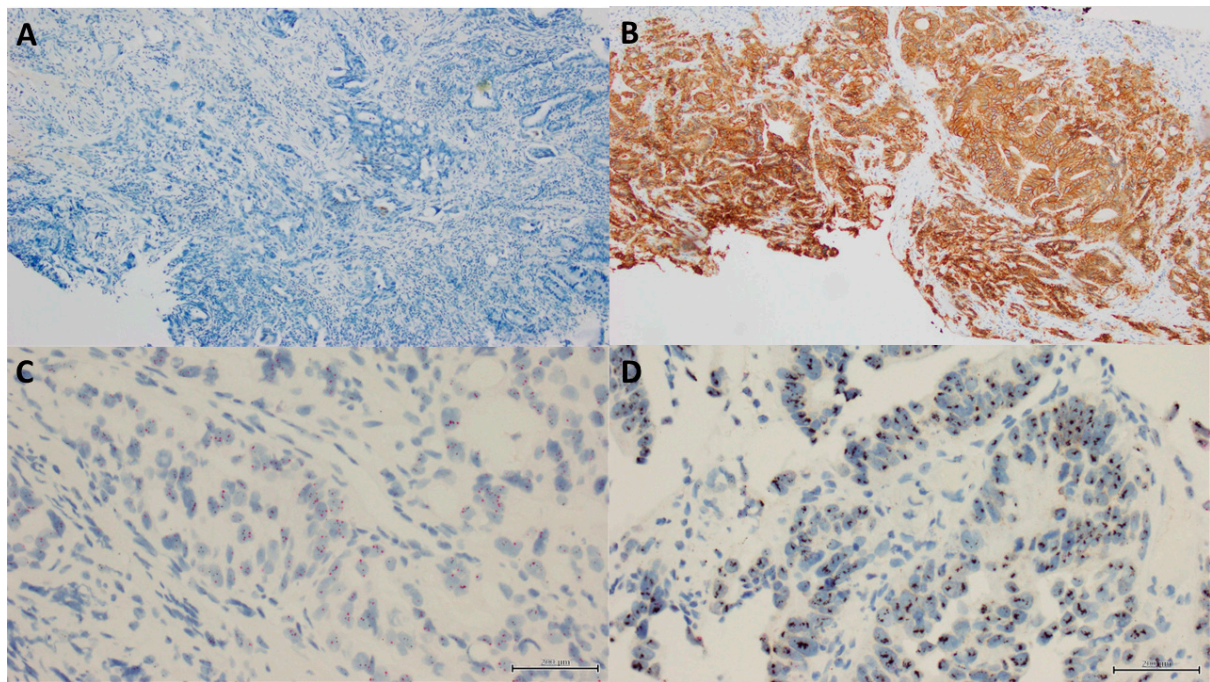


Figure S1. Examples of HER2 immunohistochemistry (IHC) and In Situ Hybridization (ISH) in gastric, gastroesophageal junction and oesophageal adenocarcinoma (at 100× magnification). (A) HER2 IHC negative (score zero). (B) HER2 IHC positive, brown staining (score 3). (C) HER2 ISH negative. (D) HER 2 ISH positive.