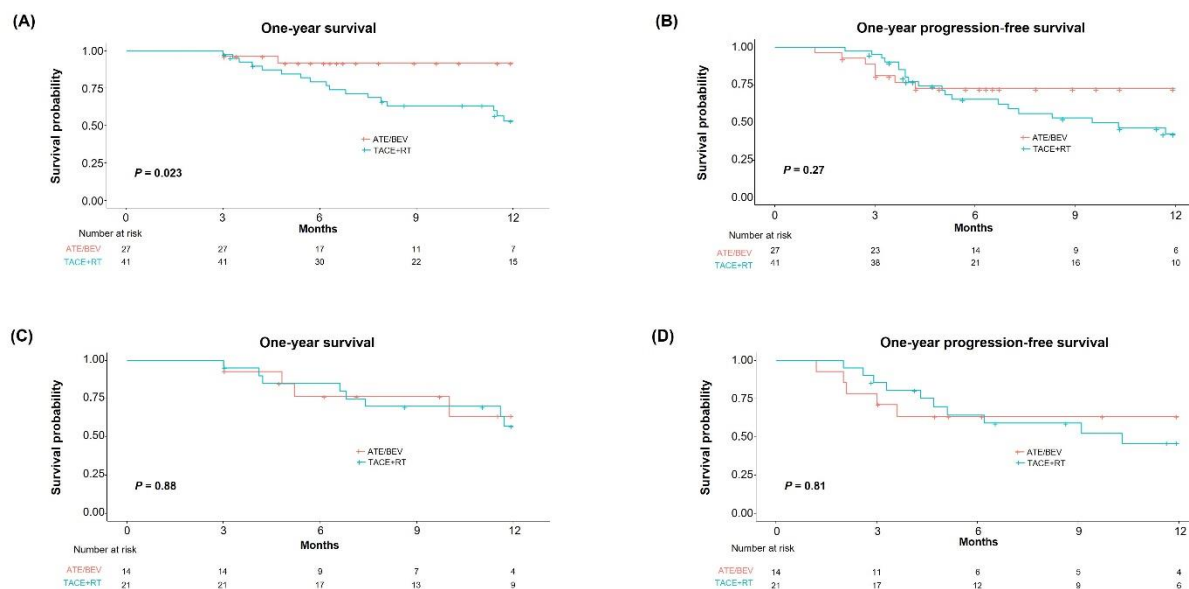


## Supplementary Materials



**Figure S1.** One-year survival and progression-free survival in patients with (A,B) multiple intrahepatic HCC, and (C,D) unilobar intrahepatic HCC without VP4 PVTT. HCC, hepatocellular carcinoma; VP4 PVTT, major portal vein tumor thrombus.