

Supplementary materials

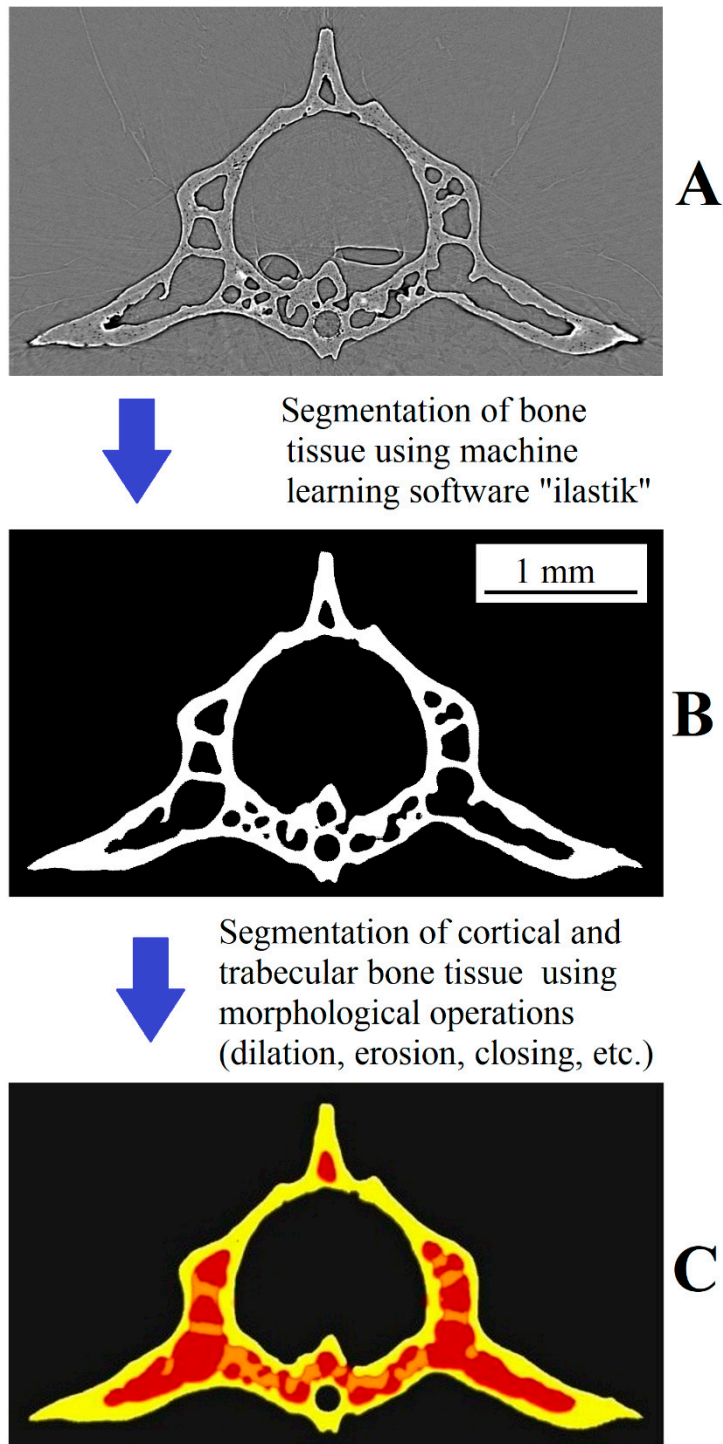


Figure S1. The steps of segmentation of the vertebrae. **A** – XPCT transverse section of the vertebra after reconstruction; **B** – the segmented bone tissue of the vertebra; **C** – the segmented cortical bone (yellow) and the subcortical volume (red) with trabeculae (orange).