

Supplement 1

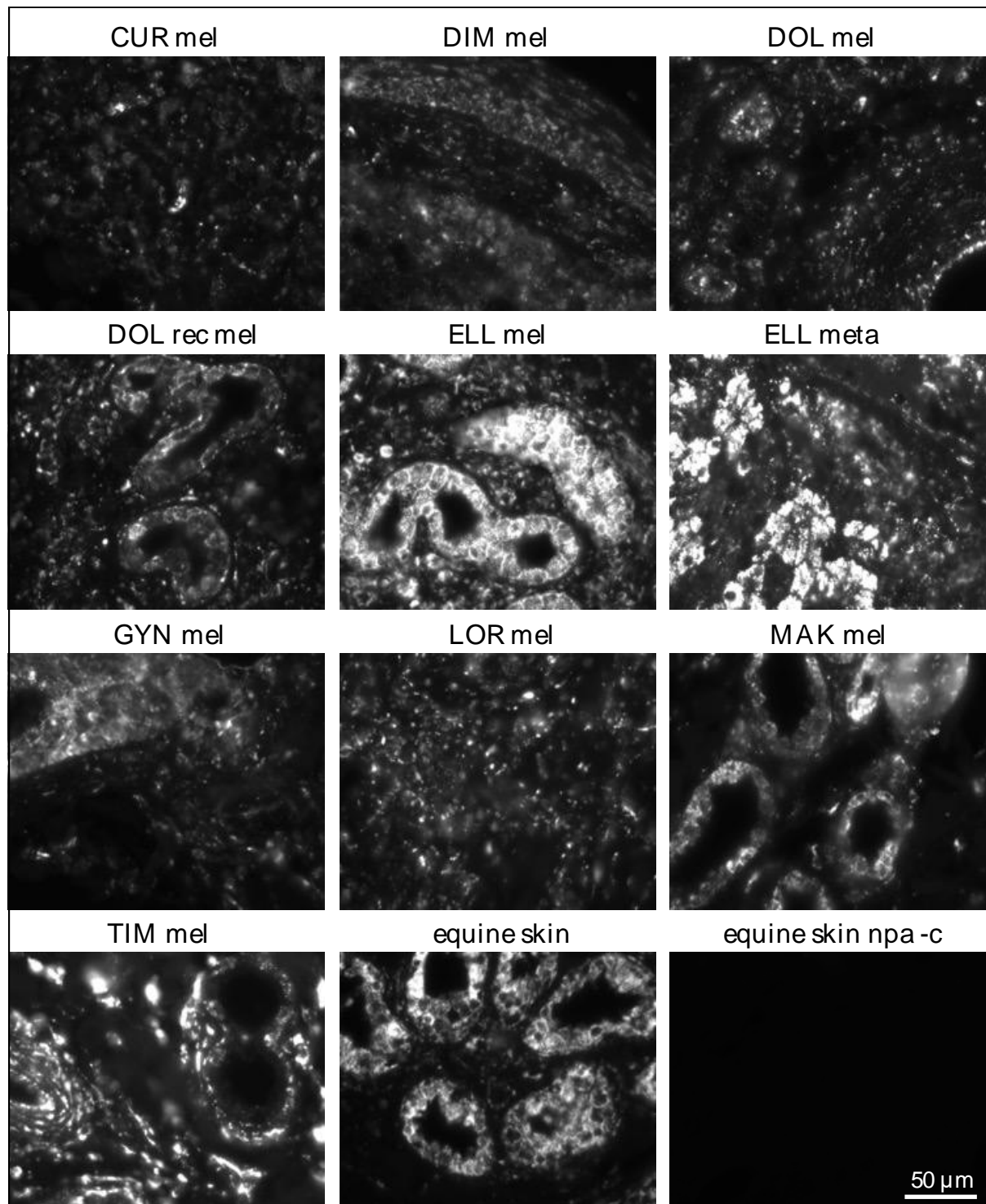


Figure S1: Grey-scale images of MMP1-stained grey-horse melanoma sections
In equine normal skin, MMP1 expression is confined to glandular cells. In the tumor sections, melanoma cells stain likewise positive for MMP1. Images were taken using an Epifluorescence Microscope Zeiss Axio Imager Z2 (Zeiss, Jena, Germany).