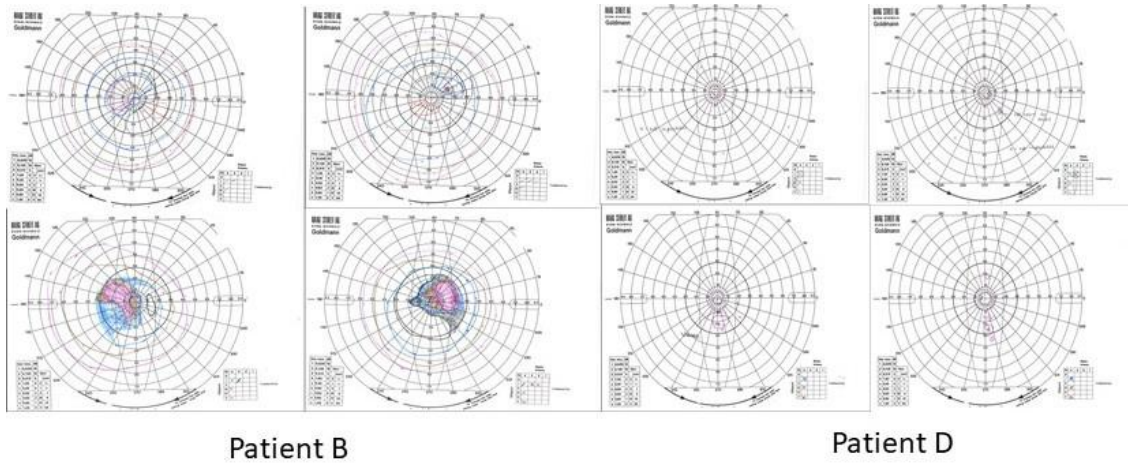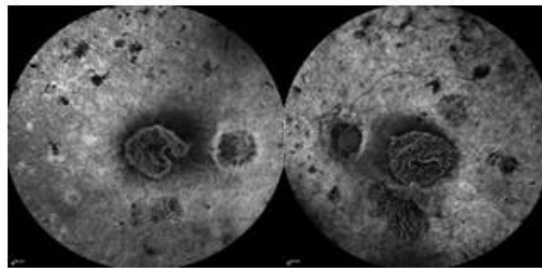


**Figure 1.** Goldmann visual fields showing two timepoints in patients B and D. Patient B the Goldmann visual fields show an increase in the central scotoma bilaterally over a 5 year time period. Patient D has severely constricted visual fields which are similar at a 2 year follow up.



**Figure 2.** Fundus fluorescein angiography demonstrating central and inferior retinal patches of total retinal loss in patient C.

**Table 1.** Variants identified in IRD genes other than *CERKL*.

Patient	Panel used	Gene	Variant	State	Report
C	55	<i>CACNA1F</i>	c.4343C>T	p.(Thr1448Ile)	Het Uncertain
D	55	<i>PDE6A</i>	c.769C>T	p.(Arg257*)	Het Pathogenic
E	111	<i>IMPG2</i>	c.789C>G	p.(Ser263Arg)	Het Uncertain
G	111	<i>USH2A</i>	c.3812-3_3837dup	p.(Met1280*)	Het Pathogenic
		<i>NRL</i>	c.11c>T	p.(Pro4Leu)	Het Uncertain