

Supplementary Materials: Outcome of Full-Thickness Macular Hole Surgery in Choroideremia

Mays Talib, Leonoor S. Koetsier, Robert E. MacLaren and Camiel J.F. Boon

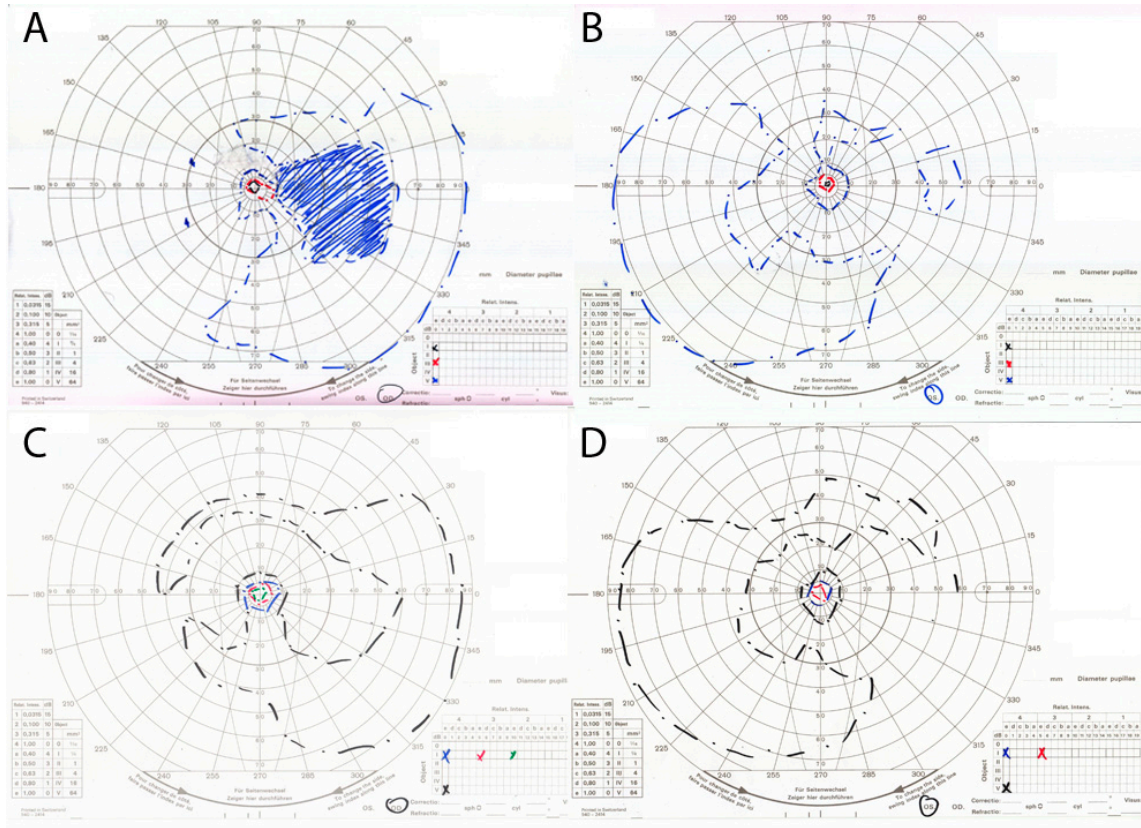


Figure S1. Goldmann visual fields before and after macular hole surgery in a choroideremia patient with a full-thickness macular hole. (A and B) Preoperative Goldmann visual fields of the right (A) and left (B) eye, showing bilateral nasal peripheral visual field constriction with a midperipheral scotoma. (C and D) Postoperative Goldmann visual fields showing no significant changes.