




## Article

# Biochemical and Pathophysiological Responses in *Capoeta capoeta* under Lethal and Sub-Lethal Exposures of Silver Nanoparticles

Dariush Azadikhah<sup>1</sup>, Ahmad Mohamadi Yalsuyi<sup>2</sup> , Shubhajit Saha<sup>3</sup> , Nimai Chandra Saha<sup>3</sup>  
and Caterina Faggio<sup>4,\*</sup> 

<sup>1</sup> Department of Pathobiology, Faculty of Veterinary Medicine, Urmia Branch, Islamic Azad University, Urmia 57561-51818, Iran

<sup>2</sup> Department of Fisheries Sciences, Gorgan University of Agricultural Science and Natural Resources, Gorgan 49138-15739, Iran

<sup>3</sup> Ecotoxicology Research Laboratory, Department of Zoology, University of Burdwan, Burdwan 713104, West Bengal, India

<sup>4</sup> Department of Chemical, Biological, Pharmaceutical and Environmental Sciences, University of Messina, Viale Ferdinando Stagno D'Alcontres 31, 98166 Messina, Italy

\* Correspondence: cfaggio@unime.it

**Abstract:** The increasing use of nano-based products raises concerns regarding potential risks related to their manufacturing, transportation, waste disposal, and management operations. We used the riverine carp, *Capoeta capoeta*, as an aquatic animal model to demonstrate the acute toxicity of silver nanoparticles (Ag-NPs). This study focuses on acute toxicity first, and then integrates the findings through histopathology, hematological, and biochemical testing of lethal and sub-lethal Ag-NPs exposures. Red blood corpuscles (RBC), white blood corpuscles (WBC), hematocrit, and total serum glucose levels were significantly lower in Ag-NPs-exposed fish than in control fish. Total serum protein, triglycerides, cholesterol, and albumin were all significantly greater in exposed fish. This research focused on the impacts of Ag-NPs on gills and liver tissue, and it was found that the level of injury escalated as the concentration of Ag NPs increased. Epithelial lifting of secondary lamellas (ELSL), epithelial hypertrophy (EH) of secondary lamellae (SL), leukocyte infiltration (LI), and bottom hyperplasia (BH) were all detected in Ag-NPs-exposed fish. In Ag-NPs-treated liver cross-sections of *Capoeta capoeta*, macrophage aggregates (MA), fatty liver (FL), sinusoid dilatation (SD), and necrosis (N) were identified. Ag-NPs dosages, according to biomarker representations, elicit stress-specific biochemical and physiological effects, compromising the general overall health status of aquatic animals. The gradients of toxic responses across exposure concentrations and portrayals of disrupted fish health with increasing silver nanoparticle exposure time indicate a reduced physiological ability for surviving in the wild.

**Keywords:** silver nanoparticles (Ag-NPs); *Capoeta capoeta*; acute toxicity test; hematological alterations; biochemical endpoints; histopathological biomarkers



**Citation:** Azadikhah, D.; Yalsuyi, A.M.; Saha, S.; Saha, N.C.; Faggio, C. Biochemical and Pathophysiological Responses in *Capoeta capoeta* under Lethal and Sub-Lethal Exposures of Silver Nanoparticles. *Water* **2023**, *15*, 585. <https://doi.org/10.3390/w15030585>

Academic Editor: Lihui An

Received: 2 December 2022

Revised: 23 January 2023

Accepted: 30 January 2023

Published: 2 February 2023



**Copyright:** © 2023 by the authors. Licensee MDPI, Basel, Switzerland. This article is an open access article distributed under the terms and conditions of the Creative Commons Attribution (CC BY) license (<https://creativecommons.org/licenses/by/4.0/>).

## 1. Introduction

Nanoparticles have been in high demand in the metal industry, biological science, and other fields in recent years [1–5]. Nanoparticles are now utilized in daily household appliances [6]. They are widely manufactured, with an annual production of 60,000 tons [7]. Six-hundred and twenty-two businesses from 30 countries develop 1814 nanoproducts for a variety of uses [8]. Only 435 nanoproducts are based on silver, accounting for 34% of overall output, with 320 tons annually [7,8]. The study of the effects of produced nanoparticles on living beings and the environment is known as nanotoxicology [9–13]. It also covers the quantitative assessment of the severity and frequency of nano-toxic effects in proportion to

organism exposure [14]. Metal nanoparticles have been used in a variety of fields, including consumer products, industrial applications, and health care technology, and are likely to enter the environment [6,12,14–16].

Silver nanoparticles (Ag-NPs) are widely used, which increases the number of pollutants released into aquatic and terrestrial habitats [6,8,17,18]. Cement manufacturing, rock weathering, fossil fuel burning, mineral processing, leaching, and anthropogenic activities all contributed to additional contamination of the environment [19,20]. Textiles frequently contain Ag-NPs, and these nanoparticles may be discharged into the atmosphere [21,22]. The wide range of applications for Ag-NPs necessitates large-scale, cost-effective synthesis. Chemical, physical, and biological methods have all been used to create these particles in recent decades. Chemical reduction is the most acceptable method due to lower chemical costs, simplicity of control, and fewer by-products [23]. Currently, formaldehyde is used as a reducing agent, whereas triethylamine serves as both a promoter and a stabilizer [8].

Ag-NPs' toxicological evidence is currently inadequate, and safety standards for these nanoparticles must be established. Engineered nanomaterials that have harmful impacts on fish include carbon nanotubes, carbon spheres termed fullerenes [24], metal nanoparticles [25,26], metal oxides [27], and composites consisting of various metals [28]. There is less information about Ag-NPs toxicity, particularly genotoxicity and cytotoxicity [29,30]. Size and surface area are important toxicity factors [31]. According to the research, Ag-NPs are more harmful than other types because they are more easily absorbed. When Ag-NPs reach the aquatic environment, they cause a physiological reaction and genotoxicity in animals [32,33]. Ag-NPs cause oxidative stress in aquatic species, according to further studies [34,35]. By increasing the production of reactive oxygen species, they promote lipid peroxidation, interaction with nucleic acid, lipid and protein, loss of membrane integrity, functional changes, and mutation (ROS). Nanoparticles have also been discovered to cause toxicity by raising intracellular ROS levels and lowering antioxidant levels [35,36]. Increased ROS levels are also an indication of acute toxicity's main mechanism [37,38]. In reaction to Ag-NPs, mitochondrial function was recently discovered to be impaired [39]. Miao, et al. [40] showed that Ag-NPs are harmful to the marine diatom, *Thalassiosira weissflogii*. Furthermore, Ag-NPs toxicity in a freshwater alga (*Chlamydomonas reinhardtii*) has been reported [41]. Kakakhel et al. [42] tested freshwater fish, *Cyprinus carpio*, for toxicity, mortality, bioaccumulation, and histological changes after exposing them to silver nanoparticles for longer term. The findings indicate the bioaccumulation of silver nanoparticles in many organs of fish. The liver had the highest bioaccumulation of silver nanoparticles, followed by the intestine, gills, and muscles. Furthermore, the study revealed that silver nanoparticle bioaccumulation resulted in histopathological changes, including damaged gill tissue and intestinal structure.

Fish species have been commonly utilized as a pollution indicator in studies of aquatic toxicity, and they respond significantly to stress conditions [1,43–45]. The acute toxicity effects of Ag-NPs were investigated in this study utilizing *Capoeta capoeta* as an in vivo model. Hematological, biochemical, and histopathological characteristics have long been regarded as useful indicators of fish health. The effects of Ag-NPs on these parameters of *Capoeta capoeta* were examined in this work. These results would be crucial in determining the possible toxicity and bio-distribution of Ag-NPs in the piscine model.

## 2. Materials and Methods

### 2.1. Study Site and Fish Maintenance

The ZarrinGol River is one of the main tributaries of the Gorgan River which is located in Golestan Province and the geographical location of the river (longitude:  $40^{\circ}43'54''$  to  $36^{\circ}11'55''$  East and latitude:  $30^{\circ}43'36''$  Up to  $44^{\circ}08'37''$  North). Due to the particle size of the bed particles, this river is one of the rivers with a coarse bed (rocky–sandy). One-hundred and seventy pieces of *Capoeta* were caught from the ZarrinGol River in Golestan Province using an electroshock device. The average weight of fish was  $15 \pm 3.5$  g. The fish were transferred to the aquaculture Hall of Gorgan University of Agricultural Sciences and

Natural Resources using plastic containers, one-third of which were air. The fish were adapted to the new conditions for 4 weeks before the start of the experiment. During the adaptation period, the water in the tanks was aerated, the feeding was done twice a day, and the feeding was stopped during the experimental period. During the experimental period, the amount of aeration, feeding, and physicochemical conditions of water (temperature, pH, dissolved oxygen) were controlled. No mortality was observed during the experimental period. After feeding, uneaten food was siphoned off the bottom of the tanks to prevent contamination of the aquarium water. Throughout the experimental period, all ethical concerns were met as per the regulation provided by the Institutional Biosafety Committee-Gorgan University of Agricultural Science and Natural Resources (9523024101e.gau).

## 2.2. Test Chemical

This study was performed using a standardized composition of silver nanoparticles (Ag-NPs) (trade name-Nanonasb L-2000) purchased from Nanonasb Pars Co., Tehran, Iran. The NPs were characterized in the MilliQ water. The surface plasmon resonance analysis of Ag-NPs was carried out in a quartz cuvette with a path length of 1 cm using a Varian Cary 50 UV-visible spectrophotometer [46]. Drop-casting the NP solution on carbon-coated copper grids measured the NP size using transmission electron microscopy at 100 kV. (JEOL 1010) [46]. The zeta potential and hydrodynamic diameter (HDD) of the nanoparticles were measured on a Zetasizer using a folded capillary cell and a glass cuvette, respectively (dynamic light scattering; Malvern Zetasizer Nano series, NanoZS).

## 2.3. Experimental Setup

### 2.3.1. Acute Toxicity Assay

Following the adaption phase, 105 fish were separated into five groups (average weight: 153.5 g) with three replicates (12 aquariums: 1,506,565 cm), and treated with four different Ag-NP concentrations. Acute toxicity of Ag-NPs to fish was assessed by exposing them to four concentrations of Ag-NPs plus a blank control (0 mL/L). The testing time was 96 h and the nominal Ag-NPs concentrations were 0, 5, 10, 15, and 20 mL/L; these concentrations were selected according to Mohsenpour et al.'s [17] study and the laboratory facilities. The number of fish deaths was recorded 24, 48, 72, and 96 h after exposure of the fish to Ag-NPs [5]. The fish were moved into the aquarium or test tank 48 h before the start of the test and did not eat during the toxicity test. pH 7.9–8.6, DO 7.9–8.6 mgL<sup>-1</sup>, NH<sub>3</sub> 0.02 mgL<sup>-1</sup>, temperature 24 ± 2 °C, and total hardness 210 mgL<sup>-1</sup> CaCO<sub>3</sub> were maintained during the adaption periods. The LC<sub>50</sub> 96 h test was conducted in a static environment. Finally, the concentrations of Ag-NPs were manually added. During the LC<sub>50</sub> 96 h test, a camera (Canon, SX230 Hs, 5.0–70 mm) was used to record fish swimming in front of the aquarium.

### 2.3.2. Blood Collection and Assay of Hematological Endpoints

Blood was drawn from the caudal vein. Using this method, the sample was taken from the midline, somewhat posterior to the anal fin. Before being delivered to the lab for hematological analysis, blood samples were spun at 2500 rpm for 10 min. Blood samples were taken from each tank's fish and 12 blood samples were analyzed. Total protein, albumin, triglyceride, cholesterol, and glucose levels in serum from each sample were measured using an automated biochemical analyzer (Roche Hitachi 911 Chemistry Analyzer, Tokyo, Japan) and accompanying kits (Pars Azmoon Inc., Tehran, Iran) [47]. The samples were collected from live fish subjected to sub-lethal levels of Ag-NPs for 96 h.

### 2.3.3. Histopathological Analysis

Fish gill specimens were collected 96 h after Ag-NPs exposure (4 samples per treatment) and treated with a diluted Formalin solution (formaldehyde 10% v/v, Sigma<sup>®</sup>, Missouri, CA, USA). After 24 h, the gill and liver samples were replaced with formalin. The center parts of the liver and the second-gill arch from the fish's left side were sampled.

The samples were submerged in a series of alcohols for 30 min (50, 70, 80, and 96 percent). The gill sample was then cleaned for two hours in 1-butanol alcohol before being immersed in chloroform for one hour of clarity. The gill samples were then paraffinized and softened in an incubator at 37 °C using a chloroform and paraffin solution (1:1). The tubes were then kept in pure paraffin for 24 h at 54 °C before being prepared for tissue incisions. The tissue incisions were 6 m thick and were created with tissue processor equipment (TP1020, Leica Microsystems Inc., Buffalo Grove, IL, USA). The tissue incisions were stained with hematoxylin and eosin. To monitor and analyze tissue damage, light microscopy (Model RH-85 UXL, UNILAB<sup>®</sup>, Delhi, India) was utilized. Alive fish were used to collect treatment tissue samples.

#### 2.3.4. Semi-Quantitative Scoring

In replicates of the different exposure concentrations and the control, histopathological alterations in gill and liver tissue were investigated. The severity of lesions was assessed using a slightly modified version of Rajkumar et al.'s [1] semi-quantitative grading approach. No histological alterations; (+) mild histopathological changes; (++) moderate histopathological changes; or (+++) severe histopathology changes were assigned to each lesion. Each modification was given a significance factor (1–3) depending on the implications for the organism's survival, according to Bernet, et al. [48]. As a result, the significance factor shows the likelihood of the change being reversed once the stressor or the organism's physiologic handling capacity has been removed.

#### 2.4. Statistical Analyses

A probit test was used to calculate the fatal concentration of Ag-NPs in intervals of 24, 48, 72, and 96 h (LC<sub>50</sub> 24 h, 48 h, 72 h, and 96 h of Ag-NPs). To evaluate the connection between different nominal concentrations of commercial Ag-NP compositions and mortality, the Spearman test was used (2-tail). Finally, using SPSS software's two-tailed significant Spearman testing, the relationship between the fish mortality rate and Ag-NP concentration was investigated (IBM SPSS Statistics 20). On a Windows platform, Adobe After Effects software (AAE CS6) was utilized to analyze the video data (Windows 7 Ultimate, Microsoft Corporation). Fish clinical symptoms were reported using video monitoring, average gill operculum activity in 1 min, and AAE CS6 color comparison of the item (fish) over time.

### 3. Results and Discussion

#### 3.1. Acute Toxicity

The UV-visible absorbance spectra of Ag-NPs exhibit an SPR (surface plasmon resonance) band at 406 nm, which is typical of Ag-NPs, and a peak at 274 nm [46,49]. The HDD (hydrodynamic diameter) was 86.6 nm, whereas core size determined by TEM was ~30 nm in diameter. The negative charge of Ag-NPs, as determined by zeta potential, is −42.4 mV. [49]

The experimental fish (*Capoeta capoeta*) was administered various exposure concentrations of Ag-NPs (5, 10, 15, and 20 mgL<sup>−1</sup>) to determine the LC<sub>50</sub> value. Syafiuddin, et al. [50] recorded AgNP values in rivers and sewage treatment plants ranging from 0.13 to 10.16 mgL<sup>−1</sup> and 0.13 to 20.02 mgL<sup>−1</sup>, respectively, in Malaysia. Thus, we selected these concentrations of Ag-NPs for toxicity testing on fish hematological and biochemical endpoints. Based on the standard protocols of 96-h toxicity tests, we chose the durations of experiments [51–53].

The mortality in each group was thoroughly investigated and documented after the 96-h treatment period. The mortality of exposed *C. capoeta* to Ag-NPs is presented in Table 1. The LC<sub>50</sub> values of Ag-NPs to *C. capoeta* were 17.213, 14.038, 11.574, and 9.619 mgL<sup>−1</sup> after 24, 48, 72, and 96 h of exposure (with 95% fiducial intervals) (Table 2). The correlation between nominal lethal concentrations of Ag-NPs with the mortality rate of *C. capoeta* ( $p < 0.01$ ) is shown in Figure 1. During the entire study period, there was no death of fish

in the control group. The effectiveness of chemically manufactured Ag-NPs was dose-dependent, and mortality increased as Ag-NPs exposure concentrations increased. At an exposure concentration of  $20 \text{ mg kg}^{-1}$ , 100% death was recorded, whereas the lowest concentrations of Ag-NPs, such as  $5 \text{ mg kg}^{-1}$ , had the lowest mortality rate. In the test animals, a significant relationship between mortality rate and exposure times was observed ( $p < 0.05$ ). The correlation between nominal lethal concentrations of Ag-NPs with the mortality rate of *C. capoeta* is summarized in the Supplementary Materials.

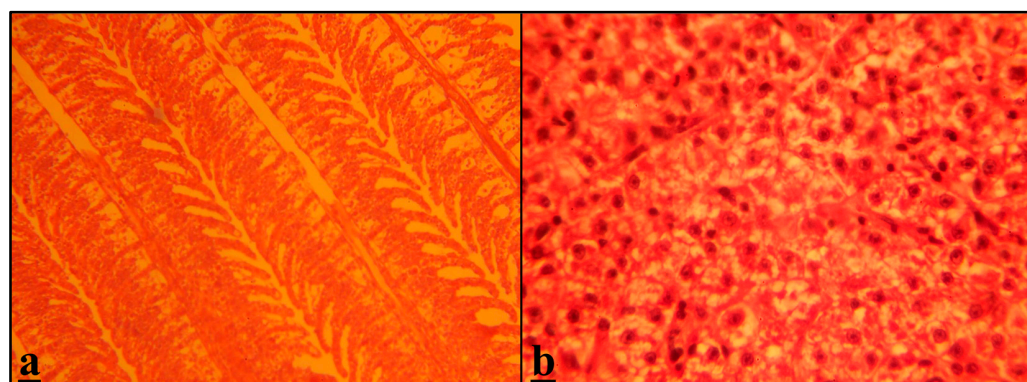
**Table 1.** Mortality of exposed *C. capoeta* to Ag-NPs.

Concentration ( $\text{mgL}^{-1}$ ) *	Number	No. of Mortality			
		24 h	48 h	72 h	96 h
0	21	0	0	0	0
5	21	1	3	4	5
10	21	3	6	8	10
15	21	9	11	14	18
20	21	13	17	20	21

Note: \* All concentrations are nominal concentrations.

**Table 2.** Lethal concentrations of Ag-NPs to *C. capoeta*.

Point	Concentration ( $\text{mgL}^{-1}$ )			
	24 h	48 h	72 h	96 h
LC <sub>10</sub>	8.161	5.049	4.164	3.609
LC <sub>20</sub>	11.268	8.135	6.708	5.672
LC <sub>30</sub>	13.509	10.360	8.542	7.160
LC <sub>40</sub>	15.424	12.261	10.109	8.431
LC <sub>50</sub>	17.213	14.038	11.574	9.619
LC <sub>60</sub>	19.003	15.815	13.039	10.808
LC <sub>70</sub>	20.918	17.716	14.606	12.079
LC <sub>80</sub>	23.158	19.941	16.440	13.567
LC <sub>90</sub>	26.266	23.027	18.984	15.630
LC <sub>95</sub>	28.832	25.575	21.084	17.334



**Figure 1.** (a,b) Tissue sample of Capoeta (*Capoeta capoeta*) in the control group ( $0 \text{ mgL}^{-1}$  of Ag-NPs); (a) gills of fish (magnified  $\times 40$ ); (b) liver of fish (magnified  $\times 40$ ).

Xue, et al. [54] conducted a study in which mice were given different doses of Ag-NPs (7.5, 30, or 120 mg/kg). The cells in the lung and liver of mice were induced to become inflamed at a dose of 120 mg/kg [54]. In TiO<sub>2</sub>-treated *Danio rerio*, the LC<sub>50</sub> value was estimated to be  $100 \text{ mgL}^{-1}$  [55,56]. Ag-NPs were used to generate the standard *Drosophila* culture medium at silver concentrations ranging from  $10 \text{ mgL}^{-1}$  to  $100 \text{ mgL}^{-1}$ , according to Panacek, et al. [57]. For a silver concentration of  $20 \text{ mgL}^{-1}$ , Ag-NPs had an acute toxic effect on *Drosophila melanogaster* [57]. At this level of silver, 50% of the tested flies were

unable to escape the pupae and did not complete their developmental cycle [57]. In the instance of *Daphnia magna*, García, et al. [58] found that cerium oxide NPs are exceedingly toxic, with an LC<sub>50</sub> of 0.012 mg/mL. In *Pangasius hypophthalmus*, Kumar, et al. [59] found that the lethal concentration of Se-NPs was 3.97 mgL<sup>-1</sup> after 96 h.

### 3.2. Hematological and Biochemical Endpoints

Hematology and biochemistry are important tools for monitoring health, diagnosing illness, and tracking disease progression and treatment response [47,60–71]. The effects of Ag-NPs on the hematological and biochemical parameters of the Caucasian scraper, *C. capoeta*, were investigated in this study.

The changes in RBC, WBC, and Hematocrit levels were investigated. When compared to other exposure concentrations and control fish samples, the levels of all the hematological parameters specified above were reduced at 5, 10, and 15 mg kg<sup>-1</sup> concentrations, according to the hematological investigations (Table 3). Stressful situations that alter the metabolism and regular functioning of the fish's physiology could cause changes in hematological markers [72–74]. The percentage of erythrocytes in blood smears also reduced (Table 3), indicating that the spleen was not replacing osmotically-damaged red cells in the circulation. Clark, et al. [75] found similar results when looking at the effects of Ag-NPs on the blood profile of rainbow trout. The treatment groups (5, 10, and 15 mgL<sup>-1</sup>) had significantly lower white blood cell counts (WBC) than the control group ( $p < 0.05$ ). The lowest overall value was recorded in groups administered 15 mgL<sup>-1</sup>. According to the findings, Ag-NPs can decrease the number of leucocytes in fish in experimental groups as compared to control groups. Despite minor statistical discrepancies, the Hct levels presented here are consistently falling with values for the normal range in Caucasian scraper, *C. capoeta* [76,77]. Furthermore, because the Hct values dropped at all exposure concentrations, the hematology is unlikely to be an artifact of gill damage-induced hypoxia. RBC, WBC, and Hct levels were lower in the treatment group than in the control group post-exposure to Ag-NPs. This indicated that higher levels of Ag-NPs can reduce the oxygen-carrying capacity of *C. capoeta* blood [78]. These negative effects could include Hb and RBC degeneration [79,80], hematological tissue damage [81], and the inhibition of aerobic glycolysis, resulting in a lack of energy for Hb synthesis [82,83].

**Table 3.** Hematological and biochemical endpoints (mean ± SD) of *C. capoeta* after exposure to different levels of Ag-NPs at 96 h.

Hematological and Biochemical Indices	Control (0 mgL <sup>-1</sup> )	5 mgL <sup>-1</sup>	10 mgL <sup>-1</sup>	15 mgL <sup>-1</sup>
RBC (10 <sup>6</sup> µL)	2.43 ± 0.06 <sup>a</sup>	1.97 ± 0.3 <sup>b</sup>	1.63 ± 0.12 <sup>c</sup>	1.28 ± 0.24 <sup>d</sup>
WBC (10 <sup>4</sup> µL)	2.35 ± 0.68 <sup>a</sup>	1.94 ± 0.5 <sup>b</sup>	1.90 ± 0.62 <sup>b</sup>	1.51 ± 0.50 <sup>c</sup>
Hematocrit (%)	46.63 ± 0.3 <sup>a</sup>	35.3 ± 0.5 <sup>b</sup>	35.3 ± 0.22 <sup>b</sup>	29.8 ± 0.38 <sup>c</sup>
Total serum glucose (mg/dL)	4.24 ± 0.07 <sup>a</sup>	4.19 ± 0.11 <sup>a</sup>	3.15 ± 0.17 <sup>b</sup>	2.02 ± 0.05 <sup>c</sup>
Total serum protein (mg/dL)	1.92 ± 0.31 <sup>d</sup>	2.98 ± 0.25 <sup>b</sup>	2.96 ± 0.13 <sup>b</sup>	3.78 ± 0.11 <sup>a</sup>
Triglyceride (mg/dL)	1.90 ± 0.09 <sup>d</sup>	2.23 ± 0.08 <sup>b</sup>	2.23 ± 0.03 <sup>b</sup>	2.98 ± 0.27 <sup>a</sup>
Cholesterol (mg/dL)	3.97 ± 0.21 <sup>c</sup>	3.98 ± 0.30 <sup>c</sup>	4.14 ± 0.14 <sup>b</sup>	4.12 ± 0.16 <sup>b</sup>
Albumin (mg/dL)	0.49 ± 0.13 <sup>c</sup>	0.63 ± 0.16 <sup>b</sup>	0.62 ± 0.11 <sup>b</sup>	0.78 ± 0.22 <sup>a</sup>

Note: Different letters (a–d) in the same columns indicate significant differences ( $p < 0.05$ ).

Exposed fish showed a significant dose- and time-dependent reduction in total serum glucose values in groups with higher exposure concentrations, but a significant increase in total serum protein, cholesterol, triglyceride, and albumin values in groups with increasing dose and exposure time when compared to control fish (Table 3). The raised triglyceride and cholesterol levels reported in the blood, muscle, and liver tissues of other fish exposed to various toxicants in the current study were also corroborated in the blood, muscle, and liver tissues of other fish [84–86]. This study's hypercholesterolemia could be related to a disrupted cholesterol transformation pathway, i.e., decreased enzyme activity in the conversion of cholesterol to bile acid [87]. The current rise in serum cholesterol levels in

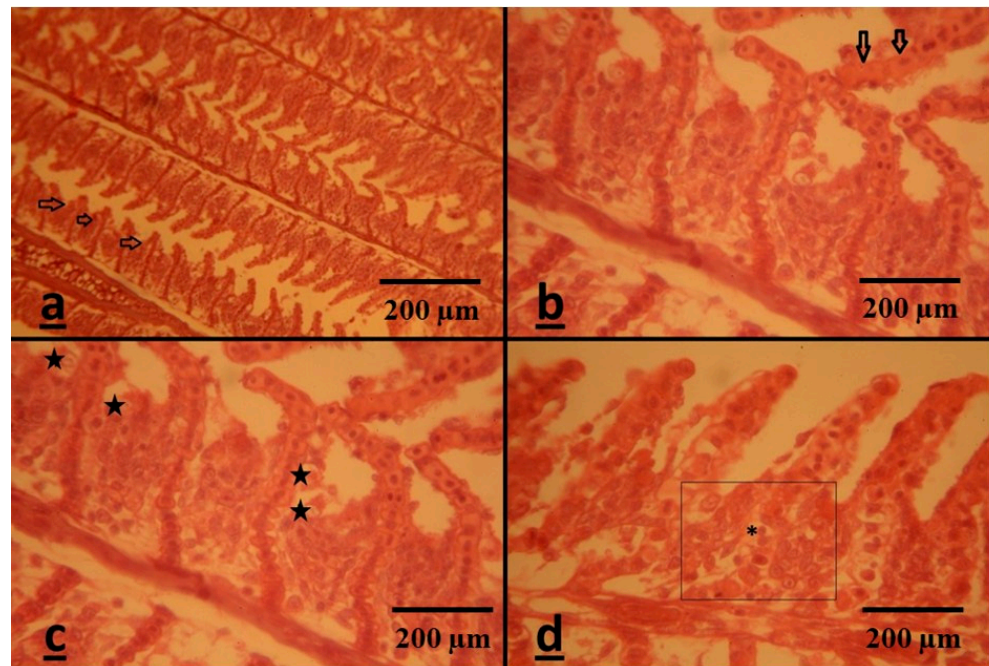
exposed fish may be due to the damaged liver parenchyma releasing volatile fatty acids into the circulation, or to decreased cholesterol excretion by the wounded liver in stressed fish [88]. Albumin is a high-molecular-weight serum protein that helps lipids, hormones, and inorganic ions flow about the body. Albumin helps the body filter fluids and maintain colloidal blood osmotic pressure [89]. Hyperalbuminemia was discovered in the current investigation as a result of exposure to Ag-NPs. When exposed to microplastic particles, *Cyprinus carpio* showed a similar trend of increased albumin levels [90].

### 3.3. Histopathological Assessment

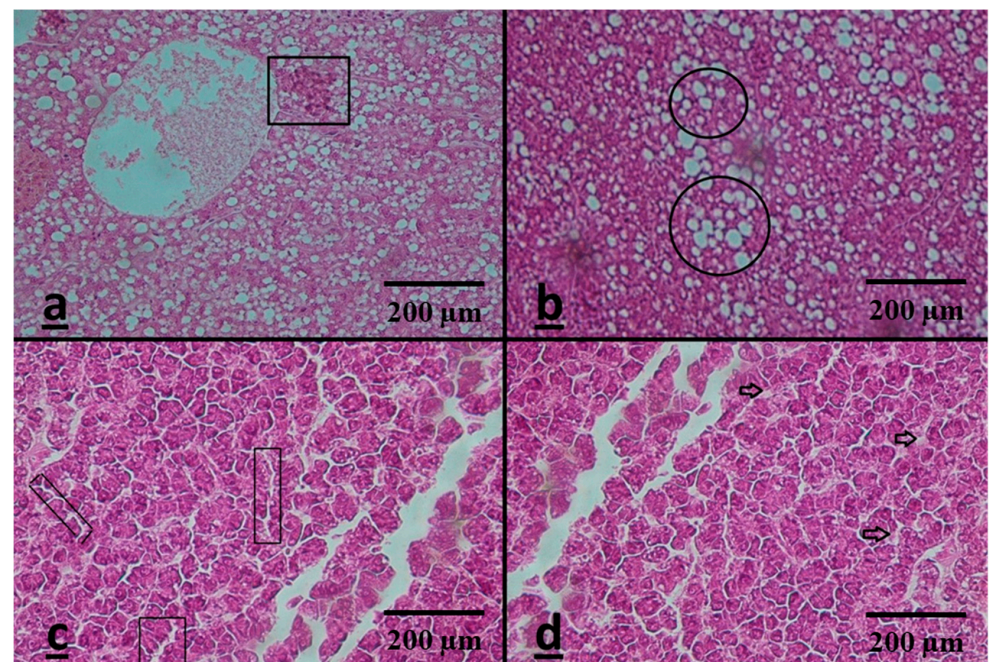
Several researchers have indicated histopathological investigations to be an effective method for measuring nanomaterial damage [91–96]. The effects of Ag-NPs on gills and liver tissue were studied in this study and it was observed that the level of harm increased as the concentration of Ag-NPs raised; however, no tissue lesions were recognized in tissue samples of the control group (Figure 1). The gills of *C. capoeta* represent a typical histological structure, with numerous secondary lamellae (SL) developing perpendicularly to the primary lamellae (PL) and a regular gill arch (Figure 2a–d). The SL had a typical primary lamellar architecture, intact epithelial lining, and normal inter-lamellar space. The Ag-NPs-exposed fish, on the other hand, demonstrated epithelial lifting of secondary lamellas (ELSL), epithelial hypertrophy (EH) of SL, leukocyte infiltration (LI), and bottom hyperplasia (BH). Remnants of a secondary lamellar tip separated from the primary lamella were also seen in numerous focus fields. Similar changes in the histological structure of the gill, liver, and muscle were seen in freshwater fish, *Oreochromis mossambicus* and *Labeo rohita*, subjected to manufactured silver nanoparticles [97,98]. The gills are the most important organ in fish, with breathing and osmoregulation as their principal roles [99–103]. Because of their large surface area and short diffusion distance, they are vulnerable to xenobiotic-induced water changes [104,105]. Changes in vascular regulation, sudden gaseous exchange, and, ultimately, homeostatic disturbance in fish result from these diverse histopathological lesions [106,107]. Kakakhel et al. observed the bioaccumulation of Ag-NPs in gills, liver, intestine, and muscles in *Cyprinus carpio* [42]. The results of their study revealed that the Ag-NPs were mostly bio-accumulated in the liver, followed by the intestine, gills, and muscles [42]. The gill tissue structure of *Cyprinus carpio* was damaged and led to atrophy and necrosis while exposed to Ag-NPs [42]. The gills of metallic nanoparticles-treated fish displayed lamellae fusion, aneurism formation, necrosis in secondary lamellae, and liposome expansion in zebrafish [108]. The gills of zebrafish exposed to copper nano-particulates were substantially broader than those of zebrafish exposed to soluble copper [108,109]. Griffitt, Hyndman, Denslow and Barber [108] found that Ag-NPs-exposed zebra fish had wider gill filaments.

The regular orientation of cord-like compact hepatocytes spreading out from the central vein to the margin of the hepatic lobules was seen in a histological cross-section of *C. capoeta* liver tissue. Nonetheless, macrophage aggregates (MA), fatty liver (FL), sinusoid dilation (DS), and necrosis (N) were seen in Ag-NPs-treated liver cross-sections (Figure 3a–d). The liver is the primary fish organ responsible for xenobiotic metabolism, detoxification, and excretion [110]. An excess of dangerous substances impairs the body's ability to break them down, resulting in a variety of histopathological alterations [111,112]. The activation of aberrant and physiologically nonfunctional proteins, which results in mitochondrion dysfunction and nuclear protein breakdown, could explain the histopathological abnormalities seen in the liver tissues of present Ag-NPs-treated *C. capoeta* [113,114]. Hypertrophy in the hepatocytes suggests an increase in the organelles involved in metabolism, as demonstrated in *Piaractus mesopotamicus* treated with veterinary pharmaceutical drugs [104]. Furthermore, all of the aforementioned diseases are most likely caused by the suppression of hepatic kinase enzymes, which are necessary to catalyze the phosphotransferase network, resulting in a reduction in hepatic energy homeostasis and ATP availability [115,116]. Ag-NPs accumulation in the liver has also been reported by previous studies [117,118]. These impacts and alterations were similar to those seen in silver nanoparticle-exposed *Oncorhynchus*

*mykiss* (rainbow trout) [91,119–122]. When Siberian sturgeon were exposed to Ag-NPs, Ostaszewska, et al. [123] detected histological changes in the gills and liver.



**Figure 2.** (a–d) Gill lesions of *Capoeta (Capoeta capoeta)* 96 h after exposure to different levels of Ag-NPs; (a) epithelial lifting of secondary lamellas (Ag-NPs were  $5 \text{ mgL}^{-1}$ —magnified  $\times 10$ ); (b) epithelial hypertrophy (Ag-NPs were  $5 \text{ mgL}^{-1}$ —magnified  $\times 40$ ); (c) leukocyte infiltration (Ag-NPs were  $10 \text{ mgL}^{-1}$ —magnified  $\times 40$ ); (d) bottom hyperplasia (Ag-NPs were  $15 \text{ mgL}^{-1}$ —magnified  $\times 40$ ).



**Figure 3.** (a–d) Liver lesions of *Capoeta (Capoeta capoeta)* 96 h after exposure to different levels of Ag-NPs; (a) macrophage aggregates (Ag-NPs were  $5 \text{ mgL}^{-1}$ —magnified  $\times 40$ ); (b) fatty liver (Ag-NPs were  $10 \text{ mgL}^{-1}$ —magnified  $\times 40$ ); (c) dilation of sinusoid (Ag-NPs were  $15 \text{ mgL}^{-1}$ —magnified  $\times 40$ ); (d) necrosis (Ag-NPs were  $15 \text{ mgL}^{-1}$ —magnified  $\times 40$ ).



## Semi-Quantitative Analysis

### Gills

Epithelial lifting of secondary lamellae, epithelial hypertrophy, bottom hyperplasia, and leukocyte infiltration have all been seen in exposed fish gills. Except for epithelial hypertrophy, which demonstrated progressive histological alterations, all changes in gill tissue were regression-type responses. Although all exposure groups had gill lesions, the degree of the lesions differed (Table 4). The fish exposed to 15 mgL<sup>-1</sup> Ag-NPs had moderate severity for all regression-type lesions and severe severity for progressive-type lesions, whereas the fish exposed to 5 and 10 mgL<sup>-1</sup> Ag-NPs had mild-to-moderate severity for regression-type lesions and moderate severity for progressive-type lesions. Regressive alterations have been linked to oxidative stress [124]; contaminant-induced enzyme inhibitions frequently cause oxidative stress, resulting in a loss of cellular membrane integrity and ultimate cell death [125–127].

**Table 4.** Gills damages of *Capoeta (Capoeta capoeta)* 96 h after exposure to different levels of Ag-NPs.

Tissue Damages	Reaction Pattern	Nominal Concentrations (mgL <sup>-1</sup> )			
		0	5	10	15
Epithelial lifting of secondary lamellae	R	–	++	++++	+++
Epithelial hypertrophy	P	–	+++	++++	+++
Bottom hyperplasia	R	–	++	++++	++++
Leukocyte infiltration	R	–	++	+++	++++

Notes: (–) No tissue damages observed; (+) there were tissue damages from 1 to 3; (++) there were tissue damages from 3 to 5; (+++) there were tissue damages from 5 to 9; (++++) there were tissue damages from 9 to 15. Abbreviations: (R) regressive changes, (P) progressive changes.

### Liver

Histopathological changes in the liver of exposed fish demonstrated a variety of lesions across exposure concentrations, including macrophage aggregates, fatty liver, dilation of sinusoids, and necrosis. Except for the increased sinusoidal space and macrophage aggregation, which are circulatory-type lesions, all of these lesions are regressive. The largest proportion of lesion severity was seen in the highest exposure group (15 mgL<sup>-1</sup> Ag-NPs) (Table 5). Furthermore, the uptake of the toxicant can be responsible for the increased severity of observed lesions in the liver tissue of the maximum concentration group [128].

**Table 5.** Liver damages of *Capoeta (Capoeta capoeta)* 96 h after exposure to different levels of Ag-NPs.

Tissue Damages	Reaction Pattern	Nominal Concentrations (mgL <sup>-1</sup> )			
		0	5	10	15
Macrophage aggregates	C	–	+++	+++	+++
fatty liver	R	–	+++	+++	++++
Dilation of sinusoid	C	–	++	+++	++++
necrosis	R	–	+	+++	++++

Notes: (–) No tissue damages observed; (+) there were tissue damages from 1 to 3; (++) there were tissue damages from 3 to 5; (+++) there were tissue damages from 5 to 9; (++++) there were tissue damages from 9 to 15. Abbreviations: (R) regressive changes, (C) circulatory disturbances.

## 4. Conclusions

The current study aimed to investigate the toxicity and toxic effects of Ag-NPs on *Capoeta capoeta*. According to the results of the present study, it can be concluded that the Ag-NPs have led to alterations of hematological and biochemical endpoints, as well as histological changes in the gills and liver. The hazardous potential of Ag-NPs in various industrial sectors should be carefully analyzed and effluents should be processed before being released into the environment to preserve aquatic eco-systems and human life, according to the findings of this experimental investigation. To protect aquatic organisms

against Ag-NPs exposure, water quality guidelines must be established based on data from toxicity studies relevant to diverse species in such environments.

**Supplementary Materials:** The following supporting information can be downloaded at: <https://www.mdpi.com/article/10.3390/w15030585/s1>, Figure S1. correlation between mortality rate of *C. capoeta* and silver nanoparticles (Ag-NPs).

**Author Contributions:** Conceptualization, Investigation, Methodology, Data Curation, Formal Analysis, Visualization, Writing—Reviewing and Editing: D.A.; Conceptualization, Investigation, Data Curation, Formal Analysis, Writing—Reviewing and Editing: A.M.Y.; Writing—Reviewing and Editing, Writing—Original Draft, Histopathological Scoring and Classification: S.S.; Writing—Reviewing and Editing, Supervision: N.C.S.; Writing—Reviewing and Editing, Supervision: C.F. All authors have read and agreed to the published version of the manuscript.

**Funding:** This research received no external funding.

**Data Availability Statement:** Not applicable.

**Acknowledgments:** The authors are thankful to the Department of Pathobiology, Islamic Azad University and Department of Fisheries Sciences, Gorgan University of Agricultural Science and Natural Resources, Iran for the laboratory facilities.

**Conflicts of Interest:** The authors declare no conflict of interest.

## References

1. Rajkumar, K.; Kanipandian, N.; Thirumurugan, R. Toxicity assessment on haematology, biochemical and histopathological alterations of silver nanoparticles-exposed freshwater fish *Labeo rohita*. *Appl. Nanosci.* **2016**, *6*, 19–29. [[CrossRef](#)]
2. Tortella, G.; Rubilar, O.; Durán, N.; Diez, M.; Martínez, M.; Parada, J.; Seabra, A. Silver nanoparticles: Toxicity in model organisms as an overview of its hazard for human health and the environment. *J. Hazard. Mater.* **2020**, *390*, 121974. [[CrossRef](#)] [[PubMed](#)]
3. Saha, S.; Chukwuka, A.V.; Mukherjee, D.; Dhara, K.; Saha, N.C.; Faggio, C. Behavioral and physiological toxicity thresholds of a freshwater vertebrate (*Heteropneustes fossilis*) and invertebrate (*Branchiura sowerbyi*), exposed to zinc oxide nanoparticles (nZnO): A General Unified Threshold model of Survival (GUTS). *Comp. Biochem. Physiol. Part C Toxicol. Pharmacol.* **2022**, *2022*, 109450. [[CrossRef](#)] [[PubMed](#)]
4. Selvaraj, V.; Mahboub, H.H.; Ganapathi, U.; Chandran, S.K.; Al-Onazi, W.; Al-Mohaimed, A.M.; Chen, T.-W.; Faggio, C.; Paulraj, B. Enhanced photodegradation of methylene blue from aqueous solution using Al-doped ZnS nanoparticles. *Environ. Sci. Pollut. Res.* **2022**, *29*, 73528–73541. [[CrossRef](#)] [[PubMed](#)]
5. Vali, S.; Majidiyan, N.; Yalsuyi, A.M.; Vajargah, M.F.; Prokić, M.D.; Faggio, C. Ecotoxicological Effects of Silver Nanoparticles (Ag-NPs) on Parturition Time, Survival Rate, Reproductive Success and Blood Parameters of Adult Common Molly (*Poecilia sphenops*) and Their Larvae. *Water* **2022**, *14*, 144. [[CrossRef](#)]
6. Yue, Y.; Behra, R.; Sigg, L.; Fernandez Freire, P.; Pillai, S.; Schirmer, K. Toxicity of silver nanoparticles to a fish gill cell line: Role of medium composition. *Nanotoxicology* **2015**, *9*, 54–63. [[CrossRef](#)]
7. Jovanović, B.; Anastasova, L.; Rowe, E.W.; Zhang, Y.; Clapp, A.R.; Palić, D. Effects of nanosized titanium dioxide on innate immune system of fathead minnow (*Pimephales promelas* Rafinesque, 1820). *Ecotoxicol. Environ. Saf.* **2011**, *74*, 675–683. [[CrossRef](#)]
8. Khan, M.S.; Qureshi, N.A.; Jabeen, F.; Asghar, M.S.; Shakeel, M.; Fakhar-e-Alam, M. Eco-friendly synthesis of silver nanoparticles through economical methods and assessment of toxicity through oxidative stress analysis in the *Labeo rohita*. *Biol. Trace Elem. Res.* **2017**, *176*, 416–428. [[CrossRef](#)]
9. Khan, M.S.; Qureshi, N.A.; Jabeen, F.; Shakeel, M.; Asghar, M.S. Assessment of waterborne amine-coated silver nanoparticle (Ag-NP)-induced toxicity in *Labeo rohita* by histological and hematological profiles. *Biol. Trace Elem. Res.* **2018**, *182*, 130–139. [[CrossRef](#)]
10. Ale, A.; Rossi, A.S.; Bacchetta, C.; Gervasio, S.; de la Torre, F.R.; Cazenave, J. Integrative assessment of silver nanoparticles toxicity in *Prochilodus lineatus* fish. *Ecol. Indic.* **2018**, *93*, 1190–1198. [[CrossRef](#)]
11. Paulpandian, P.; Beevi, I.S.; Somanath, B.; Kamatchi, R.K.; Paulraj, B.; Faggio, C. Impact of *Camellia sinensis* Iron Oxide Nanoparticle on Growth, Hemato-biochemical and Antioxidant Capacity of Blue Gourami (*Trichogaster trichopterus*) Fingerlings. *Biol. Trace Elem. Res.* **2022**, *201*, 412–424. [[CrossRef](#)] [[PubMed](#)]
12. Rashidian, G.; Lazado, C.C.; Mahboub, H.H.; Mohammadi-Aloucheh, R.; Prokić, M.D.; Nada, H.S.; Faggio, C. Chemically and green synthesized ZnO nanoparticles alter key immunological molecules in common carp (*Cyprinus carpio*) skin mucus. *Int. J. Mol. Sci.* **2021**, *22*, 3270. [[CrossRef](#)]
13. Forouhar Vajargah, M.; Mohamadi Yalsuyi, A.; Sattari, M.; Prokić, M.D.; Faggio, C. Effects of copper oxide nanoparticles (CuO-NPs) on parturition time, survival rate and reproductive success of guppy fish, *Poecilia reticulata*. *J. Clust. Sci.* **2020**, *31*, 499–506. [[CrossRef](#)]

14. Murthy, M.K.; Mohanty, C.S.; Swain, P.; Pattanayak, R. Assessment of toxicity in the freshwater tadpole *Polypedates maculatus* exposed to silver and zinc oxide nanoparticles: A multi-biomarker approach. *Chemosphere* **2022**, *2022*, 133511. [[CrossRef](#)] [[PubMed](#)]
15. Nohynek, G.J.; Lademann, J.; Ribaud, C.; Roberts, M.S. Grey goo on the skin? Nanotechnology, cosmetic and sunscreen safety. *Crit. Rev. Toxicol.* **2007**, *37*, 251–277. [[CrossRef](#)] [[PubMed](#)]
16. Vijayakumar, S.; Vaseeharan, B.; Sudhakaran, R.; Jeyakandan, J.; Ramasamy, P.; Sonawane, A.; Padhi, A.; Velusamy, P.; Anbu, P.; Faggio, C. Bioinspired zinc oxide nanoparticles using *Lycopersicon esculentum* for antimicrobial and anticancer applications. *J. Clust. Sci.* **2019**, *30*, 1465–1479. [[CrossRef](#)]
17. Mohsenpour, R.; Mousavi-Sabet, H.; Hedayati, A.; Rezaei, A.; Yalsuyi, A.M.; Faggio, C. In vitro effects of silver nanoparticles on gills morphology of female Guppy (*Poecilia reticulata*) after a short-term exposure. *Microsc. Res. Tech.* **2020**, *83*, 1552–1557. [[CrossRef](#)]
18. Forouhar Vajargah, M.; Imanpoor, M.R.; Shabani, A.; Hedayati, A.; Faggio, C. Effect of long-term exposure of silver nanoparticles on growth indices, hematological and biochemical parameters and gonad histology of male goldfish (*Carassius auratus gibelio*). *Microsc. Res. Tech.* **2019**, *82*, 1224–1230. [[CrossRef](#)]
19. Taju, G.; Majeed, S.A.; Nambi, K.; Hameed, A.S. In vitro assay for the toxicity of silver nanoparticles using heart and gill cell lines of Catla catla and gill cell line of Labeo rohita. *Comp. Biochem. Physiol. Part A Mol. Integr. Physiol.* **2014**, *161*, 41–52. [[CrossRef](#)]
20. Marin, S.; Mihail Vlasceanu, G.; Elena Tiplea, R.; Raluca Bucur, I.; Lemnaru, M.; Minodora Marin, M.; Mihai Grumezescu, A. Applications and toxicity of silver nanoparticles: A recent review. *Curr. Top. Med. Chem.* **2015**, *15*, 1596–1604. [[CrossRef](#)]
21. Cross, S.E.; Innes, B.; Roberts, M.S.; Tsuzuki, T.; Robertson, T.A.; McCormick, P. Human skin penetration of sunscreen nanoparticles: In-vitro assessment of a novel micronized zinc oxide formulation. *Ski. Pharmacol. Physiol.* **2007**, *20*, 148–154. [[CrossRef](#)] [[PubMed](#)]
22. Galdames, A.; Mendoza, A.; Orueta, M.; de Soto García, I.; Sánchez, M.; Virto, I.; Vilas, J. Development of new remediation technologies for contaminated soils based on the application of zero-valent iron nanoparticles and bioremediation with compost. *Resour. -Effic. Technol.* **2017**, *3*, 166–176. [[CrossRef](#)]
23. Dakal, T.C.; Kumar, A.; Majumdar, R.S.; Yadav, V. Mechanistic basis of antimicrobial actions of silver nanoparticles. *Front. Microbiol.* **2016**, *7*, 1831. [[CrossRef](#)] [[PubMed](#)]
24. Oberdörster, E.; Zhu, S.; Blickley, T.M.; McClellan-Green, P.; Haasch, M.L. Ecotoxicology of carbon-based engineered nanoparticles: Effects of fullerene (C60) on aquatic organisms. *Carbon* **2006**, *44*, 1112–1120. [[CrossRef](#)]
25. Shaw, B.J.; Al-Bairuty, G.; Handy, R.D. Effects of waterborne copper nanoparticles and copper sulphate on rainbow trout, (*Oncorhynchus mykiss*): Physiology and accumulation. *Aquat. Toxicol.* **2012**, *116*, 90–101. [[CrossRef](#)] [[PubMed](#)]
26. Al-Bairuty, G.A.; Shaw, B.J.; Handy, R.D.; Henry, T.B. Histopathological effects of waterborne copper nanoparticles and copper sulphate on the organs of rainbow trout (*Oncorhynchus mykiss*). *Aquat. Toxicol.* **2013**, *126*, 104–115. [[CrossRef](#)]
27. Linhua, H.; Zhenyu, W.; Baoshan, X. Effect of sub-acute exposure to TiO<sub>2</sub> nanoparticles on oxidative stress and histopathological changes in Juvenile Carp (*Cyprinus carpio*). *J. Environ. Sci.* **2009**, *21*, 1459–1466.
28. Chen, G.; Roy, I.; Yang, C.; Prasad, P.N. Nanochemistry and nanomedicine for nanoparticle-based diagnostics and therapy. *Chem. Rev.* **2016**, *116*, 2826–2885. [[CrossRef](#)]
29. Chernousova, S.; Epple, M. Silver as antibacterial agent: Ion, nanoparticle, and metal. *Angew. Chem. Int. Ed.* **2013**, *52*, 1636–1653. [[CrossRef](#)]
30. Rai, M.K.; Deshmukh, S.; Ingle, A.; Gade, A. Silver nanoparticles: The powerful nanoweapon against multidrug-resistant bacteria. *J. Appl. Microbiol.* **2012**, *112*, 841–852. [[CrossRef](#)]
31. Ji, J.H.; Jung, J.H.; Kim, S.S.; Yoon, J.-U.; Park, J.D.; Choi, B.S.; Chung, Y.H.; Kwon, I.H.; Jeong, J.; Han, B.S. Twenty-eight-day inhalation toxicity study of silver nanoparticles in Sprague-Dawley rats. *Inhal. Toxicol.* **2007**, *19*, 857–871. [[CrossRef](#)] [[PubMed](#)]
32. Cui, R.; Chae, Y.; An, Y.-J. Dimension-dependent toxicity of silver nanomaterials on the cladocerans *Daphnia magna* and *Daphnia galeata*. *Chemosphere* **2017**, *185*, 205–212. [[CrossRef](#)] [[PubMed](#)]
33. Rodriguez-Garraus, A.; Azqueta, A.; Vettorazzi, A.; Lopez de Cerain, A. Genotoxicity of silver nanoparticles. *Nanomaterials* **2020**, *10*, 251. [[CrossRef](#)] [[PubMed](#)]
34. Liao, S.; Zhang, Y.; Pan, X.; Zhu, F.; Jiang, C.; Liu, Q.; Cheng, Z.; Dai, G.; Wu, G.; Wang, L. Antibacterial activity and mechanism of silver nanoparticles against multidrug-resistant *Pseudomonas aeruginosa*. *Int. J. Nanomed.* **2019**, *14*, 1469. [[CrossRef](#)]
35. Kim, S.; Ryu, D.Y. Silver nanoparticle-induced oxidative stress, genotoxicity and apoptosis in cultured cells and animal tissues. *J. Appl. Toxicol.* **2013**, *33*, 78–89. [[CrossRef](#)]
36. Flores-López, L.Z.; Espinoza-Gómez, H.; Somanathan, R. Silver nanoparticles: Electron transfer, reactive oxygen species, oxidative stress, beneficial and toxicological effects. Mini review. *J. Appl. Toxicol.* **2019**, *39*, 16–26. [[CrossRef](#)]
37. Kaewamatawong, T.; Shimada, A.; Okajima, M.; Inoue, H.; Morita, T.; Inoue, K.; Takano, H. Acute and subacute pulmonary toxicity of low dose of ultrafine colloidal silica particles in mice after intratracheal instillation. *Toxicol. Pathol.* **2006**, *34*, 958–965. [[CrossRef](#)]
38. Tresnakova, N.; Famulari, S.; Zicarelli, G.; Impellitteri, F.; Pagano, M.; Presti, G.; Filice, M.; Caferro, A.; Gulotta, E.; Salvatore, G. Multi-characteristic toxicity of enantioselective chiral fungicide tebuconazole to a model organism Mediterranean mussel *Mytilus galloprovincialis* Lamarck, 1819 (Bivalve: Mytilidae). *Sci. Total Environ.* **2022**, *862*, 160874. [[CrossRef](#)]

39. Hussain, S.; Hess, K.; Gearhart, J.; Geiss, K.; Schlager, J. In vitro toxicity of nanoparticles in BRL 3A rat liver cells. *Toxicol. Vitr.* **2005**, *19*, 975–983. [[CrossRef](#)]
40. Miao, A.-J.; Schwehr, K.A.; Xu, C.; Zhang, S.-J.; Luo, Z.; Quigg, A.; Santschi, P.H. The algal toxicity of silver engineered nanoparticles and detoxification by exopolymeric substances. *Environ. Pollut.* **2009**, *157*, 3034–3041. [[CrossRef](#)]
41. Navarro, E.; Piccapietra, F.; Wagner, B.; Marconi, F.; Kaegi, R.; Odzak, N.; Sigg, L.; Behra, R. Toxicity of silver nanoparticles to *Chlamydomonas reinhardtii*. *Environ. Sci. Technol.* **2008**, *42*, 8959–8964. [[CrossRef](#)] [[PubMed](#)]
42. Kakakhel, M.A.; Wu, F.; Sajjad, W.; Zhang, Q.; Khan, I.; Ullah, K.; Wang, W. Long-term exposure to high-concentration silver nanoparticles induced toxicity, fatality, bioaccumulation, and histological alteration in fish (*Cyprinus carpio*). *Environ. Sci. Eur.* **2021**, *33*, 44. [[CrossRef](#)]
43. Mukherjee, D.; Saha, S.; Chukwuka, A.V.; Ghosh, B.; Dhara, K.; Saha, N.C.; Pal, P.; Faggio, C. Antioxidant enzyme activity and pathophysiological responses in the freshwater walking catfish, *Clarias batrachus* Linn under sub-chronic and chronic exposures to the neonicotinoid, Thiamethoxam<sup>®</sup>. *Sci. Total Environ.* **2022**, *836*, 155716. [[CrossRef](#)] [[PubMed](#)]
44. Vali, S.; Majidiyan, N.; Azadikhah, D.; Varcheh, M.; Tresnakova, N.; Faggio, C. Effects of Diazinon on the Survival, Blood Parameters, Gills, and Liver of Grass Carp (*Ctenopharyngodon idella Valenciennes, 1844*; Teleostei: Cyprinidae). *Water* **2022**, *14*, 1357. [[CrossRef](#)]
45. Shahjahan, M.; Taslima, K.; Rahman, M.S.; Al-Emran, M.; Alam, S.I.; Faggio, C. Effects of heavy metals on fish physiology—A review. *Chemosphere* **2022**, *300*, 134519. [[CrossRef](#)] [[PubMed](#)]
46. Lekamge, S.; Miranda, A.F.; Abraham, A.; Li, V.; Shukla, R.; Bansal, V.; Nugegoda, D. The toxicity of silver nanoparticles (AgNPs) to three freshwater invertebrates with different life strategies: *Hydra vulgaris*, *Daphnia carinata*, and *Paratya australiensis*. *Front. Environ. Sci.* **2018**, *6*, 152. [[CrossRef](#)]
47. Saha, S.; Dhara, K.; Chukwuka, A.V.; Pal, P.; Saha, N.C.; Faggio, C. Sub-lethal acute effects of environmental concentrations of inorganic mercury on hematological and biochemical parameters in walking catfish, *Clarias batrachus*. *Comp. Biochem. Physiol. Part C Toxicol. Pharmacol.* **2022**, *264*, 109511. [[CrossRef](#)]
48. Bernet, D.; Schmidt, H.; Meier, W.; Burkhardt-Holm, P.; Wahli, T. Histopathology in fish: Proposal for a protocol to assess aquatic pollution. *J. Fish Dis.* **1999**, *22*, 25–34. [[CrossRef](#)]
49. Daima, H.K.; Selvakannan, P.; Kandjani, A.E.; Shukla, R.; Bhargava, S.K.; Bansal, V. Synergistic influence of polyoxometalate surface corona towards enhancing the antibacterial performance of tyrosine-capped Ag nanoparticles. *Nanoscale* **2014**, *6*, 758–765. [[CrossRef](#)]
50. Syafiuiddin, A.; Salmiati, S.; Hadibarata, T.; Kueh, A.B.H.; Salim, M.R.; Zaini, M.A.A. Silver nanoparticles in the water environment in Malaysia: Inspection, characterization, removal, modeling, and future perspective. *Sci. Rep.* **2018**, *8*, 986. [[CrossRef](#)]
51. Butler, J.D.; Varghese, L.; Deb, N.; Thornhill, B. Extending international toxicity testing guidance to middle eastern test species. *Sci. Total Environ.* **2020**, *716*, 136343. [[CrossRef](#)] [[PubMed](#)]
52. Chen, C.-Y.; Lin, K.-C.; Yang, D.-T. Comparison of the relative toxicity relationships based on batch and continuous algal toxicity tests. *Chemosphere* **1997**, *35*, 1959–1965. [[CrossRef](#)]
53. Schipper, C.A.; Dubbeldam, M.; Feist, S.W.; Rietjens, I.M.; Murk, A.T. Cultivation of the heart urchin *Echinocardium cordatum* and validation of its use in marine toxicity testing for environmental risk assessment. *J. Exp. Mar. Biol. Ecol.* **2008**, *364*, 11–18. [[CrossRef](#)]
54. Xue, Y.; Zhang, S.; Huang, Y.; Zhang, T.; Liu, X.; Hu, Y.; Zhang, Z.; Tang, M. Acute toxic effects and gender-related biokinetics of silver nanoparticles following an intravenous injection in mice. *J. Appl. Toxicol.* **2012**, *32*, 890–899. [[CrossRef](#)] [[PubMed](#)]
55. Diniz, M.S.; De Matos, A.P.A.; Lourenço, J.; Castro, L.; Peres, I.; Mendonça, E.; Picado, A. Liver alterations in two freshwater fish species (*Carassius auratus* and *Danio rerio*) following exposure to different TiO<sub>2</sub> nanoparticle concentrations. *Microsc. Microanal.* **2013**, *19*, 1131–1140. [[CrossRef](#)]
56. Xiong, D.; Fang, T.; Yu, L.; Sima, X.; Zhu, W. Effects of nano-scale TiO<sub>2</sub>, ZnO and their bulk counterparts on zebrafish: Acute toxicity, oxidative stress and oxidative damage. *Sci. Total Environ.* **2011**, *409*, 1444–1452. [[CrossRef](#)]
57. Panacek, A.; Pucek, R.; Safarova, D.; Dittrich, M.; Richtrova, J.; Benickova, K.; Zboril, R.; Kvittek, L. Acute and chronic toxicity effects of silver nanoparticles (NPs) on *Drosophila melanogaster*. *Environ. Sci. Technol.* **2011**, *45*, 4974–4979. [[CrossRef](#)]
58. García, A.; Espinosa, R.; Delgado, L.; Casals, E.; González, E.; Puentes, V.; Barata, C.; Font, X.; Sánchez, A. Acute toxicity of cerium oxide, titanium oxide and iron oxide nanoparticles using standardized tests. *Desalination* **2011**, *269*, 136–141. [[CrossRef](#)]
59. Kumar, N.; Krishnani, K.K.; Singh, N.P. Comparative study of selenium and selenium nanoparticles with reference to acute toxicity, biochemical attributes, and histopathological response in fish. *Environ. Sci. Pollut. Res.* **2018**, *25*, 8914–8927. [[CrossRef](#)]
60. Saha, S.; Chukwuka, A.V.; Mukherjee, D.; Patnaik, L.; Nayak, S.; Dhara, K.; Saha, N.C.; Faggio, C. Chronic Effects of Diazinon<sup>®</sup> Exposures Using Integrated Biomarker Responses in Freshwater Walking Catfish, *Clarias batrachus*. *Appl. Sci.* **2021**, *11*, 10902. [[CrossRef](#)]
61. Saha, S.; Chukwuka, A.V.; Mukherjee, D.; Dhara, K.; Pal, P.; Saha, N.C. Physiological (haematological, growth and endocrine) and biochemical biomarker responses in air-breathing catfish, *Clarias batrachus* under long-term Captan<sup>®</sup> pesticide exposures. *Environ. Toxicol. Pharmacol.* **2022**, *90*, 103815. [[CrossRef](#)] [[PubMed](#)]
62. Sharma, S.; Iqbal Dar, O.; Andotra, M.; Sharma, S.; Kaur, A.; Faggio, C. Environmentally relevant concentrations of Triclosan induce cyto-genotoxicity and biochemical alterations in the hatchlings of *Labeo rohita*. *Appl. Sci.* **2021**, *11*, 10478. [[CrossRef](#)]

63. Sharma, S.; Dar, O.I.; Singh, K.; Kaur, A.; Faggio, C. Triclosan elicited biochemical and transcriptomic alterations in *Labeo rohita* larvae. *Environ. Toxicol. Pharmacol.* **2021**, *88*, 103748. [[CrossRef](#)] [[PubMed](#)]
64. Gopi, N.; Rekha, R.; Vijayakumar, S.; Liu, G.; Monserrat, J.M.; Faggio, C.; Nor, S.A.M.; Vaseeharan, B. Interactive effects of freshwater acidification and selenium pollution on biochemical changes and neurotoxicity in *Oreochromis mossambicus*. *Comp. Biochem. Physiol. Part C Toxicol. Pharmacol.* **2021**, *250*, 109161. [[CrossRef](#)]
65. Sharma, R.; Jindal, R.; Faggio, C. Cassia fistula ameliorates chronic toxicity of cypermethrin in *Catla catla*. *Comp. Biochem. Physiol. Part C Toxicol. Pharmacol.* **2021**, *248*, 109113. [[CrossRef](#)] [[PubMed](#)]
66. Burgos-Aceves, M.A.; Lionetti, L.; Faggio, C. Multidisciplinary haematology as prognostic device in environmental and xenobiotic stress-induced response in fish. *Sci. Total Environ.* **2019**, *670*, 1170–1183. [[CrossRef](#)]
67. Saha, S.; Chukwuka, A.V.; Mukherjee, D.; Dhara, K.; Adeogun, A.O.; Saha, N.C. Effects of short-term sub-lethal diazinon<sup>®</sup> exposure on behavioural patterns and respiratory function in *Clarias batrachus*: Inferences for adaptive capacity in the wild. *Chem. Ecol.* **2022**, *38*, 180–194. [[CrossRef](#)]
68. Faggio, C.; Piccione, G.; Marafioti, S.; Arfuso, F.; Fortino, G.; Fazio, F. Metabolic response to monthly variations of *Sparus aurata* reared in Mediterranean on-shore tanks. *Turk. J. Fish. Aquat. Sci.* **2014**, *14*, 567–574.
69. Hodkovicova, N.; Hollerova, A.; Svobodova, Z.; Faldyna, M.; Faggio, C. Effects of Plastic Particles on Aquatic Invertebrates and Fish—A Review. *Environ. Toxicol. Pharmacol.* **2022**, *96*, 104013. [[CrossRef](#)]
70. Banaee, M.; Impellitteri, F.; Evaz-Zadeh Samani, H.; Piccione, G.; Faggio, C. Dietary *Arthrospira platensis* in Rainbow Trout (*Oncorhynchus mykiss*): A Means to Reduce Threats Caused by CdCl<sub>2</sub> Exposure? *Toxics* **2022**, *10*, 731. [[CrossRef](#)]
71. Impellitteri, F.; Curpán, A.-S.; Plăvan, G.; Ciobica, A.; Faggio, C. Hemocytes: A Useful Tool for Assessing the Toxicity of Microplastics, Heavy Metals, and Pesticides on Aquatic Invertebrates. *Int. J. Environ. Res. Public Health* **2022**, *19*, 16830. [[CrossRef](#)]
72. Ahmed, I.; Reshi, Q.M.; Fazio, F. The influence of the endogenous and exogenous factors on hematological parameters in different fish species: A review. *Aquac. Int.* **2020**, *28*, 869–899. [[CrossRef](#)]
73. Yousefi, M.; Shabunin, S.V.; Vatnikov, Y.A.; Kulikov, E.V.; Adineh, H.; Hamidi, M.K.; Hoseini, S.M. Effects of lavender (*Lavandula angustifolia*) extract inclusion in diet on growth performance, innate immunity, immune-related gene expression, and stress response of common carp, *Cyprinus carpio*. *Aquaculture* **2020**, *515*, 734588. [[CrossRef](#)]
74. Barathinivas, A.; Ramya, S.; Neethirajan, K.; Jayakumararaj, R.; Pothiraj, C.; Balaji, P.; Faggio, C. Ecotoxicological effects of pesticides on hematological parameters and oxidative enzymes in freshwater Catfish, *Mystus keletius*. *Sustainability* **2022**, *14*, 9529. [[CrossRef](#)]
75. Clark, N.J.; Shaw, B.J.; Handy, R.D. Low hazard of silver nanoparticles and silver nitrate to the haematopoietic system of rainbow trout. *Ecotoxicol. Environ. Saf.* **2018**, *152*, 121–131. [[CrossRef](#)] [[PubMed](#)]
76. Bayir, A.; Sirkecioglu, A.N.; Polat, H.; Aras, N.M. Biochemical profile of blood serum of siraz *Capoeta capoeta umbla*. *Comp. Clin. Pathol.* **2007**, *16*, 119–126. [[CrossRef](#)]
77. Yousefzadeh, F.; Khara, H. Changes in blood chemistry and hematological indices of *Capoeta capoeta gracilis* in relation to age, sex, and geographic location. *Comp. Clin. Pathol.* **2015**, *24*, 791–795. [[CrossRef](#)]
78. Imani, M.; Halimi, M.; Khara, H. Effects of silver nanoparticles (AgNPs) on hematological parameters of rainbow trout, *Oncorhynchus mykiss*. *Comp. Clin. Pathol.* **2015**, *24*, 491–495. [[CrossRef](#)]
79. Ololade, I.; Oginni, O. Toxic stress and hematological effects of nickel on African catfish, *Clarias gariepinus*, fingerlings. *J. Environ. Chem. Ecotoxicol.* **2010**, *2*, 014–019.
80. Barboza, L.G.A.; Vieira, L.R.; Guilhermino, L. Single and combined effects of microplastics and mercury on juveniles of the European seabass (*Dicentrarchus labrax*): Changes in behavioural responses and reduction of swimming velocity and resistance time. *Environ. Pollut.* **2018**, *236*, 1014–1019. [[CrossRef](#)]
81. Bojarski, B.; Witeska, M.J.E.S.; Research, P. Blood biomarkers of herbicide, insecticide, and fungicide toxicity to fish—A review. *Environ. Sci. Pollut. Res.* **2020**, *27*, 19236–19250. [[CrossRef](#)] [[PubMed](#)]
82. Lakra, K.C.; Mistri, A.; Banerjee, T.K.; Lal, B. Analyses of the health status, risk assessment and recovery response of the nutritionally important catfish *Clarias batrachus* reared in coal mine effluent-fed pond water: A biochemical, haematological and histopathological investigation. *Environ. Sci. Pollut. Res.* **2022**, *29*, 47462–47487. [[CrossRef](#)] [[PubMed](#)]
83. Joshi, P.; Bose, M.; Harish, D. Haematological changes in the blood of *Clarias batrachus* exposed to mercuric chloride. *J. Ecotoxicol. Environ. Monit.* **2002**, *12*, 119–122.
84. Dhara, K.; Saha, S.; Mukherjee, D.; Saha, N.C. Comparative acute toxicity of mercury to air breathing fish, *Channa gachua* (Ham.) and non-air breathing fish *Cyprinus carpio* (Linn.): Ethological and Haematological Consideration. *Indian J. Ecol.* **2021**, *48*, 1243–1253.
85. Mohamed, F.; Gad, N. Environmental pollution-induced biochemical changes in tissues of *Tilapia zillii*, *Solea vulgaris* and *Mugil capito* from Lake Qarun, Egypt. *Glob. Vet.* **2008**, *2*, 327–336.
86. Allen, T.; Singhal, R.; Rana, S. Resistance to oxidative stress in a freshwater fish *Channa punctatus* after exposure to inorganic arsenic. *Biol. Trace Elem. Res.* **2004**, *98*, 63–72. [[CrossRef](#)]
87. Jaheed, E. Study of Blood Serum Biochemical Profile and Pathological Changes in Haemonchosis Experimentally Induced in Goats. *Am. J. BioScience* **2021**, *9*, 95. [[CrossRef](#)]
88. Heeren, J.; Scheja, L. Metabolic-associated fatty liver disease and lipoprotein metabolism. *Mol. Metab.* **2021**, *50*, 101238. [[CrossRef](#)]
89. Belinskaia, D.A.; Voronina, P.A.; Batalova, A.A.; Goncharov, N.V. Serum Albumin. *Encyclopedia* **2020**, *1*, 65–75. [[CrossRef](#)]

90. Nematdoost Haghi, B.; Banaee, M. Effects of micro-plastic particles on paraquat toxicity to common carp (*Cyprinus carpio*): Biochemical changes. *Int. J. Environ. Sci. Technol.* **2017**, *14*, 521–530. [[CrossRef](#)]
91. Mahmoud, U.M.; Mekkawy, I.A.; Naguib, M.; Sayed, A.E.-D.H. Silver nanoparticle-induced nephrotoxicity in *Clarias gariepinus*: Physio-histological biomarkers. *Fish Physiol. Biochem.* **2019**, *45*, 1895–1905. [[CrossRef](#)] [[PubMed](#)]
92. Mansouri, B.; Maleki, A.; Davari, B.; Johari, S.A.; Shahmoradi, B.; Mohammadi, E.; Shahsavari, S. Histopathological effects following short-term coexposure of *Cyprinus carpio* to nanoparticles of TiO<sub>2</sub> and CuO. *Environ. Monit. Assess.* **2016**, *188*, 575. [[CrossRef](#)] [[PubMed](#)]
93. Murali, M.; Suganthi, P.; Athif, P.; Bukhari, A.S.; Mohamed, H.S.; Basu, H.; Singhal, R. Histological alterations in the hepatic tissues of Al<sub>2</sub>O<sub>3</sub> nanoparticles exposed freshwater fish *Oreochromis mossambicus*. *J. Trace Elem. Med. Biol.* **2017**, *44*, 125–131. [[CrossRef](#)] [[PubMed](#)]
94. Merola, C.; Fabrello, J.; Matozzo, V.; Faggio, C.; Iannetta, A.; Tinelli, A.; Crescenzo, G.; Amorena, M.; Perugini, M. Dinitroaniline herbicide pendimethalin affects development and induces biochemical and histological alterations in zebrafish early-life stages. *Sci. Total Environ.* **2022**, *828*, 154414. [[CrossRef](#)] [[PubMed](#)]
95. Vajargah, M.; Mohamadi Yalsuyi, A.; Hedayati, A.; Faggio, C. Histopathological lesions and toxicity in common carp (*Cyprinus carpio* L. 1758) induced by copper nanoparticles. *Microsc. Res. Tech.* **2018**, *81*, 724–729. [[CrossRef](#)] [[PubMed](#)]
96. Ravi, R.; Athisuyambulingam, M.; Kanagaraj, S.; Tresnakova, N.; Impellitteri, F.; Viswambaran, G.; Faggio, C. Impact of Chlorpyrifos on Cytopathological Indices in Mangrove Crab, *Episesarma tetragonum* (Fabricius). *Vet. Sci.* **2023**, *10*, 53. [[CrossRef](#)]
97. Jeyasree, J.; Bupesh, G.; Vasanth, S.; Beulah, J.P.J.; Pandian, K.; Anand, A.V.; Vijayakumar, T.S.; Narayanan, L. In-vivo toxicological (acute) characterization of bio-synthesized silver nanoparticles in *labeo rohita*. *Nano Biomed. Eng.* **2020**, *12*, 115–123. [[CrossRef](#)]
98. Govindasamy, R.; Rahuman, A.A. Histopathological studies and oxidative stress of synthesized silver nanoparticles in Mozambique tilapia (*Oreochromis mossambicus*). *J. Environ. Sci.* **2012**, *24*, 1091–1098. [[CrossRef](#)]
99. El Euony, O.I.; Elblehi, S.S.; Abdel-Latif, H.M.; Abdel-Daim, M.M.; El-Sayed, Y.S. Modulatory role of dietary *Thymus vulgaris* essential oil and *Bacillus subtilis* against thiamethoxam-induced hepatorenal damage, oxidative stress, and immunotoxicity in African catfish (*Clarias gariepinus*). *Environ. Sci. Pollut. Res.* **2020**, *27*, 23108–23128. [[CrossRef](#)]
100. Sula, E.; Aliko, V.; Marku, E.; Nuro, A.; Faggio, C. Evaluation of kidney histopathological alterations in Crucian Carp, *Carassius carassius*, from a pesticide and PCB-contaminated freshwater ecosystem, using light microscopy and organ index mathematical model. *Int. J. Aquat. Biol.* **2020**, *8*, 154–165.
101. Sula, E.; Aliko, V.; Pagano, M.; Faggio, C. Digital light microscopy as a tool in toxicological evaluation of fish erythrocyte morphological abnormalities. *Microsc. Res. Tech.* **2020**, *83*, 362–369. [[CrossRef](#)] [[PubMed](#)]
102. Vajargah, M.F.; Namin, J.I.; Mohsenpour, R.; Yalsuyi, A.M.; Prokić, M.D.; Faggio, C. Histological effects of sublethal concentrations of insecticide Lindane on intestinal tissue of grass carp (*Ctenopharyngodon idella*). *Vet. Res. Commun.* **2021**, *45*, 373–380. [[CrossRef](#)] [[PubMed](#)]
103. Plhalova, L.; Sehonova, P.; Blahova, J.; Doubkova, V.; Tichy, F.; Faggio, C.; Berankova, P.; Svobodova, Z. Evaluation of tramadol hydrochloride toxicity to juvenile zebrafish—Morphological, antioxidant and histological responses. *Appl. Sci.* **2020**, *10*, 2349. [[CrossRef](#)]
104. Carraschi, S.; Florêncio, T.; Ignácio, N.; Ikefuti, C.; Cruz, C.; Ranzani-Paiva, M.J.T. Hematological and histopathological assessment of pacu (*Piaractus mesopotamicus*) after treatment of pathogens with veterinary medicinal products. *Comp. Clin. Pathol.* **2017**, *26*, 105–114. [[CrossRef](#)]
105. Baldissera, M.D.; Souza, C.F.; Seben, D.; Sippert, L.R.; Salbego, J.; Marchesan, E.; Zanella, R.; Baldisserotto, B.; Golombieski, J. Gill bioenergetics dysfunction and oxidative damage induced by thiamethoxam exposure as relevant toxicological mechanisms in freshwater silver catfish *Rhamdia quelen*. *Sci. Total Environ.* **2018**, *636*, 420–426. [[CrossRef](#)]
106. Sales, C.F.; Dos Santos, K.P.E.; Rizzo, E.; de Azambuja Ribeiro, R.I.M.; Dos Santos, H.B.; Thomé, R.G. Proliferation, survival and cell death in fish gills remodeling: From injury to recovery. *Fish Shellfish Immunol.* **2017**, *68*, 10–18. [[CrossRef](#)]
107. Vieira, L.; Saldanha, A.A.; Moraes, A.M.; de Oliveira, F.M.; Lopes, D.O.; de Oliveira Barbosa, L.A.; de Azambuja Ribeiro, R.I.M.; Thomé, R.G.; Dos Santos, H.B.; Villar, J.A.F.P. 21-Benzylidene digoxin, a novel digoxin hemi-synthetic derivative, presents an anti-inflammatory activity through inhibition of edema, tumour necrosis factor alpha production, inducible nitric oxide synthase expression and leucocyte migration. *Int. Immunopharmacol.* **2018**, *65*, 174–181. [[CrossRef](#)]
108. Griffith, R.J.; Hyndman, K.; Denslow, N.D.; Barber, D.S. Comparison of molecular and histological changes in zebrafish gills exposed to metallic nanoparticles. *Toxicol. Sci.* **2009**, *107*, 404–415. [[CrossRef](#)]
109. Griffith, R.J.; Luo, J.; Gao, J.; Bonzongo, J.C.; Barber, D.S. Effects of particle composition and species on toxicity of metallic nanomaterials in aquatic organisms. *Environ. Toxicol. Chem.* **2008**, *27*, 1972–1978. [[CrossRef](#)]
110. Kumar, N.; Jeena, N.; Gangola, S.; Singh, H. Phytoremediation facilitating enzymes: An enzymatic approach for enhancing remediation process. In *Smart Bioremediation Technologies*; Elsevier: Amsterdam, The Netherlands, 2019; pp. 289–306.
111. Brusle, J.; Anadon, G.G. The structure and function of fish liver. In *Fish Morphology*; Routledge: Abingdon, UK, 2017; pp. 77–93.
112. Paulino, M.G.; Tavares, D.; Terezan, A.P.; Sakuragui, M.M.; Pesenti, E.; Giani, A.; Cestari, M.M.; Fernandes, J.B.; Fernandes, M.N. Biotransformations, antioxidant system responses, and histopathological indexes in the liver of fish exposed to cyanobacterial extract. *Environ. Toxicol. Chem.* **2020**, *39*, 1041–1051. [[CrossRef](#)]
113. Saud Alarifi, D.A.; Al-Doaiss, A.A.; Ali, B.A.; Ahmed, M.; Al-Khedhairi, A.A. Histologic and apoptotic changes induced by titanium dioxide nanoparticles in the livers of rats. *Int. J. Nanomed.* **2013**, *8*, 3937.

114. Paunovic, J.; Vucevic, D.; Radosavljevic, T.; Pantic, S.; Nikolovski, D.; Dugalic, S.; Pantic, I. Effects of metallic nanoparticles on physiological liver functions. *Rev. Adv. Mater. Sci.* **2017**, *49*, 123–128.
115. Baldissera, M.D.; Souza, C.F.; Descovi, S.N.; Zanella, R.; Prestes, O.D.; da Silva, A.S.; Baldisserotto, B. Organophosphate pesticide trichlorfon induced neurotoxic effects in freshwater silver catfish *Rhamdia quelen* via disruption of blood-brain barrier: Implications on oxidative status, cell viability and brain neurotransmitters. *Comp. Biochem. Physiol. Part C: Toxicol. Pharmacol.* **2019**, *218*, 8–13. [[CrossRef](#)] [[PubMed](#)]
116. Serafini, S.; de Freitas Souza, C.; Baldissera, M.D.; Baldisserotto, B.; Segat, J.C.; Baretta, D.; Zanella, R.; da Silva, A.S. Fish exposed to water contaminated with eprinomectin show inhibition of the activities of AChE and Na<sup>+</sup>/K<sup>+</sup>-ATPase in the brain, and changes in natural behavior. *Chemosphere* **2019**, *223*, 124–130. [[CrossRef](#)] [[PubMed](#)]
117. Tang, J.; Xiong, L.; Wang, S.; Wang, J.; Liu, L.; Li, J.; Yuan, F.; Xi, T. Distribution, translocation and accumulation of silver nanoparticles in rats. *J. Nanosci. Nanotechnol.* **2009**, *9*, 4924–4932. [[CrossRef](#)]
118. Faedmaleki, F.; Shirazi, F.H.; Salarian, A.-A.; Ashtiani, H.A.; Rastegar, H. Toxicity effect of silver nanoparticles on mice liver primary cell culture and HepG2 cell line. *Iran. J. Pharm. Res.* **2014**, *13*, 235.
119. Aghamirakimi, S.; Mashinchian Moradi, A.; Sharifpour, I.; Jamili, S.; Ghavam Mostafavi, P. Sublethal effects of copper nanoparticles on the histology of gill, liver and kidney of the Caspian roach, *Rutilus rutilus caspicus*. *Global J. Environ. Sci. Manag.* **2017**, *3*, 323–332. [[CrossRef](#)]
120. Yazdanparast, T.; Sharifpour, I.; Soltani, M.; Esfahani, H.K. Evaluation of silver retention in different organs of zebrafish (*Danio rerio*) fed diet supplemented with silver nanoparticles. *Int. J. Eng. Res.* **2016**, *5*, 269–274.
121. Naguib, M.; Mahmoud, U.M.; Mekawy, I.A.; Sayed, A.E.-D.H. Hepatotoxic effects of silver nanoparticles on *Clarias gariepinus*; Biochemical, histopathological, and histochemical studies. *Toxicol. Rep.* **2020**, *7*, 133–141. [[CrossRef](#)]
122. Grigore, M.E.; Biscu, E.R.; Holban, A.M.; Gestal, M.C.; Grumezescu, A.M. Methods of synthesis, properties and biomedical applications of CuO nanoparticles. *Pharmaceuticals* **2016**, *9*, 75. [[CrossRef](#)]
123. Ostaszewska, T.; Chojnacki, M.; Kamaszewski, M.; Sawosz-Chwalibóg, E. Histopathological effects of silver and copper nanoparticles on the epidermis, gills, and liver of Siberian sturgeon. *Environ. Sci. Pollut. Res.* **2016**, *23*, 1621–1633. [[CrossRef](#)] [[PubMed](#)]
124. Avci, A.; Kaçmaz, M.; Durak, İ. Peroxidation in muscle and liver tissues from fish in a contaminated river due to a petroleum refinery industry. *Ecotoxicol. Environ. Saf.* **2005**, *60*, 101–105. [[CrossRef](#)] [[PubMed](#)]
125. Mela, M.; Randi, M.; Ventura, D.; Carvalho, C.; Pelletier, E.; Ribeiro, C.O. Effects of dietary methylmercury on liver and kidney histology in the neotropical fish *Hoplias malabaricus*. *Ecotoxicol. Environ. Saf.* **2007**, *68*, 426–435. [[CrossRef](#)] [[PubMed](#)]
126. Velma, V.; Tchounwou, P.B. Chromium-induced biochemical, genotoxic and histopathologic effects in liver and kidney of goldfish, *Carassius auratus*. *Mutat. Res./Genet. Toxicol. Environ. Mutagen.* **2010**, *698*, 43–51. [[CrossRef](#)] [[PubMed](#)]
127. Jerome, F.C.; Hassan, A.; Omoniyi-Esan, G.O.; Odujoko, O.O.; Chukwuka, A.V. Metal uptake, oxidative stress and histopathological alterations in gills and hepatopancreas of *Callinectes amnicola* exposed to industrial effluent. *Ecotoxicol. Environ. Saf.* **2017**, *139*, 179–193. [[CrossRef](#)] [[PubMed](#)]
128. Santos, D.S.; França, F.M.; Marcantonio, A.S.; Viriato, C.; Fonseca, A.M.C.R.P.; Pedroso, C.B.; Ferreira, C.M. Histopathological changes in the gills of zebrafish (*Danio rerio*) and bullfrog tadpoles (*Lithobates catesbeianus*) caused by the use of formaldehyde. *Braz. J. Anim. Environ. Res.* **2021**, *4*, 3832–3847. [[CrossRef](#)]

**Disclaimer/Publisher’s Note:** The statements, opinions and data contained in all publications are solely those of the individual author(s) and contributor(s) and not of MDPI and/or the editor(s). MDPI and/or the editor(s) disclaim responsibility for any injury to people or property resulting from any ideas, methods, instructions or products referred to in the content.