



## Case Report

# Mucin-Producing Lobular Breast Carcinoma Metastasis to an Ovarian Fibroma: Histopathological and Immunohistochemical Analysis of a Rare Case and Literature Review

Alexandra Corina Faur <sup>1</sup>, Camelia Vidița Gurban <sup>2,\*</sup> , Ecaterina Dăescu <sup>1</sup>, Răzvan Vlad Tîrziu <sup>3</sup>, Daniela Cornelia Lazăr <sup>4</sup> and Laura Andreea Ghenciu <sup>5</sup> 

<sup>1</sup> Department I, Discipline of Anatomy and Embryology, “Victor Babes” University of Medicine and Pharmacy, 300041 Timisoara, Romania; faur.alexandra@umft.ro (A.C.F.); daescu.ecaterina@umft.ro (E.D.)

<sup>2</sup> Department IV Biochemistry and Pharmacology, Discipline of Biochemistry, “Victor Babes” University of Medicine and Pharmacy, 300041 Timisoara, Romania

<sup>3</sup> Department IX, Surgery I, Discipline of Surgical Semiology I and Thoracic Surgery, “Victor Babes” University of Medicine and Pharmacy, 300041 Timisoara, Romania; razvantarziu@umft.ro

<sup>4</sup> Department V Internal Medicine I, Discipline of Internal Medicine IV, “Victor Babes” University of Medicine and Pharmacy, 300041 Timisoara, Romania; lazar\_daniela@yahoo.com

<sup>5</sup> Department III, Discipline of Pathophysiology, “Victor Babes” University of Medicine and Pharmacy, 300041 Timisoara, Romania; bolintineanu.laura@umft.ro

\* Correspondence: gurban.camelia@umft.ro; Tel./Fax: +40-256-216-510

**Abstract:** Breast cancer stands as the primary cause of cancer-related mortality among women worldwide, often presenting with distant metastases upon diagnosis. Ovarian metastases originating from breast cancer represent a range of 3–30% of all ovarian neoplasms. Case Report: Herein, we present the histopathological, histochemical, and immunohistochemical findings of a rare case involving mucin-producing lobular breast carcinoma metastasizing to an ovarian fibroma in an 82-year-old female previously diagnosed with lobular breast carcinoma. Histopathological examination of the excised tissues revealed a biphasic neoplasm characterized by tumor cells expressing AE-1/AE-3 cytokeratin, mammaglobin, GCDFP-15, inhibin, and calretinin. Positive mucin staining was observed using histochemical techniques, and reticulin fibers were demonstrated using the Gordon–Sweets technique. A final diagnosis of mucin-producing lobular breast carcinoma metastatic to a benign ovarian fibroma was rendered. Conclusion: The occurrence of metastatic breast carcinoma overlaid on an ovarian tumor represents a rare and diagnostically challenging scenario.

**Keywords:** breast cancer; lobular carcinoma; ovarian metastases; ovarian metastases from non-gynecologic primary sites; tumor-to-tumor metastases



**Citation:** Faur, A.C.; Gurban, C.V.; Dăescu, E.; Tîrziu, R.V.; Lazăr, D.C.; Ghenciu, L.A. Mucin-Producing Lobular Breast Carcinoma Metastasis to an Ovarian Fibroma: Histopathological and Immunohistochemical Analysis of a Rare Case and Literature Review. *Diagnostics* **2024**, *14*, 953. <https://doi.org/10.3390/diagnostics14090953>

Academic Editor: Edward J. Pavlik

Received: 20 March 2024

Revised: 22 April 2024

Accepted: 28 April 2024

Published: 30 April 2024



**Copyright:** © 2024 by the authors. Licensee MDPI, Basel, Switzerland. This article is an open access article distributed under the terms and conditions of the Creative Commons Attribution (CC BY) license (<https://creativecommons.org/licenses/by/4.0/>).

## 1. Introduction

Metastases from remote primaries to the ovary are an uncommon condition. Approximately 3–30% of ovarian tumors are metastases and originate mainly from the gastrointestinal tract [1]. Metastases from tumors of the breast, pancreas, endometrium, bladder, lungs, and kidney are also reported in a small number of cases [1–11]. Most ovarian metastases are from extragenital organs, with 6.7% being breast carcinomas [4]. In rare cases, reports of tumor metastasis in an ovarian tumor or concurrent tumors with ovarian involvement are to be found [12–19]. Accounting for 5–15% of all breast cancers, lobular breast carcinomas (ILCs) are the second most common histological type. Invasive breast carcinoma sites of metastases include the bones, brain, liver, lungs, and lymph nodes [6,20–22]. Unusual locations like the gastrointestinal tract, uterus, ovary, peritoneum, retroperitoneum, bladder, spleen, and cervix can be involved in the metastatic spread of ILC [23–29]. Histologically, ILC has distinct morphologic features represented by round tumor cells lacking cohesion arranged in files, cords, and single cells that can also form targetoid patterns. The stromal

response in ILC is minimal, and necrosis is uncommon. Morphological variants of ILC are classic lobular carcinoma, solid, alveolar, tubulolobular, pleomorphic, histiocytoid, apocrine, signet ring, and mixed [30]. Also, variants of ILC with mucin production have been described [30–33].

Fibromas constitute common benign stromal ovarian sex-cord tumors, accounting for 1–4% of all ovarian neoplasms [34–36]. Ovarian fibromas typically present as unilateral, well-circumscribed solid masses. Histologically, these tumors consist of spindle cells with oval nuclei and scant cytoplasm. Due to their morphological resemblance, a differential diagnosis must include lesions such as thecomas, diffuse adult granulosa-cell tumors, massive ovarian edema, and fibrosarcomas. Clinically, consideration should be given to Meigs syndrome, characterized by ascites and pleural effusions in the presence of a benign ovarian mass, such as fibromas or fibroid tumors [37–39].

We hereby present a rare case of lobular breast carcinoma metastasizing to an ovarian fibroma.

## 2. Materials and Methods—Case Report

### 2.1. Presentation and Clinical Characteristics

An 82-year-old female with a previous diagnosis of lobular breast carcinoma presented to the Surgery Department of City Hospital Timisoara complaining of abdominal distension and pain. A right-side ovarian tumor was investigated ultrasonographically, and the clinician made a right ovarian tumor diagnosis. The laboratory data showed elevated values of cancer antigen 125 (CA-125) and human epididymis protein (HE-4) with a 95% ROMA score (risk of ovarian malignancy algorithm). Because of the high likelihood of malignancy, the operation was recommended. The clinical test results are summarized in Table 1.

**Table 1.** Tumor markers values.

Marker	Results	Reference Value (Postmenopausal) [39–41]
CA-125	751 U/L	<46 U/L
HE-4	381 pmol/L	<140 pmol/L
ROMA Score	95%	>2.99 (high risk for ovarian cancer)

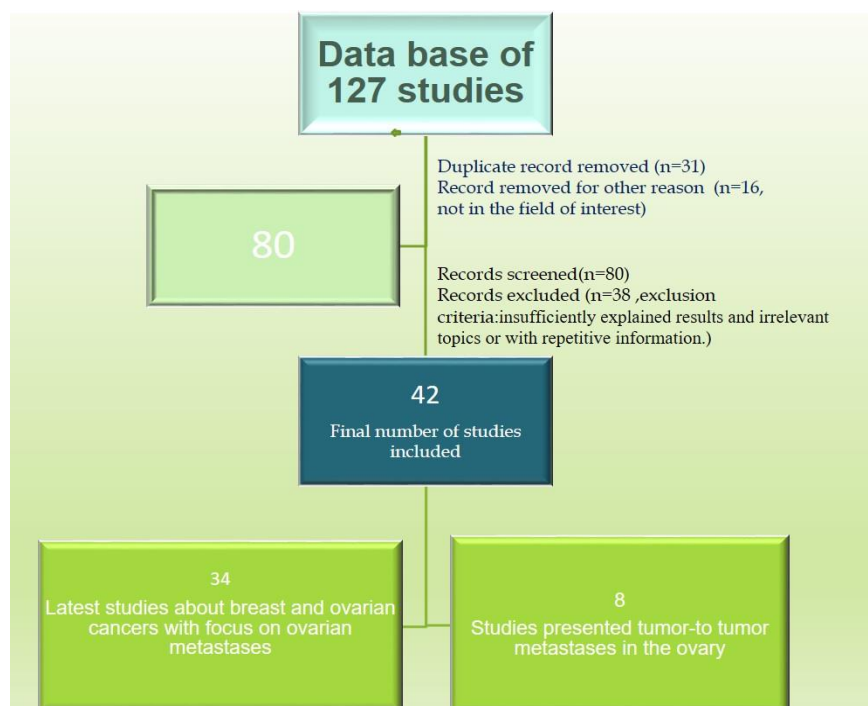
CA-125 = cancer antigen 125, HE-4 = human epididymis protein, ROMA score = risk of ovarian malignancy algorithm.

### 2.2. Literature Data Investigation

We conducted a comprehensive review of recent English-language literature regarding ovarian tumors, lobular breast carcinoma, and tumor-to-tumor metastasis. Our review encompassed the utilization of the PubMed electronic database alongside other relevant sources. We used a set of predetermined keywords, including “breast cancer”, “lobular carcinoma”, “ovarian metastases”, “ovarian metastases from non-gynecologic primary sites”, and “tumor-to-tumor metastases”. We meticulously overviewed a database comprising 127 studies addressing breast and ovarian neoplasms, comprising both individual studies and reviews.

Subsequently, we curated this database, eliminating duplicate entries and articles falling outside the scope of our investigation, resulting in a refined dataset of 80 relevant papers. Publications lacking sufficiently explained results, discussing irrelevant topics, or presenting redundant information were systematically excluded from further consideration. Ultimately, 42 articles met our inclusion criteria.

We categorized the remaining articles into two distinct datasets. The first dataset comprised a study investigating breast cancer (both primary and metastatic tumors) and ovarian cancer, with a specific focus on elucidating current insights into ovarian metastases. The second dataset comprised reports documenting tumor metastasis within an ovarian tumor. The algorithm employed for the selection of articles is explained in Figure 1.



**Figure 1.** Algorithm used for article selection; n = number of articles.

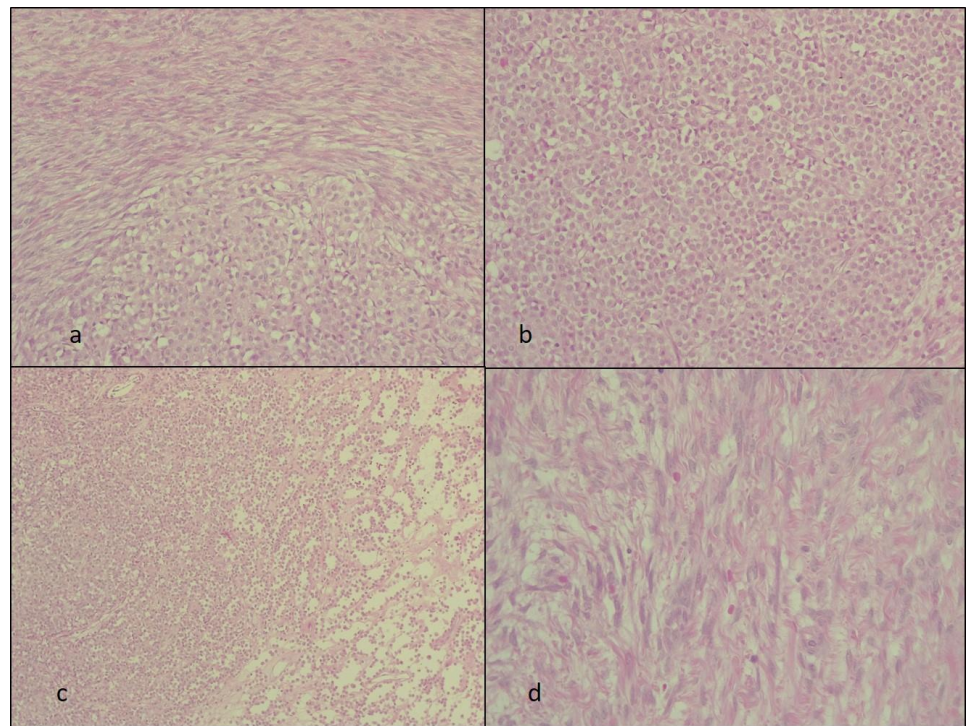
### 3. Results

#### *Gross and Microscopic Evaluation*

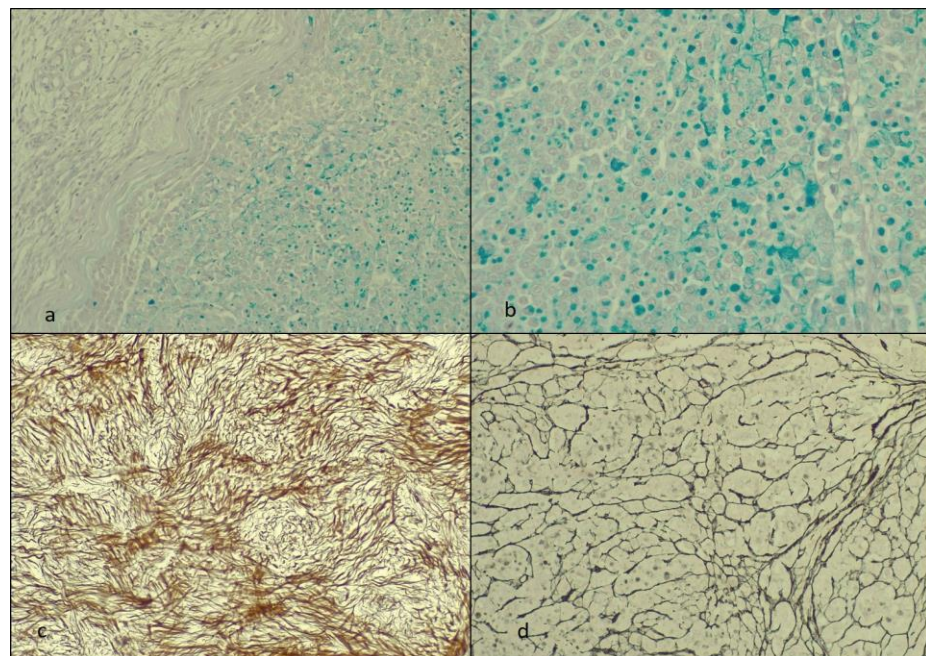
The patient had undergone a bilateral salpingo-oophorectomy. Further postoperative gross and microscopic examination of the excised tissues was made. On gross examination, the resected right specimen showed a 10/8/7 cm right ovarian mass well circumscribed with a tan-yellow to brown aspect on the cut surface. Sections from this mass were harvested and investigated histopathologically. The 4  $\mu$ m thick formalin-fixed paraffin-embedded tissue samples were stained with hematoxylin and eosin (HE). Additional slides from the ovarian tumor were immunohistochemically stained with AE-1/AE-3 cytokeratin, mammaglobin, GCDFP-15, inhibin, and calretinin. In addition, we used histological techniques: periodic acid–Schiff alcian blue (PAS-AA) for mucins and the Gordon–Sweets technique for reticulin fibers.

The HE slides revealed a biphasic tumor with circumscribed areas of round tumor cells bordered by variable cellular spindle cells with focal fascicular growth. The fusiform cells had bland spindle to ovoid nuclei and scant cytoplasm resembling the stroma of the ovarian cortex. The round cells were arranged in solid areas and only focally in cords or sheets. These cells were small, monomorphic, and without marked atypia, necrosis, or atypical mitoses. The stromal responses in the round cell areas lacked desmoplastic reactions (Figure 2).

The PAS-AA revealed in the round cells tumor areas of positive (blue) material in the cytoplasm of these cells but also focally in the adjacent stroma (extracellular). The reticulin highlighted the aspect of the disrupted architecture of the stroma in the round-shaped cell areas and underlined the areas with the spindle cells. The fibroma areas had a pericellular reticulin staining pattern (Figure 3).

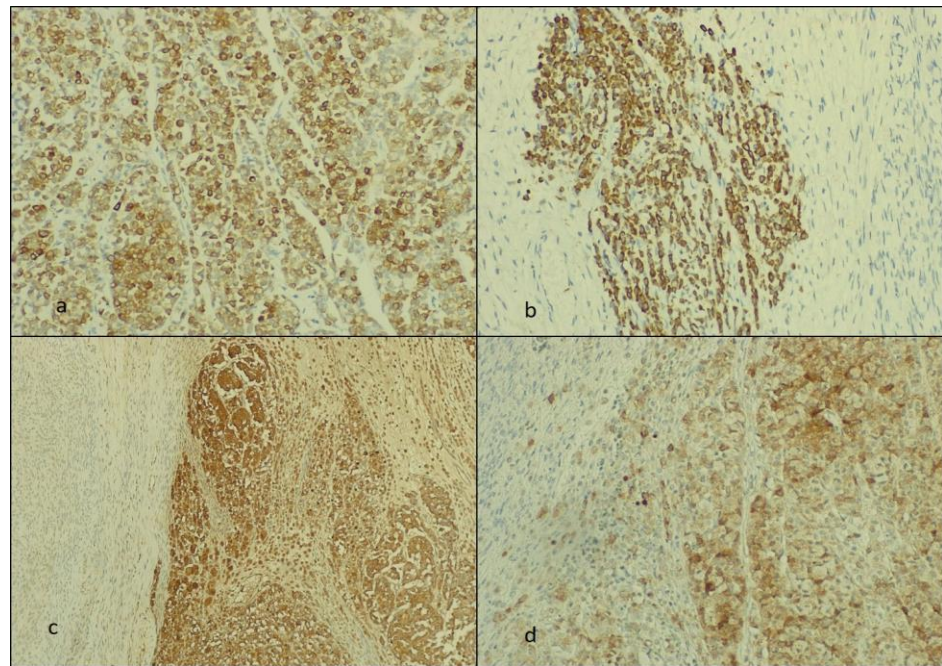


**Figure 2.** The hematoxylin and eosin staining. The HE slides with the biphasic tumor showing (a) the tumor-in-tumor aspect objective (at  $\times 40$  Ob.), (b,c) the ILC metastasis in detail at  $\times 20$  and  $\times 40$  Ob., respectively, and (d) the spindle cells fibroma area (at  $\times 40$  Ob.). Ob = the microscope objective.

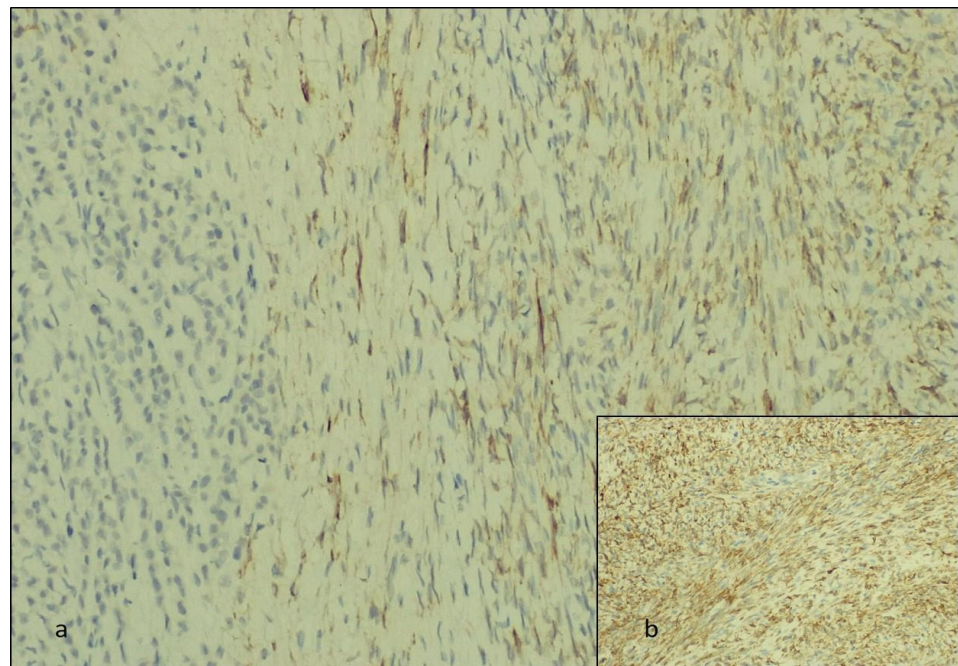


**Figure 3.** The staining with PAS-AA and reticulin: (a,b) the PAS-AA reaction at  $\times 20$  and  $\times 40$  Ob., respectively; (c,d) reticulin stain (at  $\times 20$  and  $\times 40$  Ob., respectively) with (c) the fibroma areas and (d) the ILC.

We studied the biphasic tumor areas immunohistochemically and observed that the round cells were positive for AE-1/AE-3 cytokeratin, mammaglobin, and GCDFP-15, and the fusiform tumor cells stained for inhibin and calretinin (Figures 4 and 5).



**Figure 4.** The immunohistochemically staining: (a,b) the AE-1/AE-3-positive ILC metastasis at  $\times 40$  and  $\times 20$  Ob., respectively; (c) the mammaglobin-positive cells of the ILC and (d) GCDFP-15-positive ILC areas at  $\times 20$  and  $\times 40$  Ob., respectively.



**Figure 5.** The immunohistochemical staining. The fibroma areas are positive for (a) inhibin and (b) calretinin (at  $\times 40$  Ob.), respectively.

#### 4. Discussion

Ovarian metastases from breast cancer account for 3–30% of all ovarian ovarian neoplasms [1–11]. We identified both lobular and invasive ductal breast carcinoma studies with metastasis to the ovary, but the cases presented in the current literature data were few. Brigrorie V et al. identified 29 breast carcinomas with ovarian metastases without specifying the CA-125 level [1]. Pimentel C et al. presented 28 such cases with a mean value of 488

and only 9 cases with a CA-125 level higher than their reference value of 35 U/L [5]. Zhang JJ et al. reported 6 breast tumors metastatic in an ovary from 177 tumors identified, but the histological type was not specified, and the CA-125 level was higher than 35 U/L in 65% of the cases included in their study [7]. In the rest of the analyzed studies, isolated cases of ovarian metastases of breast lobular carcinoma or tumors with primary localization in other organs were reported [2–4,6,8–11]. The types of primary tumors metastatic to the ovary, their incidence, CA-125 levels, and the number of cases identified in the literature database are summarized in Table 2.

**Table 2.** Summary of the studies reporting ovarian metastasis in the English-language literature.

References	Type of Study	Ovarian Metastases: Primary Sites (Histopathological Diagnosis of the Primary Tumor and/or Number of Cases)	CA-125 Levels	Number of Cases
Bigorie, V.; et al. [1]	Retrospective	Breast (16 cases with invasive ductal carcinoma (IDC), 12 ILC and 1 unknown)	NS	29
Akizava, Y.; et al. [2]	Case report	Breast (bilateral carcinoma ILC and IDC)	692 U/mL	1
Yamaguchi, T.; et al. [3]	Case report	Gastrointestinal tract (gastrointestinal stromal tumor)	818 U/L	1
Makris, G.M.; et al. [4]	Case report	Breast (ILC)	78 UI/L	1
Pimentel, C.; et al. [5]	Retrospective	Breast cancer (17 ILC, 7 IDC, 2 mixed ILC and IDC), 2 different histology	488 IU/L mean value (9 cases with >35)	28
Wong, Y.M.; et al. [6]	Retrospective	Breast (ILC)	NS	NS
Zhang, J.J.; et al. [7]	Retrospective	Colorectal (68), stomach (61), appendix (12), biliary tract (7), pancreas (7), breast (6), small intestine (5), lung (3), bladder (2), unknown sites (6)	>35 U/L in 65% of the patients	177
Kemps, G.P.; et al. [8]	Case report	Colon (adenocarcinoma not otherwise specified)	18 kU/L	1
Porfirys, O.; et al. [9]	Case report	Kidney (clear-cell renal cell carcinoma)	103.3 U/mL	1
Li, Z.; et al. [10]	Retrospective	Pancreas (5 cases with pancreatic ductal adenocarcinoma, 2 cases with pancreatic cystadenocarcinoma)	2 patients with elevated values -NS	7
Wang, S.D.; et al. [11]	Case report	Pancreas (pancreas mucinous adenocarcinoma)	412 U/L	NS

ILC = invasive lobular carcinoma, IDC = invasive ductal carcinoma, NS = not specified.

Invasive ductal carcinoma, not otherwise specified, stands as the predominant malignant breast tumor type. However, ILC of the breast, characterized by unpredictable behavior, is more prone to multifocal and distant metastases. The loss of the adhesion molecule E-cadherin, a hallmark of ILC, is implicated in the dissemination of tumor cells to distant sites and the occurrence of bilateralism. Metastases from breast ILCs have been documented in the bones, lungs, pleura, soft tissue, and liver [1–11,20–29].

The gastrointestinal tract represents a metastatic site in 6–18% of ILC cases, with the stomach being the most frequently affected site, followed by the colon and rectum [29]. Furthermore, metastases to the genital tract, including the uterus, cervix, and ovary, have been reported [25,26].

Ovarian fibromas typically present in middle-aged postmenopausal women and can simulate malignant tumors when associated with pleural effusions or ascites, posing diagnostic challenges preoperatively. Histologically, fibromas often resemble leiomy-

omas [34,36,42,43]. Additionally, while elevated levels of CA-125 are rare in fibromas, some studies suggest that mechanical stimulation of the peritoneum in the presence of ascites can result in elevated CA-125 levels, potentially leading to misdiagnosis of malignant ovarian tumors. Rare instances have been reported wherein fibromas spread and adhere to adjacent tissues, resulting in fatal outcomes [35]. Moreover, normal serum CA-125 levels are observed in up to 35% of cases of ovarian metastases from non-gynecological neoplasms [8].

In this study, we present a case of ILC metastasizing to an ovarian fibroma. This case posed diagnostic challenges as both breast tumors and primary ovarian tumors can coexist. In our patient, a prior diagnosis of ILC was compounded by elevated CA-125 levels and a ROMA score indicating an increased risk of ovarian cancer development.

Studies show that patients with a history of breast cancer are more predisposed to develop primary ovarian tumors [9]. The likelihood incidence ratio of a primary ovarian tumor to metastasis of a breast neoplasm is 7:1 in a 12-year retrospective study [43]. Also, less than 10% of breast cancer patients have clinical signs of distant metastasis at the moment of the initial diagnosis [9]. Women with hereditary conditions and BRCA-1 and BRCA-2 mutations have a higher risk of developing both primary ovarian and breast tumors [4]. Also, there are therapeutic implications. The primary ovarian cancer treatment is surgical debulking, but the optimal treatment for ovarian metastasis from other primary sites has not been established [7]. In the analyzed case, the morphological characteristics of the tumor cells within the areas of metastatic involvement closely resembled the histopathological profile of lobular carcinoma of the breast, exhibiting pathognomonic features identifiable through standard staining techniques. Various staining techniques, such as hematoxylin and eosin and PAS-AA [44], are commonly employed for diagnosing metastasis to the ovaries, aiding in the accurate identification of abnormal cells. To ascertain the cellular lineage and primary tumor site within the mammary gland, immunolabeling techniques were employed. Positive immunoreactivity for cytokeratin confirmed the epithelial origin of the tumor, while the presence of GCDPF-15 and mammaglobin indicated the breast as the primary tumor site. Furthermore, to distinguish the fibroma from other similar sex-cord stromal tumors, staining for reticulin fibers was utilized. In fibromas, a pericellular reticulin staining pattern is typically observed, contrasting with the varied patterns observed in tumors such as diffuse adult granulosa cell tumors, smooth muscle tumors, or mesenchymal tumors [45]. Disruption of reticulin fiber architecture, similar to that observed in areas of metastatic lobular carcinoma, is indicative of malignancy.

During immunohistochemistry, a diagnostic technique that may use several specific antibodies to detect proteins [46], the fibroma exhibited positive staining for inhibin and calretinin. Recent investigations have proposed the utility of inhibin and calretinin in diagnosing ovarian sex-cord stromal tumors, with fibromas demonstrating positivity for these markers in approximately 25–30% of cases studied [37,47,48].

The morphological characteristics of the metastatic lobular breast carcinoma were further elucidated through PAS-AA staining. Notably, the tumor cells exhibited blue staining of intra- and extracellular material suggestive of mucin production. While intracellular and extracellular mucin secretion is a recognized feature of lobular breast carcinoma, the identification of such mucins within the metastatic tumor is a rare occurrence [30,31,33,49]. Some studies suggest that mucin production may signify aggressive behavior in lobular carcinoma [31]. In the case under consideration, mucinous material was predominantly localized within the cytoplasm of tumor cells, with focal extracellular distribution.

Another unique aspect in our case is tumor-to-tumor metastasis (TTM). Our second dataset included reports of tumor metastasis in an ovarian tumor. TTMs turned out to be a rare finding. By consulting the English-language literature data, we have identified only eight TTMs, with one case of ILC metastatic to a sex-cord stromal tumor. Strobel et al. described a triple-negative ILC metastasis to an ovarian fibrothecoma [19]. Cases of follicular lymphoma, appendiceal adenocarcinoma, squamous-cell carcinoma, and breast ILC metastatic to ovarian mature teratoma have been described [12,14,50].

## 5. Conclusions

We report a rare case of tumor-to-tumor metastasis of an uncommon mucin-producing ILC. To the best of our knowledge, this is the first case of TTM due to lobular carcinoma of the breast to an ovarian fibroma. Awareness of this phenomenon is important for the therapeutic management of the patient. If for primary ovarian masses, the treatment is surgical, for TTMs, the therapeutic approach should be made by a multidisciplinary medical team.

**Supplementary Materials:** The following supporting information can be downloaded at <https://www.mdpi.com/article/10.3390/diagnostics14090953/s1>. The ethical approval document E-628/31.01.2024.

**Author Contributions:** Conceptualization, A.C.F. and C.V.G.; methodology, D.C.L. and E.D.; investigation L.A.G. and R.V.T.; writing—original draft preparation A.C.F.; writing—review and editing L.A.G. and C.V.G. All authors have read and agreed to the published version of the manuscript.

**Funding:** We would like to acknowledge “VICTOR BABES” UNIVERSITY OF MEDICINE AND PHARMACY TIMISOARA for their support in covering the costs of publication for this research paper.

**Institutional Review Board Statement:** This study was conducted in accordance with the Declaration of Helsinki and approved by the Institutional Review Board of City Hospital Timisoara, Approval No. E-628/31.01.2024 (Supplementary Materials—the ethical approval document).

**Informed Consent Statement:** Written consent has been obtained from the patient and is included in the patient’s hospital records.

**Data Availability Statement:** The data presented in this study are not publicly available due to privacy.

**Conflicts of Interest:** The authors declare no conflicts of interest.

## References

1. Bigorie, V.; Morice, P.; Duvillard, P.; Antoine, M.; Cortez, A.; Flejou, J.F.; Uzan, S.; Darai, E.; Barranger, E. Ovarian metastases from breast cancer: Report of 29 cases. *Cancer* **2010**, *116*, 799–804. [[CrossRef](#)] [[PubMed](#)]
2. Akizawa, Y.; Kanno, T.; Horibe, Y.; Shimizu, Y.; Nouguchi, E.; Yamamoto, T.; Okamoto, T.; Nagashima, Y.; Tabata, T. Ovarian metastasis from breast cancer mimicking a primary ovarian neoplasm: A case report. *Mol. Clin. Oncol.* **2021**, *15*, 135. [[CrossRef](#)] [[PubMed](#)]
3. Yamaguchi, T.; Kinoshita, J.; Saito, H.; Shimada, M.; Terai, S.; Moriyama, H.; Okamoto, K.; Nakamura, K.; Tajima, H.; Ninomiya, I.; et al. Gastrointestinal stromal tumor metastasis to the ovary: A case report. *SAGE Open Med. Case Rep.* **2021**, *9*, 2050313X211012511. [[CrossRef](#)] [[PubMed](#)]
4. Makris, G.M.; Marinelis, A.; Battista, M.; Chrelias, C.; Papantoniou, N. An ovarian mass after breast cancer: Metachronous carcinoma or metastasis? A case report. *Int. J. Surg. Case Rep.* **2017**, *31*, 106–108. [[CrossRef](#)] [[PubMed](#)]
5. Pimentelm, C.; Becquet, M.; Lavoue, V.; Henno, S.; Leveque, J.; Ouldamer, L. Ovarian Metastases from Breast Cancer: A Series of 28 Cases. *Anticancer Res.* **2016**, *36*, 4195–4200.
6. Wong, Y.M.; Jagmohan, P.; Goh, Y.G.; Putti, T.C.; Ow, S.G.W.; Thian, Y.L.; Pillay, P. Infiltrative pattern of metastatic invasive lobular breast carcinoma in the abdomen: A pictorial review. *Insights Imaging* **2021**, *12*, 181. [[CrossRef](#)] [[PubMed](#)]
7. Zhang, J.J.; Cao, D.Y.; Yang, J.X.; Shen, K. Ovarian metastasis from nongynecologic primary sites: A retrospective analysis of 177 cases and 13-year experience. *J. Ovarian Res.* **2020**, *13*, 128. [[CrossRef](#)]
8. Kemps, P.G.; Bol, M.; Steller, E.J.A.; de Pont, L.M.H.; Holterhues, C.; van Gerven, L.; Kolkman, W. Colon carcinoma presenting as ovarian metastasis. *Radiol. Case Rep.* **2021**, *16*, 2799–2803. [[CrossRef](#)]
9. Porfyris, O.; Alexandrou, P.; Masaoutis, C.; Nikolakakos, F. Ovarian metastasis of renal cell carcinoma: Clinical and pathological presentation of a case. *Turk. J. Urol.* **2019**, *45*, 150–153. [[CrossRef](#)]
10. Li, Z.; Zhou, X.; Zhao, B.; Zheng, Z.; Qiun, C.; Liu, X.; Xue, H.; Wang, W. Pancreatic cancer with ovarian metastasis: Cases report and literature review. *J. Pancreatol.* **2023**, *6*, 34–39. [[CrossRef](#)]
11. Wang, S.D.; Zhu, L.; Wu, H.W.; Dai, M.H.; Zhao, Y.P. Pancreatic cancer with ovarian metastases: A case report and review of the literature. *World J. Clin. Cases* **2020**, *8*, 5380–5388. [[CrossRef](#)] [[PubMed](#)]
12. Hackethal, A.; Brueggmann, D.; Bohlmann, M.K.; Franke, F.E.; Tinneberg, H.R.; Münstedt, K. Squamous-cell carcinoma in mature cystic teratoma of the ovary: Systematic review and analysis of published data. *Lancet Oncol.* **2008**, *9*, 1173–1180. [[CrossRef](#)] [[PubMed](#)]
13. Kirova, Y.M.; Feuilhade, F.; de Baecque-Fontaine, C.; Le Bourgeois, J.P. Metastasis of a breast carcinoma in a mature teratoma of the ovary. *Eur. J. Gynaecol. Oncol.* **1999**, *20*, 223–225.



14. Yano, M.; Katoh, T.; Hamaguchi, T.; Kozawa, E.; Hamada, M.; Nagata, K.; Yasuda, M. Tumor-to-tumor metastasis from appendiceal adenocarcinoma to an ovarian mature teratoma, mimicking malignant transformation of a teratoma: A case report. *Diagn. Pathol.* **2019**, *14*, 88. [[CrossRef](#)]
15. Santos, F.; Oliveira, C.; Caldeira, J.P.; Coelho, A.; Félix, A. Metastatic Endocervical Adenocarcinoma in a Mature Cystic Teratoma: A Case of a Tumor-to-Tumor Metastasis. *Int. J. Gynecol. Pathol.* **2018**, *37*, 559–563. [[CrossRef](#)]
16. Hutspardol, S.; Li, Y.; Dube, V.; Delabie, J. Concurrent Primary Follicular Lymphoma and a Mature Cystic Teratoma of the Ovary: A Case Report and Review of Literature. *Case Rep. Pathol.* **2022**, *2022*, 5896696. [[CrossRef](#)]
17. Tandon, N.; Sultana, S.; Sun, H.; Zhang, S. Follicular Lymphoma Arising in a Mature Cystic Teratoma in a 26-year-Old Female. *Ann. Clin. Lab. Sci.* **2016**, *46*, 298–301.
18. Hadžisejdić, I.; Babarović, E.; Vranić, L.; Duletić Načinović, A.; Lučin, K.; Krašević, M.; Jonjić, N. Unusual presentation of plasmablastic lymphoma involving ovarian mature cystic teratoma: A case report. *Diagn. Pathol.* **2017**, *12*, 83. [[CrossRef](#)] [[PubMed](#)]
19. Strobel, S.L.; Jenison, E.L.; Van Kooten, J.M.; Kitts, A.N.; Britton, A.J. Triple negative lobular breast carcinoma metastatic to an ovarian fibrothecoma. *J. Histotechnol.* **2020**, *43*, 200–203. [[CrossRef](#)]
20. Guo, Y.; Arciero, C.A.; Jiang, R.; Behera, M.; Peng, L.; Li, X. Different Breast Cancer Subtypes Show Different Metastatic Patterns: A Study from A Large Public Database. *Asian Pac. J. Cancer Prev.* **2020**, *21*, 3587–3593. [[CrossRef](#)]
21. Kennecke, H.; Yerushalmi, R.; Woods, R.; Cheang, M.C.; Voduc, D.; Speers, C.H.; Nielsen, T.O.; Gelmon, K. Metastatic behavior of breast cancer subtypes. *J. Clin. Oncol.* **2010**, *28*, 3271–3277. [[CrossRef](#)] [[PubMed](#)]
22. Smid, M.; Wang, Y.; Zhang, Y.; Sieuwerts, A.M.; Yu, J.; Klijn, J.G.M.; Foekens, J.A.; Martens, J.W.M. Subtypes of Breast Cancer Show Preferential Site of Relapse. *Cancer* **2008**, *68*, 3108–3114. [[CrossRef](#)] [[PubMed](#)]
23. Groisman, G.M. Lobular carcinoma of the breast metastatic to the spleen and accessory spleen: Report of a case. *Case Rep. Pathol.* **2016**, *2016*, 5160180. [[PubMed](#)]
24. Yoneyama, K.; Nakagawa, M.; Hara, A. Bladder metastasis from primary breast cancer: A case report. *Surg. Case Rep.* **2018**, *4*, 73. [[CrossRef](#)] [[PubMed](#)]
25. Lokadasan, R.; Ratheesan, K.; Sukumaran, R.; Nair, S.P. Metastatic lobular carcinoma of breast mimics primary cervix carcinoma: Two case reports and a review of the literature. *Ecancermedicalscience* **2015**, *9*, 571. [[CrossRef](#)] [[PubMed](#)]
26. Kong, D.; Dong, X.; Qin, P.; Sun, D.; Zhang, Z.; Zhang, Y.; Hao, F.; Wang, M. Asymptomatic uterine metastasis of breast cancer: Case report and literature review. *Medicine* **2022**, *101*, e31061. [[CrossRef](#)]
27. Franco-Márquez, R.; Torres-Gaytán, A.G.; Narro-Martinez, M.A.; Carrasco-Chapa, A.; Núñez, B.G.; Boland-Rodriguez, E. Metastasis of Breast Lobular Carcinoma to Endometrium Presenting as Recurrent Abnormal Uterine Bleeding: A Case Report and Review of Literature. *Case Rep. Pathol.* **2019**, *2019*, 5357194. [[CrossRef](#)]
28. Saranovic, D.; Kovac, J.D.; Knezevic, S.; Susnjarić, S.; Stefanovic, A.D.; Saranovic, D.S.; Artiko, V.; Obradovic, V.; Masulovic, D.; Micev, M.; et al. Invasive lobular breast cancer presenting an unusual metastatic pattern in the form of peritoneal and rectal metastases: A case report. *J. Breast Cancer* **2011**, *14*, 247–250. [[CrossRef](#)]
29. Abdallah, H.; Elwy, A.; Alsayed, A.; Rabea, A.; Magdy, N. Metastatic Breast Lobular Carcinoma to Unusual Sites: A Report of Three Cases and Review of Literature. *J. Med. Cases* **2020**, *11*, 292–295. [[CrossRef](#)]
30. Koufopoulos, N.; Pateras, I.S.; Gouloumis, A.R.; Ieronimaki, A.I.; Zacharitou, A.; Spathis, A.; Leventakou, D.; Economopoulou, P.; Psyrris, A.; Arkadopoulou, N.; et al. Diagnostically Challenging Subtypes of Invasive Lobular Carcinomas: How to Avoid Potential Diagnostic Pitfalls. *Diagnostics* **2022**, *12*, 2658. [[CrossRef](#)]
31. Soong, T.R.; Dillon, D.A.; Rice-Stitt, T.L.; Wiczorek, T.J.; Baker, G.M.; Darvishian, F.; Collins, L.C.; Lester, S.C.; Schnitt, S.J.; Harrison, B.T. Invasive lobular carcinoma with extracellular mucin (ILCEM): Clinicopathologic and molecular characterization of a rare entity. *Mod. Pathol.* **2022**, *35*, 1370–1382. [[CrossRef](#)] [[PubMed](#)]
32. Haltas, H.; Bayrak, R.; Yenidunya, S.; Kosehan, D.; Sen, M.; Akin, K. Invasive lobular carcinoma with extracellular mucin as a distinct variant of lobular carcinoma: A case report. *Diagn. Pathol.* **2012**, *7*, 91. [[CrossRef](#)] [[PubMed](#)]
33. Bari, V.B.; Bholay, S.U.; Sane, K.C. Invasive lobular carcinoma of the breast with extracellular mucin- a new rare variant. *J. Clin. Diagn. Res.* **2015**, *9*, ED05-6. [[CrossRef](#)] [[PubMed](#)]
34. Abdelazim, I.A.; Abu-Faza, M.; Abdelrazek, K.; Amer, O.O.; Shikanova, S.; Zhurabekova, G. Ovarian Fibroma Commonly Misdiagnosed as Uterine Leiomyoma. *Gynecol. Minim. Invasive Ther.* **2019**, *9*, 36–38. [[CrossRef](#)] [[PubMed](#)]
35. Tan, N.; Jin, K.Y.; Yang, X.R.; Li, C.F.; Yao, J.; Zheng, H. A case of death of patient with ovarian fibroma combined with Meigs Syndrome and literature review. *Diagn. Pathol.* **2022**, *17*, 83. [[CrossRef](#)] [[PubMed](#)]
36. Parwate, N.S.; Patel, S.M.; Arora, R.; Gupta, M. Ovarian Fibroma: A Clinico-pathological Study of 23 Cases with Review of Literature. *J. Obs. Gynaecol. India* **2016**, *66*, 460–465. [[CrossRef](#)]
37. Al-Agha, O.M.; Huwait, H.F.; Chow, C.; Yang, W.; Senz, J.; Kalloger, S.E.; Huntsman, D.G.; Young, R.H.; Gilks, C.B. FOXL2 is a sensitive and specific marker for sex cord-stromal tumors of the ovary. *Am. J. Surg. Pathol.* **2011**, *35*, 484–494. [[CrossRef](#)]
38. Lanitis, S.; Sivakumar, S.; Behranwala, K.; Zacharakis, E.; Al Mufti, R.; Hadjiminias, D.J. A case of Meigs syndrome mimicking metastatic breast carcinoma. *World J. Surg. Oncol.* **2009**, *7*, 1–6. [[CrossRef](#)]
39. Dochez, V.; Caillon, H.; Vaucel, E.; Dimet, J.; Winer, N.; Ducarme, G. Biomarkers and algorithms for diagnosis of ovarian cancer: CA125, HE4, RMI and ROMA, a review. *J. Ovarian Res.* **2019**, *12*, 28. [[CrossRef](#)]

40. Moore, R.G.; Jabre-Raughley, M.; Brown, A.K.; Robison, K.M.; Miller, M.C.; Allard, W.J.; Kurman, R.J.; Bast, R.C.; Skates, S.J. Comparison of a novel multiple marker assay vs. the Risk of Malignancy Index for the prediction of epithelial ovarian cancer in patients with a pelvic mass. *Am. J. Obstet. Gynecol.* **2010**, *203*, 228.e1–228.e6. [[CrossRef](#)]
41. Karlsen, M.A.; Sandhu, N.; Høgdall, C.; Christensen, I.J.; Nedergaard, L.; Lundvall, L.; Engelholm, S.A.; Pedersen, A.T.; Hartwell, D.; Lydolph, M.; et al. Evaluation of HE4, CA125, risk of ovarian malignancy algorithm (ROMA) and risk of malignancy index (RMI) as diagnostic tools of epithelial ovarian cancer in patients with a pelvic mass. *Gynecol. Oncol.* **2012**, *127*, 379–383. [[CrossRef](#)] [[PubMed](#)]
42. Borukh, E.; Ilyaev, B.; Muminiy, S.N.; Muminiy, S.N.; Babayev, M.; Musheyev, Y.; Levada, M. Ovarian Fibroma Presents As Uterine Leiomyoma in a 61-Year-Old Female: A Case Study. *Cureus* **2023**, *15*, e36264. [[CrossRef](#)] [[PubMed](#)]
43. Simpkins, F.; Zahurak, M.; Armstrong, D.; Grumbine, F.; Bristow, R. Ovarian malignancy in breast cancer patients with an adnexal mass. *Obstet Gynecol.* **2005**, *105*, 507–513. [[CrossRef](#)]
44. Ghenciu, L.A.; Faur, A.C.; Bolintineanu, S.L.; Salavat, M.C.; Maghiari, A.L. Recent Advances in Diagnosis and Treatment Approaches in Fungal Keratitis: A Narrative Review. *Microorganisms* **2024**, *12*, 161. [[CrossRef](#)]
45. Buza, N.; Wong, S.; Hui, P. FOXL2 Mutation Analysis of Ovarian Sex Cord-Stromal Tumors: Genotype-Phenotype Correlation with Diagnostic Considerations. *Int. J. Gynecol. Pathol.* **2018**, *37*, 305–315. [[CrossRef](#)] [[PubMed](#)]
46. Dănilă, A.-I.; Ghenciu, L.A.; Stoicescu, E.R.; Bolintineanu, S.L.; Iacob, R.; Săndesc, M.-A.; Faur, A.C. Aldose Reductase as a Key Target in the Prevention and Treatment of Diabetic Retinopathy: A Comprehensive Review. *Biomedicines* **2024**, *12*, 747. [[CrossRef](#)] [[PubMed](#)]
47. Zhao, C.; Vinh, T.N.; McManus, K.; Dabbs, D.; Barner, R.; Vang, R. Identification of the most sensitive and robust immunohistochemical markers in different categories of ovarian sex cord-stromal tumors. *Am. J. Surg. Pathol.* **2009**, *33*, 354–366. [[CrossRef](#)] [[PubMed](#)]
48. Deavers, M.; Malpica, A.; Liu, J.; Broaddus, R.; Silva, E.G. Ovarian Sex Cord-Stromal Tumors: An Immunohistochemical Study Including a Comparison of Calretinin and Inhibin. *Mod. Pathol.* **2003**, *16*, 584–590. [[CrossRef](#)] [[PubMed](#)]
49. Cserni, G.; Floris, G.; Koufopoulos, N.; Kovács, A.; Nonni, A.; Regitnig, P.; Stahls, A.; Varga, Z. Invasive lobular carcinoma with extracellular mucin production—a novel pattern of lobular carcinomas of the breast. Clinico-pathological description of eight cases. *Virchows Arch.* **2017**, *471*, 3–12. [[CrossRef](#)]
50. Sato, Y.; Yano, M.; Eto, S.; Takano, K.; Nasu, K. Metastasis from follicular lymphoma to an ovarian mature teratoma: A case report of tumor-to-tumor metastasis. *J. Ovarian Res.* **2023**, *16*, 106. [[CrossRef](#)]

**Disclaimer/Publisher’s Note:** The statements, opinions and data contained in all publications are solely those of the individual author(s) and contributor(s) and not of MDPI and/or the editor(s). MDPI and/or the editor(s) disclaim responsibility for any injury to people or property resulting from any ideas, methods, instructions or products referred to in the content.