

## Case Report

# Unusual Masquerading Infraorbital Mass—A Case Report of Human Ocular Dirofilariosis Found in A Ukrainian Patient in Switzerland

Feliciano Menna <sup>1,\*</sup>, Filippo Billia <sup>1</sup>, Anthia Papazoglou <sup>1</sup>, Markus Tschopp <sup>1,2</sup> and Rainer Grobholz <sup>3,4</sup>

<sup>1</sup> Department of Ophthalmology, Cantonal Hospital Aarau, CH-5001 Aarau, Switzerland; filippo.billia@gmail.com (F.B.); anthia.papazoglou@ksa.ch (A.P.); markus.tschopp@ksa.ch (M.T.)

<sup>2</sup> Department of Ophthalmology, Inselspital, Bern University Hospital, University of Bern, 3010 Bern, Switzerland

<sup>3</sup> Medical Faculty, University of Zurich Pestalozzistrasse 3, CH-8032 Zurich, Switzerland; rainer.grobholz@ksa.ch

<sup>4</sup> Institute of Pathology, Cantonal Hospital Aarau, CH-5001 Aarau, Switzerland

\* Correspondence: feliciano.menna@gmail.com; Tel.: +41-76-603-3530

† Current Address: Kantonsspital Aarau AG, Herzogstrasse 15, CH-5000 Aarau, Switzerland.

**Abstract:** A 78-year-old Ukrainian woman who had immigrated to Switzerland presented with a rapid growing subcutaneous infraorbital mass. Surgical excision of the mass revealed a well-circumscribed, encapsulated tumor, adherent to the skin. The excision showed a soft tissue inflammation with parts of *Dirofilaria* spp. The number of cases of human dirofilariosis reported in the last 50 years has gradually increased. *Dirofilaria repens* is now endemic in many countries and is currently considered to be one of the fast spreading zoonoses in Central, Eastern and Northern Europe. The first empirical evidence of Swiss spreading of *D. repens* infections was in a dog from southern Switzerland in 1998. Ours is the first case of human orbital dirofilariosis found in a Ukrainian patient reported in Switzerland. Our purpose is to inform the ophthalmologist to consider orbital dirofilariosis in the differential diagnosis of inflammatory masses of the orbit and to warn about the spread of this infection in Switzerland.

**Keywords:** infraorbital cyst; subcutaneous dirofilariosis; *Dirofilaria repens*; orbital tumor



**Citation:** Menna, F.; Billia, F.; Papazoglou, A.; Tschopp, M.; Grobholz, R. Unusual Masquerading Infraorbital Mass—A Case Report of Human Ocular Dirofilariosis Found in A Ukrainian Patient in Switzerland.

*Pathogens* **2023**, *12*, 982. <https://doi.org/10.3390/pathogens12080982>

Academic Editor: Anastasia Diakou

Received: 5 June 2023

Revised: 26 July 2023

Accepted: 26 July 2023

Published: 27 July 2023



**Copyright:** © 2023 by the authors. Licensee MDPI, Basel, Switzerland. This article is an open access article distributed under the terms and conditions of the Creative Commons Attribution (CC BY) license (<https://creativecommons.org/licenses/by/4.0/>).

## 1. Introduction

A wide variety of processes can produce space-occupying lesions in and around the orbit. These include benign neoplasms, malignant neoplasms, vascular lesions, inflammatory disease, congenital lesions, and infections, among other causes. Imaging can be used to precisely localize a lesion, to help establish a diagnosis or generate a differential diagnosis that guides management, to follow a known lesion for progression, or some combination of these [1].

In this report we describe a case of a rapidly growing subcutaneous infraorbital mass—masquerading as orbital tumor—secondary to a dirofilariosis.

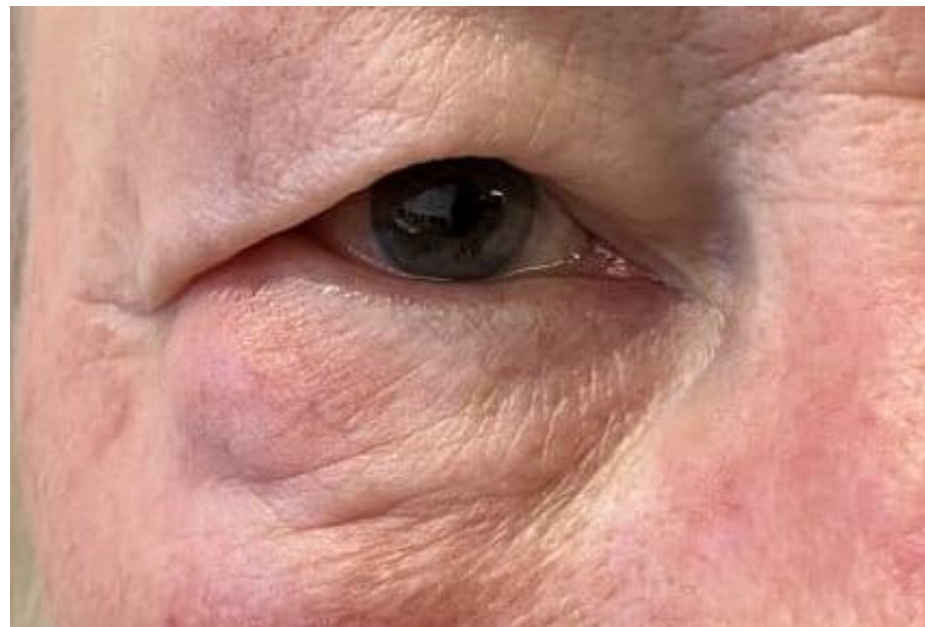This case report was prepared in accordance with the principles of the Declaration of Helsinki. As this article pertains only to a case report, specific ethics approval is not mandated. Written informed consent was taken from the patient to publish the photographs before inclusion in the article.

## 2. Case Report

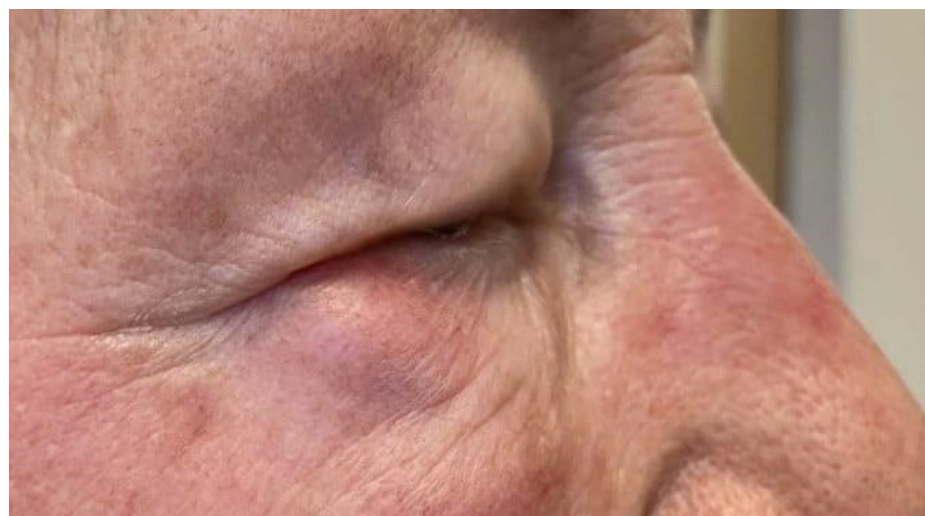A 78-year-old Ukrainian woman, who had moved to Switzerland about 6 months ago complained of a three-week history of sudden, relatively painless swelling in the lower right orbit (Figure 1). At the time of presentation in our clinic in November she had already been treated with corticosteroids and antibiotics, with no improvement. Since the patient

had been recently diagnosed with breast cancer, she was referred to us with the suspect of an orbital tumor or metastasis. She had no dogs of her own but lived in a family with dogs in Switzerland. She reported no recent foreign travel and could not recall any mosquito bites. Vision was 20/20 in both the eyes and intraocular pressure and fundus were normal. There was no evidence of conjunctival infection and hemorrhage. A round palpable hard and not very mobile subcutaneous mass was in the area of the lower lid/ anterior orbit. CT scan showed a round well-defined mass in the lower left orbit (Figure 2). An excision was performed under local anesthesia. The histological evaluation section showed a florid nodular soft tissue inflammation measuring  $1.4 \times 1 \times 1$  cm with abundant neutrophils and eosinophils. Centrally, sections of a nematode parasite could be observed. The nematode had an average cross-section of  $450 \mu\text{m}$  with an approximately  $7 \mu\text{m}$  thick cuticle with typical longitudinal grooves (Figure 3A,B). Within the worm, parts of the intestine and a paired uterus were visible. Based on this morphology, the parasite was a female *Dirofilaria* spp., probably *Dirofilaria repens*. The postoperative course went well and the patient had no complaints after the surgical excision of the mass.

(A)



(B)



**Figure 1.** (A,B) This 78-year-old woman had three weeks history of sudden and non-specific swelling in the lower right orbit.

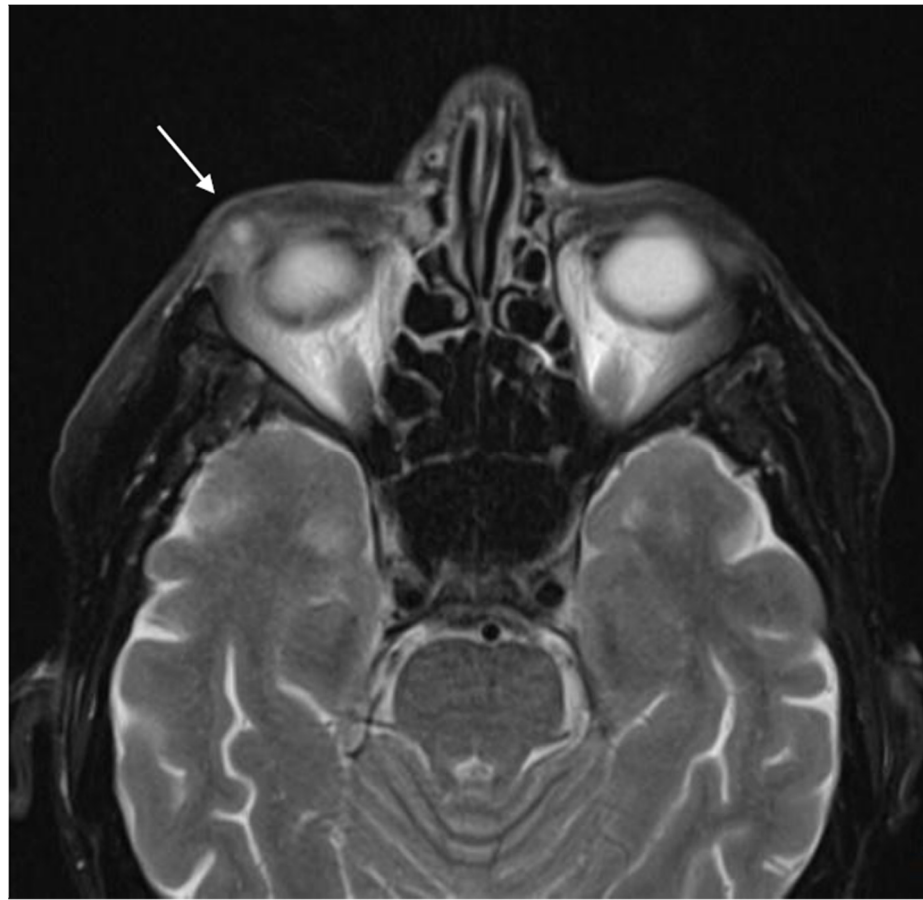

Figure 2. A CT scan showed a round, well-defined mass in the lower right orbit (arrow).

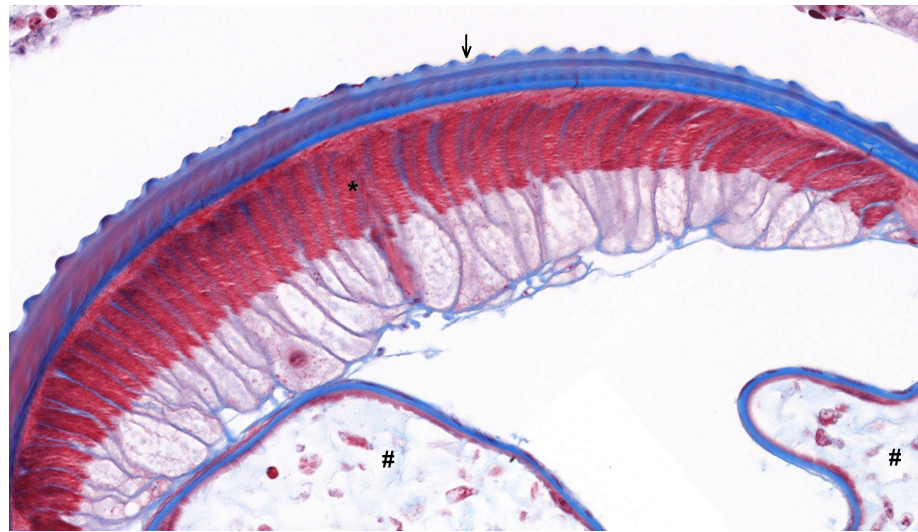
(A)

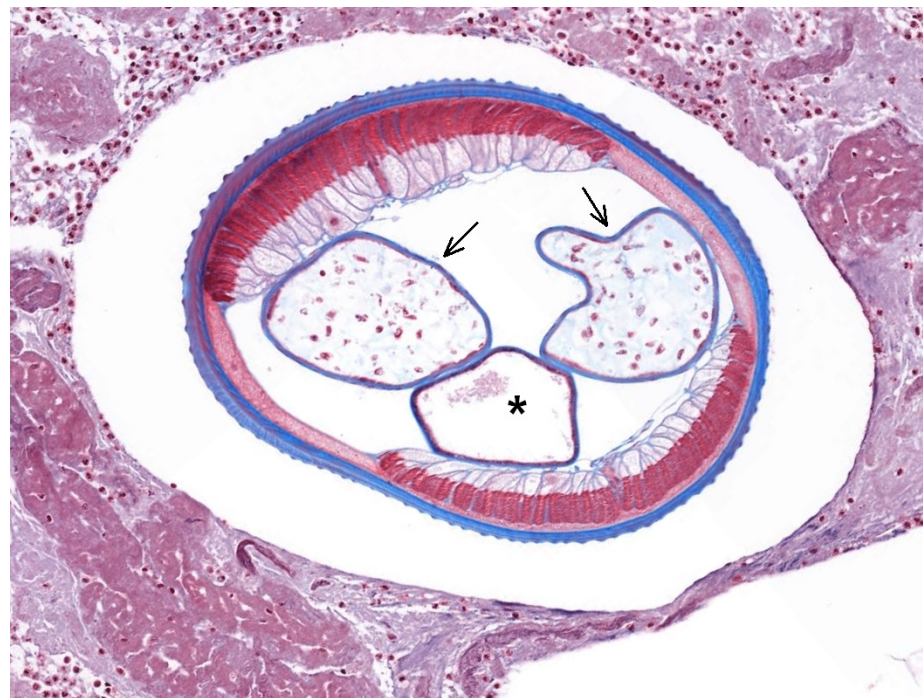

Figure 3. Cont.



(B)



**Figure 3.** Histological sections of the body of the worm. (A): The cross-section shows the digestive tube (asterisk) and the paired uterus (arrows), indicating a female worm (Masson's Trichrome 100×). (B): The outer wall is composed of a thick cuticle with typical longitudinal grooves (arrow). Underneath the cuticle are visible bands of muscle cells (asterisk). Parts of the uterus are also visible (hashtag) (Masson's Trichrom 400×).

### 3. Discussion

*Dirofilaria repens* is a nematode affecting domestic and wild canids, transmitted by several species of mosquitoes. It usually causes a non-pathogenic subcutaneous infection in dogs and is the principal agent of human dirofilariasis in Europe [2]. In recent decades, *D. repens* has increased in prevalence in areas where it has already been reported and its distribution range has expanded into new areas of Europe, representing a paradigmatic example of an emergent pathogen [3].

In the ophthalmology literature, the number of cases of human dirofilariasis reported in the last 50 years has gradually increased. Global warming in particular, has created conditions favoring the development of infective larvae in mosquitoes, and facilitated the recent spread of *Dirofilaria* spp. to Central Europe. *Dirofilaria repens* is now endemic in many countries in the region (Poland, Ukraine, Germany, Austria, Hungary, The Netherlands), and is currently considered to be one of the fastest spreading zoonoses in Central, Eastern, and Northern Europe [4,5]. In Ukraine, reporting cases of dirofilariasis has been mandatory since 1975, and the disease was included in the national surveillance system for notifiable diseases [6].

The first empirical evidence of Swiss spreading of *D. repens* infections was found in a dog in southern Switzerland in 1998. A few years later, another two positive dogs were found in Canton Ticino in 2001 [7,8].

*Dirofilaria repens* is a common parasite in dogs, which constitute the main source of infection. Humans are accidental hosts and many infected subjects are asymptomatic [5]. Transmission occurs through the bite of zooanthrophilic species of the mosquito genera *Aedes*, *Culex*, or *Anopheles* mosquitoes carrying infective larvae acquired from the microfilariae-rich blood of animal hosts parasitized with either deep-seated or subcutaneous worms of the *Dirofilaria* spp. In humans, the nematode causes a subcutaneous or superficially located inflammatory reaction that traps it within a nodule, where it may survive for many years [9]. Such lesions are always associated with moderate to severe inflammation. However, it may also present as a noninflammatory lid tumor.

*Dirofilaria repens* is well known to affect the eye and the ocular adnexa [10]. The infection may be periorcular, subconjunctival, or intraocular. The first case of ocular dirofilariasis was reported in 1885 by Addario [11], an Italian ophthalmologist. He found a *Dirofilaria* worm in the conjunctiva of a Sicilian woman and called it *Dirofilaria conjunctivae*. The

largest series of cases—six with periocular involvement of *D. repens*—was described by Font in 1980 [12]. More recently reports have included one involving the lateral rectus muscle of a 20-year-old man [13], conjunctival tissue of a 27-year-old female [14] and a 35-year-old male [15] and a superficial orbital dirofilariasis in a 24-year-old female [16]. A case was recently reported of ocular dirofilariasis in a 76-year-old patient in the course of cataract surgery in Bulgaria caused by a gravid female nematode [17] and a case of a 12-year-old patient with a rapidly growing deep orbital mass and imaging findings suggestive of rhabdomyosarcoma that was found to be dirofilariasis after mass resection [18]. Our case showed the typical morphologic picture of a female *D. repens*; however, based on histologic criteria alone, in the differential diagnosis an onchocerciasis has to be considered. *Onchocerca lupi* (zoonotic) is also present in Europe. In the present case, the morphology of the parasite makes us think with high probability of an infection with *D. repens*; the morphological distinctive characters of female nematodes allow a straightforward identification. *Onchocerca lupi* presents a thick cuticle composed of an external layer bearing prominent, undulated annular ridges and an internal layer with transverse striae [19]. These morphological features are not present in *D. repens*, which has longitudinal crests. Since *O. volvulus* occurs mainly in Africa, with additional foci in Latin America and the Middle East, the present case represents, with a very high probability, *D. repens* infection rather than an onchocerciasis.

In the literature there are 38 up-to-date reported cases of ocular/orbital/eyelid dirofilariasis. The majority of articles were case reports of up to three patients, with the exception of Dzamic et al. [20] who presented 19 cases of human dirofilariasis in Serbia, both ocular and subcutaneous, and Kalogeropoulos et al. [21], who presented eight cases of ocular dirofilariasis. In published reports of ocular dirofilariasis, most of the cases were located under the conjunctiva (>60% of all cases), followed by orbital/eyelid dirofilariasis (approximately 25%).

In general, the diagnosis of human dirofilariasis is based on histologic examination. Useful characteristics for differentiating between the different *Dirofilaria* spp. are the size and the features of the body wall, i.e., thickness of the cuticle and its structure, ridges, lateral chords, and number and type of muscle cells [22].

Usually, the clinical symptoms disappear after the parasite is removed and no adjunct therapy is necessary [23].

#### 4. Conclusions

This is the first report of human infraorbital dirofilariasis masquerading as an orbital tumor found in a Ukrainian patient reported in Switzerland.

Climate change affecting mosquito vectors and the facilitation of pet travel seem to have contributed to this expansion; however, the major factor is likely the rate of undiagnosed dogs perpetuating the life-cycle of *D. repens* [2]. Many infected dogs remain undetected due to the subclinical nature of the disease, the lack of rapid and reliable diagnostic tools and the poor knowledge and still low awareness of *D. repens* in non-endemic areas.

Because the clinical onset of orbital dirofilariasis is usually marked by common symptoms of orbital inflammation such as redness and swelling, ophthalmologists are advised to consider this parasite in the differential diagnosis of inflammation of the orbital tissues. The differential diagnosis in these cases includes dermoid cysts, sarcoidosis, idiopathic pseudotumor, benign and malignant tumors including metastatic disease.

The purpose of this report is to inform ophthalmologists to consider orbital dirofilariasis in the differential diagnosis of inflammatory masses of the orbit and to warn about the spread of this infection in Switzerland.

In our view, it is critical to register all new cases in order to assess the epidemiological status and raise awareness of this rare infection.

**Author Contributions:** Conceptualization, M.T.; methodology, R.G.; software, F.B.; validation, M.T.; formal analysis, R.G.; investigation, F.M.; resources, F.M.; data curation, A.P.; writing—original draft preparation, F.M.; writing—review and editing, R.G., M.T. and A.P.; visualization, F.B.; supervision, R.G., M.T. and A.P.; project administration, F.M.; funding acquisition, F.B. All authors have read and agreed to the published version of the manuscript.

**Funding:** This research received no external funding.

**Institutional Review Board Statement:** Ethical approval is not required for this study in accordance with local or national guidelines.

**Informed Consent Statement:** Informed consent was obtained from all subjects involved in the study.

**Data Availability Statement:** Not applicable.

**Conflicts of Interest:** The authors declare no conflict of interest.

## References

- Khan, S.N.; Sepahdari, A.R. Orbital masses: CT and MRI of common vascular lesions, benign tumors, and malignancies. *Saudi J. Ophthalmol.* **2012**, *26*, 373–383. [[CrossRef](#)] [[PubMed](#)]
- Gutiérrez-Jara, J.P.; Salazar-Viedma, M.; González, C.R.; Cancino-Faure, B. The emergence of *Dirofilaria repens* in a non-endemic area influenced by climate change: Dynamics of transmission using a mathematical model. *Acta Tropica* **2022**, *226*, 106230. [[CrossRef](#)] [[PubMed](#)]
- Capelli, G.; Genchi, C.; Baneth, G.; Bourdeau, P.; Brianti, E.; Cardoso, L.; Danesi, P.; Fuehrer, H.-P.; Giannelli, A.; Ionică, A.M.; et al. Recent advances on *Dirofilaria repens* in dogs and humans in Europe. *Parasites Vectors* **2018**, *11*, 663. [[CrossRef](#)] [[PubMed](#)]
- Rymgayłło-Jankowska, B.; Ziaja-Sołtys, M.; Flis, B.; Bogucka-Kocka, A.; Żarnowski, T. Subcutaneous *Dirofilaria* of the Eyelid Brought to Poland from the Endemic Territory of Ukraine. *Pathogens* **2023**, *12*, 196. [[CrossRef](#)] [[PubMed](#)]
- Simón, F.; Diosdado, A.; Siles-Lucas, M.; Kartashev, V.; González-Miguel, J. Human *dirofilariosis* in the 21st century. A scoping review of clinical cases reported in the literature. *Transbound. Emerg. Dis.* **2022**, *69*, 2424–2439. [[CrossRef](#)]
- Salamatin, R.; Pavlikovska, T.M.; Sagach, O.S.; Nikolayenko, S.M.; Korniyushin, V.V.; Kharchenko, V.O.; Masny, A.; Cielecka, D.; Konieczna-Salamatin, J.; Conn, D.B.; et al. Human *dirofilariosis* due to *Dirofilaria repens* in Ukraine, an emergent zoonosis: Epidemiological report of 1465 cases. *Acta Parasitol.* **2013**, *58*, 592–598. [[CrossRef](#)]
- Pampiglione, S.; Rivasi, F. Human *dirofilariosis* due to *Dirofilaria (Nochtiella) repens*: An update of world literature from 1995 to 2000. *Parassitologia* **2000**, *42*, 231–254.
- Petruschke, G.; Rossi, L.; Genchi, C.; Pollono, F. Canine *dirofilariosis* in the canton of Ticino and in the neighboring areas of northern Italy. *Schweiz. Arch. Tierheilkd.* **2001**, *143*, 141–147.
- Smitha, M.; Rajendran, V.R.; Devarajan, E.; Anitha, P.M. Case report: Orbital *dirofilariosis*. *Indian J. Radiol. Imaging* **2008**, *18*, 60–62.
- Strianese, D.; Martini, A.; Molino, G.; Falabella, L.; Tranfa, F. Orbital *dirofilariosis*. *Eur. J. Ophthalmol.* **1998**, *8*, 258–262. [[CrossRef](#)]
- Addario, C. Su di un mematoide dell'occhio umano. *Ann. Ottalmol. Clin. Ocul.* **1985**, *14*, 135–147.
- Font, R.L.; Neafie, R.C.; Pery, H.D. Subcutaneous *dirofilariosis* of the eyelid and ocular adnexa. Report of six cases. *Arch. Ophthalmol.* **1980**, *98*, 1079–1082. [[CrossRef](#)]
- Makaveev, I.; Galev, A.; Marinova, P.; Martinov, M.; Harizanov, R.; Rainova, I.; Karsheva, M. First case of ocular *dirofilariosis* in Bulgaria caused by gravid female *Dirofilaria repens*. *Ann. Parasitol.* **2022**, *68*, 191–193.
- Bergin, D.J.; Parmley, V. Orbital neurilemoma. *Arch. Ophthalmol.* **1988**, *106*, 414–415. [[CrossRef](#)]
- Goto, H.; Mori, H.; Shirato, S.; Usui, M. Ciliary body schwannoma successfully treated by local resection. *Jpn. J. Ophthalmol.* **2006**, *50*, 543–546. [[CrossRef](#)]
- Smith, P.A.; Damato, B.E.; Ko, M.K.; Lyness, R.W. Anterior uveal neurilemoma—A rare neoplasm simulating malignant melanoma. *Br. J. Ophthalmol.* **1987**, *71*, 34–40. [[CrossRef](#)]
- Fan, J.T.; Campbell, R.J.; Robertson, D.M. A survey of intraocular schwannoma with a case report. *Can. J. Ophthalmol.* **1995**, *30*, 37–41.
- Pakdel, F.; Ghadimi, H.; Nozarian, Z.; Amoli, F.A.; Pirmarzashti, N.; Karimi, M.; Mehrpour, M. Orbital *Dirofilaria* Masquerading as Orbital Rhabdomyosarcoma. *J. Ophthalmic Vis. Res.* **2022**, *17*, 587–591. [[CrossRef](#)]
- Otranto, D.; Dantas-Torres, F.; Cebeci, Z.; Yeniad, B.; Buyukbabani, N.; Boral, O.B.; Gustinelli, A.; Mounir, T.; Mutafchiev, Y.; Bain, O. Human ocular filariosis: Further evidence on the zoonotic role of *Onchocerca lupi*. *Parasit Vectors.* **2012**, *5*, 84.
- Džamić, A.M.; Čolović, I.V.; Arsić-Arsenijević, V.S.; Stepanović, S.; Boričić, I.; Džamić, Z.; Mitrović, S.M.; Rašić, D.M.; Stefanović, I.; Latković, Z.; et al. Human *Dirofilaria repens* infection in Serbia. *J. Helminthol.* **2009**, *83*, 129–137. [[CrossRef](#)]
- Kalogeropoulos, C.; Stefanidou, M.; Gorgoli, K.; Papadopoulou, C.; Pappa, C.; Paschidis, C. Ocular *dirofilariosis*: A case series of 8 patients. *Middle East Afr. J. Ophthalmol.* **2014**, *21*, 312–316. [[CrossRef](#)] [[PubMed](#)]

22. Stringfellow, G.J.; Francis, I.C.; Coroneo, M.T.; Walker, J. Orbital dirofilariasis. *Clin. Exp. Ophthalmol.* **2002**, *30*, 378–380. [[CrossRef](#)] [[PubMed](#)]
23. Kartashev, V.; Afonin, A.; González-Miguel, J.; Sepúlveda, R.; Simón, L.; Morchón, R.; Simón, F. Regional warming and emerging vector-borne zoonotic dirofilariasis in the Russian Federation, Ukraine, and other post-Soviet states from 1981 to 2011 and projection by 2030. *BioMed Res. Int.* **2014**, *2014*, 858936. [[PubMed](#)]

**Disclaimer/Publisher’s Note:** The statements, opinions and data contained in all publications are solely those of the individual author(s) and contributor(s) and not of MDPI and/or the editor(s). MDPI and/or the editor(s) disclaim responsibility for any injury to people or property resulting from any ideas, methods, instructions or products referred to in the content.