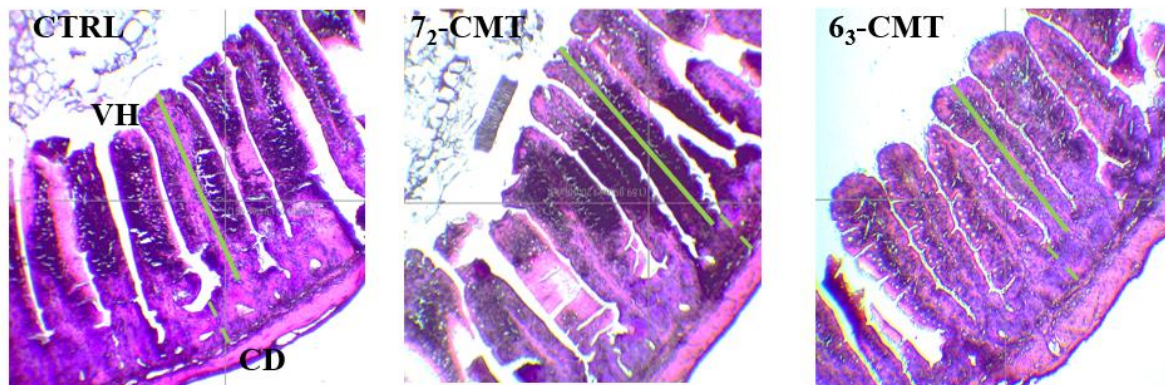


Figure S1. The examples of the morphological changes of the villus height and crypt depth in the ileum of recipient chickens at A) week 5 and B) week 16. Magnification: $\times 100$. — Villus height (VH); - - - Crypt depth (CD).

A week 5



B week 16

