




Article

Retrospective Analysis on Inferior Third Molar Position by Means of Orthopantomography or CBCT: Periapical Band-Like Radiolucent Sign

Young-Sam Kim ¹, Young-Min Park ¹, Saverio Cosola ², Abanob Riad ^{3,*}, Enrica Giammarinaro ², Ugo Covani ^{2,4} and Simone Marconcini ²

¹ Gangam Dental Office, Seoul 06614, Korea; doctorkimys@gmail.com (Y.-S.K.); min1810@hotmail.com (Y.-M.P.)

² Department of Stomatology, Tuscan Stomatologic Institute, Foundation for Dental Clinic, Research and Continuing Education, 55042 Forte dei Marmi, Italy; s.cosola@hotmail.it (S.C.); e.giammarinaro@gmail.com (E.G.); covani@covani.it (U.C.); simosurg@gmail.com (S.M.)

³ Department of Public Health, Faculty of Medicine, Masaryk University, Kamenice 5, 625 00 Brno, Czech Republic

⁴ Oral Surgery and Implantology, Unicamillus International Medical University, 00131 Rome, Italy

* Correspondence: abanoub.riad@med.muni.cz

Abstract: Background: Orthopantomography (OPG) is usually used as a primary diagnostic radiological exam in the planning of third molar surgery because it is deeply available in dental clinics and has lower radiation doses compared to Cone-beam computed tomography (CBCT). The OPG provides a bi-dimensional image, but several radiological signs have been proposed to study the position of the lower third molar and to predict surgical risks. Methods: Patients were divided into two groups, the OPG with a radiolucent area (D-group) and the OPG without any sign (C-group) in correspondence of inferior wisdom tooth roots. Results: The mean distance between the inferior third molar root and the lingual cortical mandibular bone was -1.09 ± 1.5 mm. The nearness of the root that is less than 1 mm was more frequent in the D-group (84.85%) compared to the C-group (14.58%) with statistical significance (Odd ratio: 32.8) using the Chi-square test. Conclusions: When the root of the impacted inferior third molar is impacted into the lingual cortical plate, a periapical band-like radiolucent sign may appear in the OPG image. It could be useful for the prediction of root position and surgical risks.

Keywords: radiolucent sign; OPG; CBCT; third molar; oral surgery; periapical sign



Citation: Kim, Y.-S.; Park, Y.-M.; Cosola, S.; Riad, A.; Giammarinaro, E.; Covani, U.; Marconcini, S. Retrospective Analysis on Inferior Third Molar Position by Means of Orthopantomography or CBCT: Periapical Band-Like Radiolucent Sign. *Appl. Sci.* **2021**, *11*, 6389. <https://doi.org/10.3390/app11146389>

Academic Editor: Vittorio Checchi

Received: 9 June 2021

Accepted: 7 July 2021

Published: 10 July 2021

Publisher's Note: MDPI stays neutral with regard to jurisdictional claims in published maps and institutional affiliations.



Copyright: © 2021 by the authors. Licensee MDPI, Basel, Switzerland. This article is an open access article distributed under the terms and conditions of the Creative Commons Attribution (CC BY) license (<https://creativecommons.org/licenses/by/4.0/>).

1. Introduction

Do dental clinicians need to extract all third molars? On May 2000 in the UK, National Institute for Health and Care Excellence (NICE) published the guidelines about the extraction of third molars. The NICE guidelines recommended that third molar extraction should be limited to teeth with pathologies such as caries lesion, peri-apical lesions, recurrent pericoronitis, lesion to the second molar, cyst/neoplastic lesions, etc. [1].

Still, in the last decades, the frequency of third molar extraction by oral surgeons and general dentists has been increasing [2]. Some cohort studies reported that between 30% and 60% of people who have retained their asymptomatic, unerupted wisdom teeth will need of at least one extraction in the next future (4–12 years after their first evaluation). In fact, third molars tend to change position towards the coronal and mesial direction, resulting in the damage of second molars or becoming partially erupted, thus meaning at a higher risk of caries or pericoronitis [3].

It is believed that the presence of the third molar is a phenomenon of human vestigiality so that the prevalence is very high and various according to population and familiarity [4].

In Sweden, 72% of the young population aged between 20 to 30 years has, at least, one impacted lower third molar and, in the UK, it is estimated that every year, 4 people out of 1000 will need a third molar extraction [5].

A retrospective cohort study of De Brynn L et al. (2020) including 1682 patients reported that the common reasons to avoid third molars extraction are: right eruption with function in occlusion (31.9%), patient preference (31.5%), and absence of symptom in patients >30 years old (17.5%) [6]. Compromised health status and advanced age were often included in the decision regarding whether to retain the third molars or not. One-third of the referred patients had reasons to retain one or more third molars. These findings might facilitate the future development of a consensus statement.

Prevalent literature indicates that wisdom teeth surgery is often performed by general dentists, however, the cost-benefit relationship and the complication rate should be carefully considered before initiating any treatment plan [2].

A retrospective study of Sarica and co-workers (2019) suggested that impacted teeth with no pathologies could be left in site monitoring the evolution. In those cases, Orthopantomography (OPG) is very useful to monitor the evolution of impacted third molar but cone-beam computed tomography (CBCT) is needed to predict the surgical risk [7].

It is well reported that Orthopantomography (OPG) is routinely used as a primary diagnostic exam in third molar surgery, and it is useful in the initial decision-making process [1,8]. Typical radiological signs of high risk of inferior alveolar nerve (IAN) damage are the darkening of the roots; a deflected root; narrowing of the root; diversion or loop of the inferior alveolar canal [9].

Despite this knowledge, some studies reported that there is an incidence of 17% of transitory nerve damage in patients who presented these signs in OPG plus 2% of permanent nerve damage [10].

The present retrospective study was performed to assess whether specific OPG findings could predict the risk level of a third molar extraction and, therefore, the putative need for further patients X-ray exposure to CBCT to have a better understanding of the anatomy.

The aim was to evaluate the pre-operative position of wisdom teeth as seen on OPGs and to compare this position with the one found on CBCT. The null hypothesis was that the radiolucent area at the apical portion of third molar roots as observed on OPG-(Y-sign)-does not match with the impaction of the root into the lingual cortical bone on the CBCT of the same patient.

2. Materials and Methods

2.1. Study Design

This is a monocentric retrospective comparative study approved by the Gangnam Academy of Wisdom tooth Extraction (GAWE), Seoul, South Korea.

Patients, admitted to “Gangnam Dental Office” (Seoul, South Korea) to remove an inferior third molar between January 2015 and December 2019, were retrospectively enrolled for the present study.

The subjects were searched on the database of the dental clinic using the following inclusion criteria:

- Patients who received both an OPG and CBCT before inferior third molar extraction following the guidelines: CBCT was performed after OPG because the inferior alveolar canal appeared near (or superimposed) to the root with high pre- or post-surgical risk [1];
- Patients who received the inferior third molar surgery by the director of the clinic (Kim YS.);
- Consecutive patients aged between 25 to 35 years old (this range because people with more than 40 years could have other pathologies or compliances and because the complete root development in the third molars may occur up to 24 years but with individual variation according to the studies) [11].

Evaluating the moment of the surgery, the search was pursued according to the following exclusion criteria:

- subject with severe systemic or genetic disease affecting the bone metabolism;
- subject in radiotherapy or chemotherapy or bisphosphonates;
- subject with not completely formed root of the third;
- subject with a fracture of mandibula.

2.2. Collection of Data

OPG and CBCT were performed by a CBCT machine (Vatech, South Korea).

Images of fundamental structures of CBCT in axial, panorex, and cross-sections planes and 3D were captured and reformatted in JPG-image. These screenshots were saved in the same chart of OPG for each patient with anamnestic data. The measurement of the minimum distance between the root and the lingual cortical bone of the mandibula was performed with the same program used to read the CBCT, a computer-assisted stereological analysis system (Vatech, South Korea) [12].

The chosen landmark in the lingual cortical bone was the most buccal one: if the roots overcame the buccal surface of the lingual cortical bone, the assigned value was negative because the surgery became riskier; on the contrary, if the root was inside of the trabecular bone, the value assigned was positive as represented in Figure 1 and the surgery could have less risk of complications such as fracture of cortical bone or roots. [12,13].

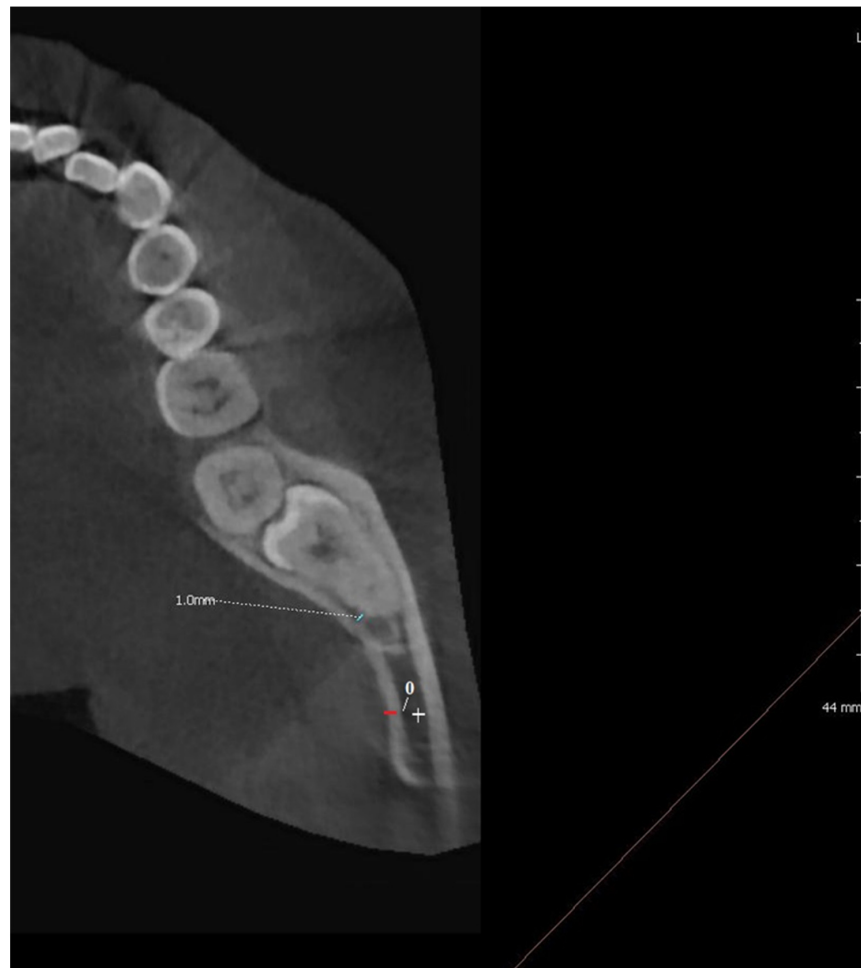

Figure 1. The distance is directly proportional to the root position. If the root is distant from the lingual cortical bone the measurement is considered positive when the root is in contact with the cortical lingual bone the distance is 0 and into the lingual cortical bone, the distance is negative. As reported in the figure the landmark for zero value is the buccal portion of the lingual cortical bone. The distance in the trabecular bone is positive (white) and the distance into the cortical bone is negative (red). The distance for this third molar is 1 mm (green).

The screenshot of this minimum distance was saved for each patient in CBCT.

Anamnestic data consisted of the following information: age, gender, smoking habits, a reason to require the extraction.

All wisdom teeth extractions were performed using the ESSE (Easy Simple Safe Efficient) surgical technique [2,13].

2.3. Modern Radiological Material for Clinicians

Modern technology such as digital OPG and CBCT in the dental field offers to clinicians several tools for diagnosis and research. The OPG and CBCT used in the present study followed the principle of justification and optimization. CBCT had a low-dose protocol with large FOV, but normal resolution and normal quality images (80 kVp, 5 mA). The acquisition time used to be 15 s corresponding to the effective dose of 35 μ Sv [14].

The effective dose indicates the evaluation risk of the patients, meaning the unit of energy absorbed by the unit of mass (J/Kg) [8].

PaX-i3D Smart is an advanced digital dental diagnostic software that incorporates Panoramic, Cephalometric, and CBCT imaging capabilities into a single system of Vatech, (Hwaseong-si, Korea) used in the present study.

2.4. Groups of Patients

The entire cohort of patients was divided into 2 main groups according to a first OPG examination of the inferior teeth needed for extraction.

- Dark-group (D-group): The pre-operative OPG of patients who had a dark area at the apical portion of the root/roots of the inferior third molar;
- Control-group (C-group): The pre-operative OPG of patients who did not present a radiolucent area at the apical portion of the root/roots of the inferior third molar.

2.5. Statistical Analysis

The data were evaluated using Statistical Package for the Social Sciences SPSS® 26 (Java, May 2019, USA). Descriptive statistic was used to describe the population frequency, mean and standard deviation (SD).

D-group and C-group were compared using CBCT to check if the apical portion of the inferior third molar was distant from the lingual cortical bone of the mandibula. These two groups were compared using Student's t-test at a 0.05 significance level.

On evaluating the distance between the nearest portion of the root/roots and the buccal portion of the lingual cortical bone, the authors used a cut-off point of -1 mm. If the root is completely in the cortical bone the distance will be ≤ -1 mm and the third molar is classified as "impacted" or if the distance is > -1 mm the tooth is "non-impacted". This cut-off point of -1 mm was established for clinical reasons because, if the root is impacted completely in the lingual cortical bone (less than -1 mm), the surgery could be more difficult and the surgical risks such as fracture may be more frequent [15]. The comparisons between groups were performed using Chi-square for these parameters.

In the D-group a stratification of patients was performed according to a differential diagnosis observing the OPG and CBCT and 2 subgroups were created:

2.6. Pathological Signs

- No-group: No sign of pathologies that could explain the radiolucent area in the apical portion of the root of the inferior wisdom tooth;
- Yes-group: Some signs of pathologies that could explain the radiolucent area in the apical portion of the root of the inferior wisdom tooth, such as caries and cystitis.

The Chi-squared test was used to assess differences and correlation between variables at a 0.05 significance level.

In the D-group a stratification of patients was performed according to a differential diagnosis observing the OPG and CBCT in the second subgroup to distinguish the exact cause of the radiolucent area around the root:

3. Results

Two hundred and forty-nine patients met the inclusion criteria of this study; however, twenty-one patients were excluded after reviewing clinical and radiographic records due to. Demographic data of two hundred and twenty-eight are reported in Table 1. The mean age of patients was 30.47 ± 0.5 (30–31, $n = 228$) years old with 120 (52.6%) male and 108 (49.4%) female patients. While 100 (43.86%) of the extracted molars were from the right side, 128 (56.14%) were from the left side with similar distribution between groups. According to the OPG, 132 (57.89%) patients had a radiolucent area at the apical portion of the third molar in need for extraction (D-group), while 96 (42.11%) patients did not present any relevant sign (C-group). In the entire cohort, the mean distance between the nearest portion of the root/roots to the buccal portion of the lingual cortical bone was -1.09 ± 1.5 mm. While 126 (55.26%) patients had impacted third molars with at least-1 mm of root in the lingual cortical plate, 102 (44.74%) had non-impacted third molars. The impaction of the root of 1 mm resulted more frequently with statistical significance (Odd ratio: 32.8) using Chi-square in the D-group (84.85%) compared to C-group (14.58%) as showed in Figure 2. Stratification of patients was performed according to a differential diagnosis observing both OPG and comparing the presence of the “Periapical Band-Like Radiolucent Sign” in the CBCT too:

- True sign (Y-sign): the pre-operative OPG shows a band-like radiolucent sign corresponding to the apical portion of the root of the inferior third molar with no sign of other reason that could explain this. On CBCT image lingual impaction of the root is observed.
- False sign (F-sign): OPG image shows a band-like radiolucent area corresponding to the apical portion of the root of the inferior third molar and determining causes of the radiolucent area visible on OPG and CBCT such as Juxta-Apical Radio-Translucency, peri-apical lesion, immature apex, impaction of the inferior alveolar nerve into the lingual plate, apex impaction into the buccal plate.

Table 1. demographic and clinical characteristics of D-group vs. C-group patients. *N* = number, *SD* = standard deviation, *Sig* = statistical significance using Chi-square and One-way ANOVA. * = *p* value with significance level.

	C-Group (N = 96)	D-Group (N = 132)	Total (N = 228)	Sig.
Age (mean \pm SD)	30.53 \pm 0.5	30.43 \pm 0.5	30.47 \pm 0.5	0.14
Gender (Female/Male)	52/44	56/76	108/120	0.47
Side (Left/Right)	47/39	81/61	128/100	0.17
Impaction $<$ -1 mm (Yes/Tot.)	14/96 14.58%	112/132 84.85%	126/208 60.58%	$<$0.001 *
Radiolucency due to a pathology/non-pathology	/	11/121		
Juxta-apical Radiolucency (JAR)	/	4/132		
Inferior Alveolar Nerve (IAN) impaction	/	10/132		

The most frequent reasons for extraction were pericoronitis with or without resorption on the adjacent lower second molar (75%), caries of the wisdom tooth (13.6%), and caries of the lower second molar (9.2%).

As reported in Table 2, the mean distance between the root and cortical bone was not significantly different between male and female patients, left side and right side of mandibula. One-way ANOVA test revealed that there was a highly significant difference in mean distance between D-group (-1.89 ± 1.26 mm) and C-group (0 ± 1.6 mm) with $p < 0.001$. Analyzing CBCT, within D-group, the dark area was related to pathology in 11 cases (subgroup Yes-pathology), no sign of pathology in 121 cases (subgroup No-pathology). Four cases within No-pathology were false Y-sign because they had juxta-

apical radiolucency (JAR) and in ten CBCT an Inferior Alveolar Nerve (IAN) impaction was observed.

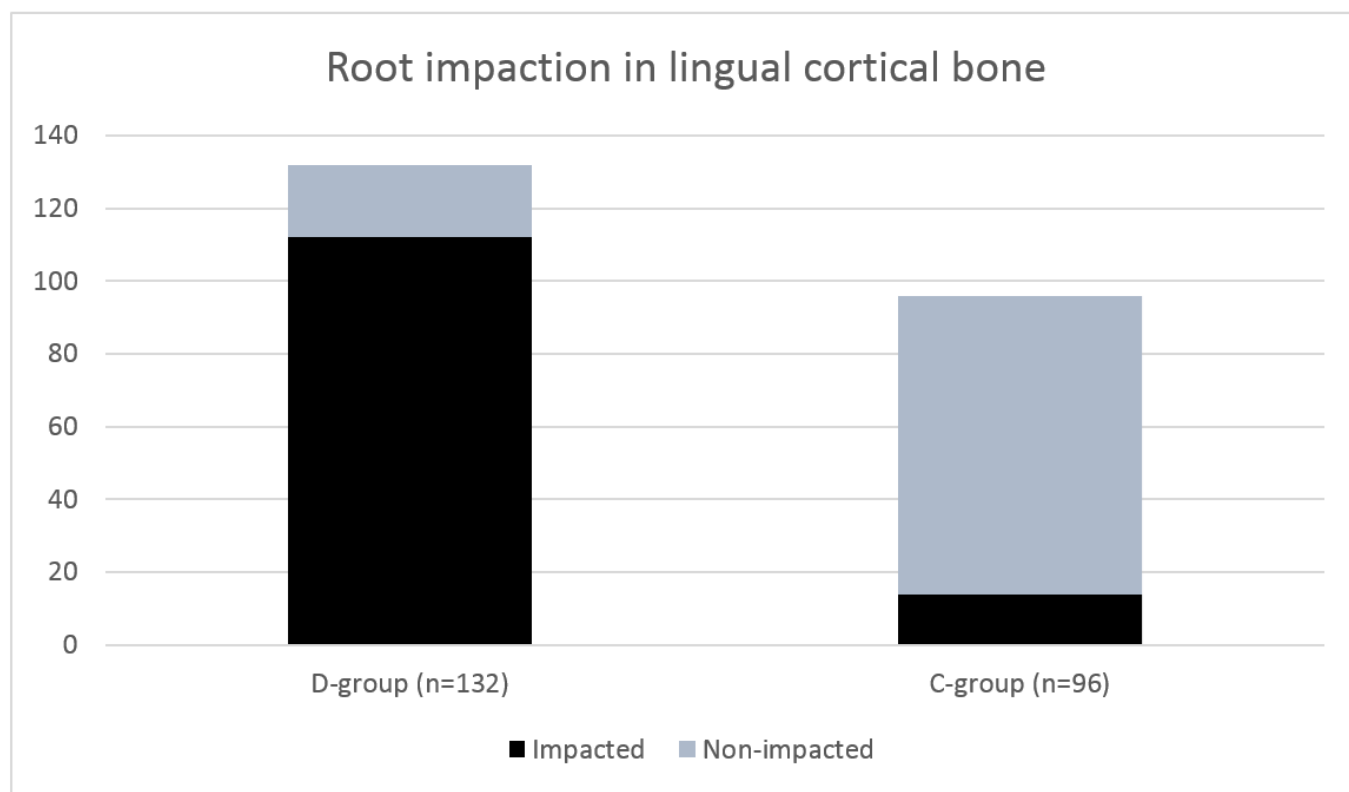


Figure 2. A graphic representation of the distribution of patients with impaction of the root in the lingual cortical bone of at least 1 mm (in black) in D-group (84.85%, 112/132) and C-group (14.58%, 14/96).

Table 2. Mean distance across the study groups. SD = standard deviation, Sig = statistical significance using One-way ANOVA and T-test. * = *p* value with significance level.

	Mean Distance (Mean ± SD) in Millimeter		Sig.
Total Group (n = 228)	−1.09 ± 1.5 mm		
Group	C-group (0 ± 1.6) (n = 96)	D-group (−1.89 ± 1.26) (n = 132)	<0.001 *
Pathological Sign in D-group	Yes (−0.22 ± 1.54 mm) (n = 11)	No (−2.04 ± 1.12) (n = 121)	<0.001 *
Juxta-apical Radiolucency (JAR)		(0.77 ± 0.84 mm) (n = 4)	Not detectable
Inferior Alveolar Nerve (IAN) impaction		(0.81 ± 0.44 mm) (n = 10)	Not detectable

Within D-group ($n = 132$), the difference between patients without pathological signs ($n = 121$, -2.04 ± 1.12 mm) and patients with pathological signs ($n = 11$, -0.22 ± 1.54 mm) was statistically significant $p < 0.001$ in term of mean distance. In D-group, the impaction of the root of 1 mm resulted more frequently in the No-Pathology group (110/121; 90.91%) compared to the Yes-Pathology group (2/11; 18.18%) with no statistical significance using Chi-square because of the short sample of patients with pathology in D-group.

Similarly, there was an important difference between False Y-sign due to IAN-impaction ($n = 10$, 0.81 ± 0.44 mm) or to JAR ($n = 4$, 0.77 ± 0.84 mm) compared to D-group, but it was not possible to statistically compare these subgroups due to the short samples. Within the D-group, 112 (84.84%) patients had true Y-sign, corresponding to the same value of tooth impacted in the lingual plate (2 patients belong to subgroup Yes-pathology group).

4. Discussion

If the OPG is interpreted correctly, numerous signs may help clinicians to predict the wisdom tooth position decreasing the risk of injury to the IAN. Sometimes, the signs are

confirmed by CBCT and the risk of complications during or after surgery is too high so that a coronectomy technique is recommended [16,17].

Complications after third molar extractions are reported to be more frequent than complications for other teeth extractions, particularly for wound infection and loss of sensibility [18].

A correct pre-surgical planning and a proper knowledge of the teeth's position and its contact with other anatomic structures could prevent these complications reducing the incidence, particularly of nerve damage, for these reasons CBCT may help surgeons because it is a [19,20].

When the third molar root is impacted into the cortical portion of the lingual side of the inferior jaw, the incidence of complications may increase such as the lingual nerve could be damaged, the portion of the root impacted in the bone could fracture and/or even the lingual cortical bone may fracture [21]. According to the results of the present study, the root is more frequently positioned near the lingual portion of the bone or in direct contact with it when the OPG shows a band like radiolucent area corresponding to the apical portion of the inferior third molar root with an odds ratio of 32.8 (Figure 3) confuting the null hypothesis proposed. The distance between these two structures in the control group is in line with other studies [12,22,23].

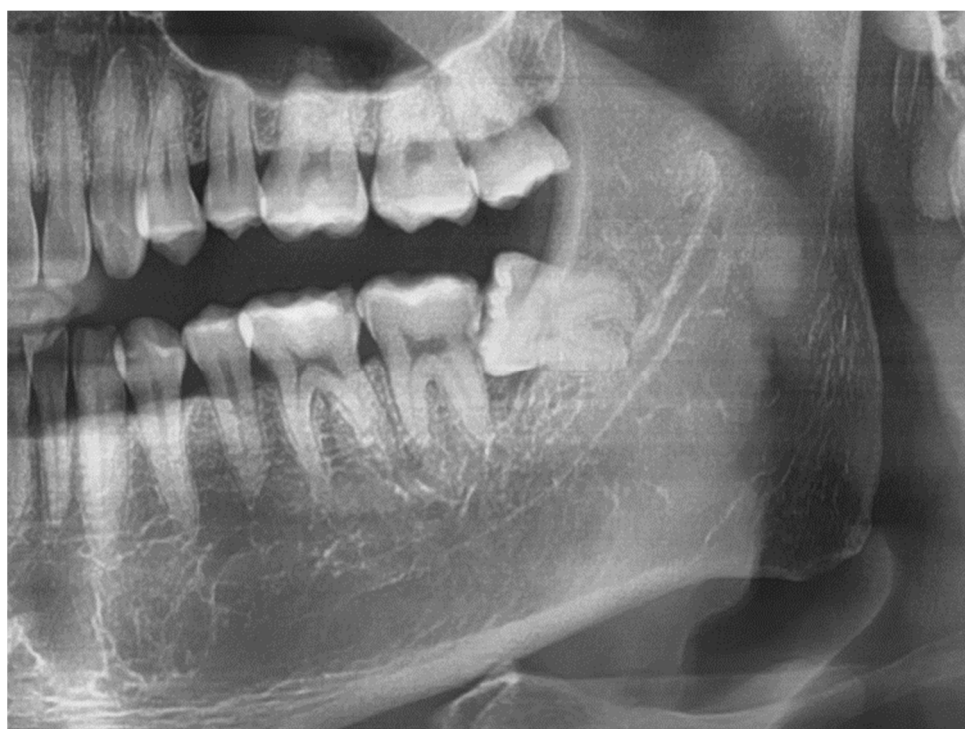

Figure 3. Patient 1801222 with a Y-sign corresponding to wisdom tooth 3.8 in the OPG.

Still, a radiolucent area does not always correspond to the proximity between root and cortical lingual bone. For these reasons, CBCT may be useful to verify the anatomic position of the third molar (Figure 4). The stratification of patients in the D-group (with a dark sign in OPG) was performed using CBCT to make a differential diagnosis and help clinicians to have as much information as possible OPG classifying subjects with no sign of pathologies that could explain the radiolucent area in the apical portion of the root of the inferior wisdom tooth, and subjects with possible pathologies.

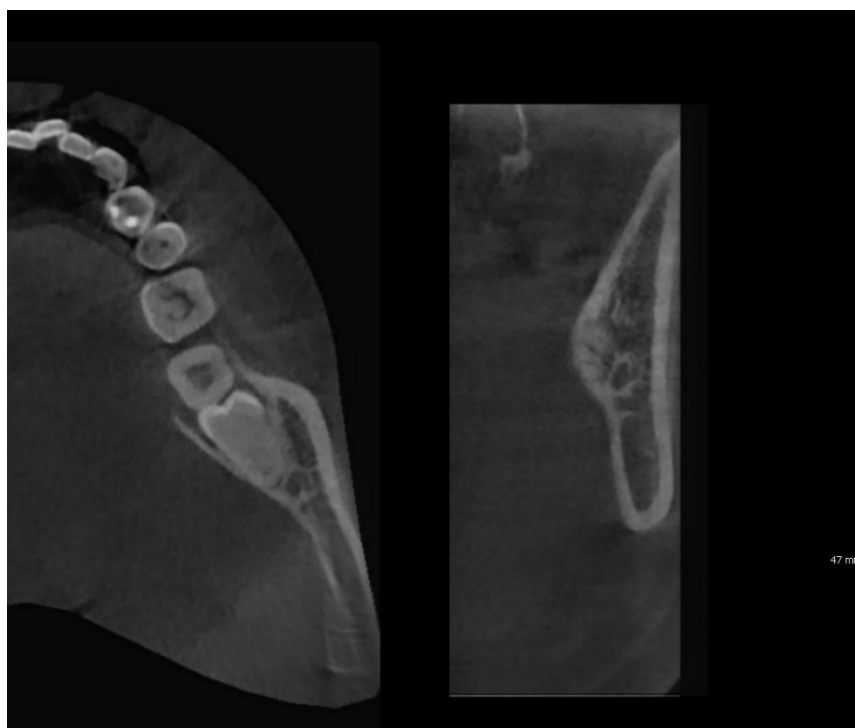


Figure 4. Patient 1801222, the CBCT confirms the nearness of the root of the wisdom tooth with the lingual cortical plate with an impaction of -1 mm. Axial plan on the left and cross-section plan on the right.

This radiolucency in “Y-sign” occurs because if the third molar root is positioned in proximity with the cortical bone, in fact, we could name this sign as “Periapical Band-Like Radiolucent Sign” possible due to its periodontal ligament impacts the lingual plate and the bone in that slight area resorbs. When this is visible in OPG, the probability to have a closeness between root and lingual cortical bone is extremely high.

After the stratification of the D-group according to the presence of Pathology (Yes) or not (No), the results significantly showed that, in 90.91% of suspected dark areas, third molar roots are close to the lingual cortical bone if there are no other pathologies. When the periapical band-like radiolucent sign is identified in OPG, there are useful clinical implications, instead, a dark area in OPG usually can also represent a pathology of the tooth or surrounding tissue.

There are other OPG signs reported in the literature strongly associated with nerve damages and surgical risks such as JAR; Peri-apical lesion; Immature apex; Inferior Alveolar Nerve (IAN) impaction into the lingual plate; apex impaction into the buccal plate [24]. This last case is reported to be very similar in OPG because it interests the buccal cortical bone, but it was not evidenced in CBCT in the present study in 228 patients, so that may be extremely rare. In some cases, the pathology is evident, and the differential diagnosis of Y-sign must be done with JAR translucency and IAN impaction.

JAR is a radiolucent area positioned laterally to the root or the apex of inferior third molars [25]. This radiological aspect of bone has been reported to be related to a variation of trabecular bone, or an ectasia of periodontal ligament and its relations with surrounding structures using CBCT.

Clinical studies showed a significant relationship between the JAR and the mandibular canal, but it is most commonly detected superiorly to the mandibular canal (59% of cases). It is reported to be mostly mesial to the tooth (43%) and above the third molars (55%), extremely rare lingual to the tooth (3%), and at the disto-angular third molar (3%) ($p = 0.005$) [26].

In these last cases, it could be misunderstood with “Y-sign” which is mostly an apical radiolucency and without pathologies. The presence of pathology is one other important

variable in the differential diagnosis because this sign could be misinterpreted as a periapical lesion. Some authors reported the diagnostic accuracy of OPG and CBCT for the detection of apical periodontal lesions, even though clinical confirmation is always needed [27].

Of 249 OPG meeting the inclusion criteria of this study, twenty-one were excluded due to radiological artifacts and exclusion criteria, this aspect could be one limitation of the present analysis that makes this retrospective study less exploitable in daily practice.

One other limitation of the present study could be that the cut-off points of -1 mm were a merely clinical decision because less impaction is not a surgical risk, and it could be no appreciable in OPG. Future studies could change the results of Y-sign if the definition of impaction is different. Moreover, in the D-group the stratification Yes (pathology) and No (no pathologies) showed that in some cases also pathological teeth could be strictly near to the lingual plate and have the “Y-sign” too and it may be difficult to highlight the sign. The dark sign seems to be strongly associated with the root impaction on the lingual cortical bone, but the absence of any dark sign could bring to a false negative because in 14.58% of C-group cases there was a nearness between these two structures.

The present study highlighted the importance of evaluating all radiological signs in OPG, a tool particularly useful for making diagnoses and reducing the use of CBCT and, in line with previous studies when there are these radiolucent signs of uncertain causes (JAR, or this sign proposed), a CBCT is the only instrumental examination for dental surgeons to analyze wisdom tooth position OPG [28,29].

In some countries, it could be a medical-legal issue to not require the CBCT in case of doubts before third molars extraction, especially if complications occur. In other countries, the CBCT is not mandatory for dental implant placement in mandible or wisdom tooth extraction [30].

Nevertheless, for general dentists, the CBCT may be still more difficult to be read than the OPG, CBCT has a higher radiation dose, it is more expensive, and not all dental clinics are equipped to offer this service. Each time a patient receives has a radiological exam carried out, millions of photons transit through the body and may bring a series of reactions that in some cases can be very dangerous. Before performing any OPG/CBCT, the relationship between risk to the patients and potential benefit must be taken into account. These findings may be useful for new guidelines to reduce CBCT prescription in inferior third molar surgery planning considering the previously mentioned principles of justification and optimization, respectively.

5. Conclusions

A new periapical band-like radiolucent sign in OPG seems to be associated with the proximity of the mandibular third molar root to the lingual cortical bone. This sign could help clinicians in the decision-making process to prescribe or not a CBCT exam to predict the real position of wisdom teeth in space and anatomic rapport. Other prospective clinical studies with larger examples are needed to confute this finding.

Author Contributions: Conceptualization, S.C. and Y.-S.K.; methodology, S.C. and Y.-M.P.; software, Y.-M.P. and Y.-S.K.; validation, S.M. and U.C.; formal analysis, A.R. and Y.-M.P.; investigation, Y.-S.K. and Y.-M.P.; Surgery Y.-S.K.; resources, A.R. and Y.-S.K.; data curation, Y.-M.P. and A.R.; writing—original draft preparation, S.C. and Y.-M.P.; writing—review and editing, S.C. and E.G.; visualization, E.G. and S.M.; supervision, U.C.; project administration, S.M.; funding acquisition, Y.-S.K. All authors have read and agreed to the published version of the manuscript.

Funding: This research was supported by Tuscan Stomatologic Institute and Young Sam Kim. The work of A.R. was supported by Masaryk University grants: MUNI/IGA/1543/2020 and MUNI/A/1608/2020.

Institutional Review Board Statement: The study was conducted according to the guidelines of the Declaration of Helsinki. This is a monocentric retrospective comparative study approved by the Gangnam Academy of Wisdom tooth Extraction (GAWE).

Informed Consent Statement: Written informed consent was obtained from all subjects involved in the study to analyze retrospectively the radiographs. Written informed consent has been obtained from the patient(s) to publish this paper.

Data Availability Statement: Restrictions apply to the availability of these data. Data was obtained from [third party] and are available [from the authors / at URL] with the permission of [third party].

Acknowledgments: The authors would like to acknowledge “Istituto Stomatologico Toscano” and its director Ugo Covani, who allowed this study, setting this international team and the Young Sam Kim to have this large number of cases of wisdom teeth.

Conflicts of Interest: The authors declare no conflict of interest.

Abbreviations

CBCT	Cone-Beam Computed Tomography
ESSE	Easy Simple Safe Efficient
GAWE	Gangnam Academy of Wisdom tooth Extraction
IAN	Inferior Alveolar Nerve
JAR	Juxta-Apical Radiolucency
MR	Magnetic resonance
NICE	National Institute for Health and Care Excellence
OAC	Oroantral Communication
OPG	Orthopantomography
OR	Odds Ratio
SD	Standard Deviation
Y-sign	Periapical band-like radiolucent sign introduced by Young Sam Kim

References

1. Barraclough, J.; Power, A.; Pattni, A. Treatment planning for mandibular third molars. *Dent. Updat.* **2017**, *44*, 221–228. [[CrossRef](#)] [[PubMed](#)]
2. Kim, Y.S. *Extraction of Third Molars: Easy Simple Safe Efficient Minimally Invasive & Atraumatic*; Koonja Publishing Inc.: Seoul, Korea, 2018.
3. Dodson, T.B.; Susarla, S.M. Impacted wisdom teeth. *BMJ Clin. Evid.* **2014**, *2014*, 1302. [[PubMed](#)]
4. Rozkovicová, E.; Marková, M.; Dolejší, J. Studies on agenesis of third molars amongst populations of different origin. *Sb. Lek.* **1999**, *100*, 71–84.
5. Worrall, S.; Riden, K.; Haskell, R.; Corrigan, A. UK National Third Molar project: The initial report. *Br. J. Oral Maxillofac. Surg.* **1998**, *36*, 14–18. [[CrossRef](#)]
6. De Bruyn, L.; Vranckx, M.; Jacobs, R.; Politis, C. A retrospective cohort study on reasons to retain third molars. *Int. J. Oral Maxillofac. Surg.* **2020**, *49*, 816–821. [[CrossRef](#)]
7. Derindağ, G.; Sarica, I.; Kurtuldu, E.; Naralan, M.E.; Caglayan, F. A retrospective study: Do all impacted teeth cause pathology? *Niger. J. Clin. Pr.* **2019**, *22*, 527–533. [[CrossRef](#)] [[PubMed](#)]
8. Di Dino, B. *Atlas of Cone Beam: Volumetric 3d Images: Safety in Implantology and General Dentistry*; BDD: Monsumano Terme–Pistoia, Italy, 2011; pp. 1–275.
9. Rood, J.; Shehab, B.N. The radiological prediction of inferior alveolar nerve injury during third molar surgery. *Br. J. Oral Maxillofac. Surg.* **1990**, *28*, 20–25. [[CrossRef](#)]
10. Renton, T.; Hankins, M.; Sproate, C.; McGurk, M. A randomised controlled clinical trial to compare the incidence of injury to the inferior alveolar nerve as a result of coronectomy and removal of mandibular third molars. *Br. J. Oral Maxillofac. Surg.* **2005**, *43*, 7–12. [[CrossRef](#)] [[PubMed](#)]
11. Jung, Y.-H.; Cho, B.-H. Radiographic evaluation of third molar development in 6- to 24-year-olds. *Imaging Sci. Dent.* **2014**, *44*, 185–191. [[CrossRef](#)] [[PubMed](#)]
12. Vidya, K.C.; Mallik, A.; Waran, A.; Rout, S.K. Measurement of lingual cortical plate thickness and lingual position of lower third molar roots using cone beam computed tomography. *J. Int. Soc. Prev. Community Dent.* **2017**, *7*, S8–S12. [[CrossRef](#)]
13. Steed, M.B. The indications for third-molar extractions. *J. Am. Dent. Assoc.* **2014**, *145*, 570–573. [[CrossRef](#)] [[PubMed](#)]
14. Feragalli, B.; Rampado, O.; Abate, C.; Festa, F.; Stromei, F.; Caputi, S.; Guglielmi, G.; Macri, M. Cone beam computed tomography for dental and maxillofacial imaging: Technique improvement and low-dose protocols. *La Radiol. medica* **2017**, *122*, 581–588. [[CrossRef](#)] [[PubMed](#)]
15. Stacchi, C.; Daugela, P.; Berton, F.; Lombardi, T.; Andriulionis, T.; Perinetti, G.; Di Lenarda, R.; Juodžbalys, G. A classification for assessing surgical difficulty in the extraction of mandibular impacted third molars: Description and clinical validation. *Quintessence Int.* **2018**, *49*, 745–753. [[PubMed](#)]

16. Cosola, S.; Kim, Y.; Park, Y.; Giammarinaro, E.; Covani, U. Coronectomy of Mandibular Third Molar: Four Years of Follow-Up of 130 Cases. *Med.* **2020**, *56*, 654. [[CrossRef](#)]
17. Cervera-Espert, J.; Pérez-Martínez, S.; Cervera-Ballester, J.; Peñarrocha-Oltra, D.; Peñarrocha-Diago, M. Coronectomy of impacted mandibular third molars: A meta-analysis and systematic review of the literature. *Med. Oral Patol. Oral Cir. Bucal* **2016**, *21*, e505–e513. [[CrossRef](#)]
18. Miclotte, I.; Agbaje, J.; Spaey, Y.; Legrand, P.; Politis, C. Incidence and treatment of complications in patients who had third molars or other teeth extracted. *Br. J. Oral Maxillofac. Surg.* **2018**, *56*, 388–393. [[CrossRef](#)]
19. Harada, N.; Vasudeva, S.; Joshi, R.; Seki, K.; Araki, K.; Matsuda, Y.; Okano, T. Correlation between panoramic radiographic signs and high-risk anatomical factors for impacted mandibular third molars. *Oral Surg.* **2013**, *6*, 129–136. [[CrossRef](#)]
20. Glera-Suárez, P.; Soto, D.; Peñarrocha-Oltra, D.; Peñarrocha-Diago, M. Patient morbidity after impacted third molar extraction with different flap designs. A systematic review and meta-analysis. *Medicina Oral Patología Oral y Cirugía Bucal* **2020**, *25*, e233–e239. [[CrossRef](#)]
21. Aydın, Z.U.; Bulut, D.G. Relationship between the anatomic structures and mandibular posterior teeth for endodontic surgery in a Turkish population: A cone-beam computed tomographic analysis. *Clin. Oral Investig.* **2019**, *23*, 3637–3644. [[CrossRef](#)] [[PubMed](#)]
22. Kim, S.-Y.; Yang, S.-E. Cone-Beam Computed Tomography Study of Incidence of Distolingual Root and Distance from Distolingual Canal to Buccal Cortical Bone of Mandibular First Molars in a Korean Population. *J. Endod.* **2012**, *38*, 301–304. [[CrossRef](#)] [[PubMed](#)]
23. Zhang, X.; Xu, N.; Wang, H.; Yu, Q. A Cone-beam Computed Tomographic Study of Apical Surgery-related Morphological Characteristics of the Distolingual Root in 3-rooted Mandibular First Molars in a Chinese Population. *J. Endod.* **2017**, *43*, 2020–2024. [[CrossRef](#)] [[PubMed](#)]
24. Nascimento, E.H.L.; Oenning, A.C.C.; Nadaes, M.R.; Ambrosano, G.M.B.; Haiter-Neto, F.; Freitas, D.Q. Juxta-apical radiolucency: Relation to the mandibular canal and cortical plates based on cone beam CT imaging. *Oral Surgery, Oral Med. Oral Pathol. Oral Radiol.* **2017**, *123*, 401–407. [[CrossRef](#)] [[PubMed](#)]
25. Nascimento, E.H.L.; Oenning, A.C.C.; Nadaes, M.R.; Ambrosano, G.M.B.; Haiter-Neto, F.; Freitas, D.Q. Juxta-Apical Radiolucency: Prevalence, Characterization, and Association With the Third Molar Status. *J. Oral Maxillofac. Surg.* **2018**, *76*, 716–724. [[CrossRef](#)] [[PubMed](#)]
26. Yalcin, E.; Artas, A. Juxta-apical radiolucency and relations with surrounding structures on cone-beam computed tomography. *Br. J. Oral Maxillofac. Surg.* **2020**, *58*, 309–313. [[CrossRef](#)] [[PubMed](#)]
27. Nardi, C.; Calistri, L.; Pradella, S.; Desideri, I.; Lorini, C.; Colagrande, S. Accuracy of Orthopantomography for Apical Periodontitis without Endodontic Treatment. *J. Endod.* **2017**, *43*, 1640–1646. [[CrossRef](#)] [[PubMed](#)]
28. Nardi, C.; Talamonti, C.; Pallotta, S.; Saletti, P.; Calistri, L.; Cordopatri, C.; Colagrande, S. Head and neck effective dose and quantitative assessment of image quality: A study to compare cone beam CT and multislice spiral CT. *Dentomaxillofacial Radiol.* **2017**, *46*, 20170030. [[CrossRef](#)] [[PubMed](#)]
29. Nascimento, E.H.L.; Oenning, A.C.C.; Freire, B.B.; Gaêta-Araujo, H.; Haiter-Neto, F.; Freitas, D.Q. Comparison of panoramic radiography and cone beam CT in the assessment of juxta-apical radiolucency. *Dentomaxillofacial Radiol.* **2018**, *47*, 20170198. [[CrossRef](#)] [[PubMed](#)]
30. Luangchana, P.; Pornprasertsuk-Damrongsri, S.; Kiattavorncharoen, S.; Jirajariyavej, B. Accuracy of linear measurements using cone beam computed tomography and panoramic radiography in dental implant treatment planning. *Int. J. Oral Maxillofac. Implant.* **2015**, *30*, 1287–1294. [[CrossRef](#)] [[PubMed](#)]