



Case Report

Skin-Reducing Mastectomy and Immediate Reconstruction for a Large Recurrent Borderline Phyllodes Tumor

Daciana Grujic ^{1,2}, Horia Cristian ³, Teodora Hoinoiu ^{2,4,*} , Codruta Diana Miclaus ⁵, Simona Cerbu ⁶,
Ljubisa Grujic ² and Cristina Oprean ^{7,8} 

- ¹ Department of Plastic, Reconstructive and Burn Surgery, “Victor Babeș” University of Medicine and Pharmacy, Eftimie Murgu Sq. No. 2, 300041 Timișoara, Romania; dcalistru@yahoo.com
 - ² Clinic of Burns, Plastic and Reconstructive Surgery, “Pius Branzu” Emergency County Hospital, Liviu Rebreanu Bld. No. 156, 300723 Timișoara, Romania; grujicmlj@yahoo.com
 - ³ Department of Emergency Surgery, “Victor Babeș” University of Medicine and Pharmacy, 300041 Timișoara, Romania; cristian.horia@gmail.com
 - ⁴ Department of Clinical Practical Skills, “Victor Babeș” University of Medicine and Pharmacy, Eftimie Murgu Sq. No. 2, 300041 Timișoara, Romania
 - ⁵ Department of Surgical Oncology, “Victor Babeș” University of Medicine and Pharmacy, Eftimie Murgu Sq. No. 2, 300041 Timișoara, Romania; codrutamiclaus@yahoo.com
 - ⁶ Discipline of Radiology and Medical Imaging, “Victor Babeș” University of Medicine and Pharmacy, Eftimie Murgu Sq. No. 2, 300041 Timișoara, Romania; cerbusimona@yahoo.com
 - ⁷ Department of Morphopathology, “Victor Babeș” University of Medicine and Pharmacy, Eftimie Murgu Sq. No. 2, 300041 Timișoara, Romania; coprean@yahoo.com
 - ⁸ Department of Oncology—ONCOHELP Hospital, Ciprian Porumbescu street, No. 59, 300239 Timișoara, Romania
- * Correspondence: tstoichituiu@umft.ro; Tel.: +40-256-216510

check for
updates

Citation: Grujic, D.; Cristian, H.; Hoinoiu, T.; Miclaus, C.D.; Cerbu, S.; Grujic, L.; Oprean, C. Skin-Reducing Mastectomy and Immediate Reconstruction for a Large Recurrent Borderline Phyllodes Tumor. *Appl. Sci.* **2021**, *11*, 1224. <https://doi.org/10.3390/app11031224>

Academic Editor: Szerb
Elisabeta Ildyko

Received: 17 December 2020
Accepted: 26 January 2021
Published: 29 January 2021

Publisher’s Note: MDPI stays neutral with regard to jurisdictional claims in published maps and institutional affiliations.



Copyright: © 2021 by the authors. Licensee MDPI, Basel, Switzerland. This article is an open access article distributed under the terms and conditions of the Creative Commons Attribution (CC BY) license (<https://creativecommons.org/licenses/by/4.0/>).

Abstract: Background: Large recurrent phyllodes breast tumors are often malignant. Therefore, when taking the surgical decision, a simple mastectomy and immediate reconstruction must be considered. Case presentation: The patient, aged 40 years, with a benign phyllodes tumor in the left breast, having a recurrence 2 years after, with 4–7 cm conglomerate tumor masses, was subjected to skin-reducing mastectomy, breast reconstruction with a silicone mammary implant in the left breast, and symmetrization of the right breast. Discussion and conclusions: In the case of patients with breast hypertrophy and gigantomastia (cup size D–F), skin-reducing mastectomy and immediate reconstruction with an implant can be the option. It is important for the resection specimen to include the skin tissue above the tumor. After 14 months of follow-up, there was no recurrence of the lesions on a clinical examination, ultrasonography, or MRI.

Keywords: phyllodes tumor; breast; surgical margins; skin-reducing mastectomy; DTI; immediate reconstruction

1. Introduction

Initially described by Johannes Muller in 1838 as “cystosarcoma phyllodes” [1], the phyllodes tumor (PT) accounts for 0.3–1% of the mammary tumors and 2–3% of the malignant fibroepithelial lesions of the breast [2,3] in middle-aged affected women (age between 40 and 50 years) [4,5]. The name is derived from the Greek phyllon (leaf) due to its lobed histological appearance. Clinically, the size of the tumor varies between 4 and 7 cm on average with a rapid radial growth, initially compressing the adjacent breast parenchyma. First, a false capsule is formed through which the tumor expands and grows, invading the rest of the healthy breast tissue. According to the WHO, phyllodes tumors are classified into benign, borderline, and malignant tumors [6] taking into account the histological criteria: Degree of stromal cellularity, stromal cell atypia, mitotic activity, degree of stromal growth, and damage to tumor margins [7,8]. Borderline phyllodes tumors account for 16.1% and malignant phyllodes tumors account for 9.3% of the total phyllodes tumors. However, the

boundary between the two types is difficult to differentiate and the recurrence rate varies between 12.8 [9] and 40% [10]. A delayed treatment may increase the risk of metastases (25–31%) through the bloodstream, rarely through the lymph system, due to the rapid progression of the disease [11].

The NCCN (National Comprehensive Cancer Network) guidelines largely recommend the excision of tumors exceeding 1 cm, without an axillary dissection, while for invasive cancer they indicate that margins free of tumor are enough (no tumor on ink) [12]. A surgical removal is the primary treatment for PT, given that adjuvant treatments play a poorly efficient role in this malignancy. A successful surgical treatment means that local recurrences are absent. In the case of tumors exceeding 10 cm and spreading on more than half of the breast volume, mastectomy and immediate reconstruction are recommended. Lymphatic node metastasis is quite rare and the metastatic path relies mainly on the blood.

2. Case Presentation

The 40-year-old Caucasian patient, from the urban area, with a family history of breast cancer (mother with undocumented malignant breast cancer), with associated obesity BMI = 30, non-smoker, was presented to the doctor in April 2016 for the onset of tumor formations in the left breast.

The clinical and ultrasound examination (Philips iU22; Philips Medical Systems, Inc., Bothell, WA, USA), corroborated by mammography (Selenia Dimensions Mammography System; Hologic Corporation, Bedford, MA, USA) and magnetic resonance imaging (GE Healthcare MRI 1.5T Chicago, IL, USA) have resulted in the identification of multiple tumor formations in both breasts, with sizes up to 6 cm, BI-RADS 4a [13] in the upper interior quadrant (UIQ) of the left breast (Figure 1).

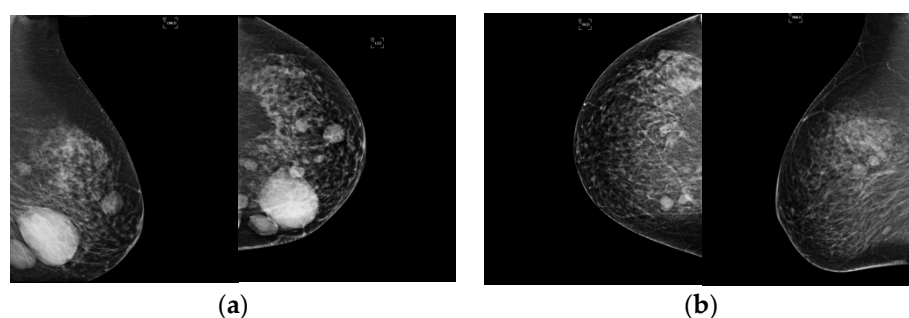


Figure 1. A 40-year-old woman with multiple tumor formations of both breasts on mammography. (a) Mammography left breast—Mediolateral oblique view (MLO) and craniocaudal (CC). (b) Mammography right breast—MLO and CC.

On palpation, the tumor formations had a mobile mass, firm in consistency, and imprecisely delimited, approximately the size of 6×3 cm with no adherence to the skin or fixity to the posterior wall involving the upper interior quadrant (UIQ), slightly painful, with a slow growth over time, approximately 1 cm in 6 months. In addition, all the vital signs were stable. All the laboratory and biochemical parameters along with a systemic examination were within the physiological limit. Her menarche was at 13 years with a regular menstrual cycle. At the time of the examination, both axillary regions were free of adenopathies that could be detected on palpation. Prior surgery and a biopsy from the UIQ of the left breast was done, which revealed the diagnosis of fibroadenoma. Surgery was performed at the level of the left breast, and, during surgery, three tumors were found with sizes between 3 and 6 cm, closely connected, well delimited, with an appearance suggestive of benignity, which is why it was decided to carry out an UIQ quadrantectomy. The surgical gross specimen exhibited a poorly circumscribed, reddish brown soft-to-firm tumor with hemorrhagic areas.

The histopathological diagnosis highlighted a biphasic benign tumor proliferation with a stromal and an epithelial component, with a lobular appearance consisting of excre-

tory ducts lined with epithelial cells without cyto-nuclear atypia, most with a collapsed lumen, with an elongated morphology, some ramified, having in some areas, the appearance of “deer horns”, peripherally surrounded by myoepithelial cells. The left tumor proliferation shows an intracanalicular growth. The above-mentioned excretory ducts are arranged in an expanded hypocellular stroma, with fusiform stromal cells, without cyto-nuclear atypia or mitotic activity, presenting a discrete, chronic inflammatory lymphoplasmocytic infiltrate with rare mast cells diffusely disposed in the interstitial spaces. Rare dilated ductal structures are present, some with apocrine metaplasia. The limits of surgical resection are in contact with the proliferative changes. The final anatomopathological diagnosis was peri- and intra-canalicular fibroadenoma in the upper inner quadrant of the left breast, benign phyllodes tumor with a complete resection and free negative margins of 0.4 cm, and fibrocystic breast disease.

For 2 years, the imaging monitoring (ultrasound, mammography, and MRI (every 6 months) showed a slow increase in size of the remaining bilateral breast lumps, but at the end of 2018, a rapid growth, from 1.4 to 7 cm, took place especially in the UIQ of the left breast (Figure 2). MRI findings, areas in the T2 hyposignal and diffusion restriction, were considered suspicious and framed the giant lesion from the inner quadrants of the left breast. The right breast findings revealed an area in the lower inner quadrant (LIQ) with aspects of a benign lesion. The lesion was categorized as BIRADS 4C and a histopathological examination was recommended.

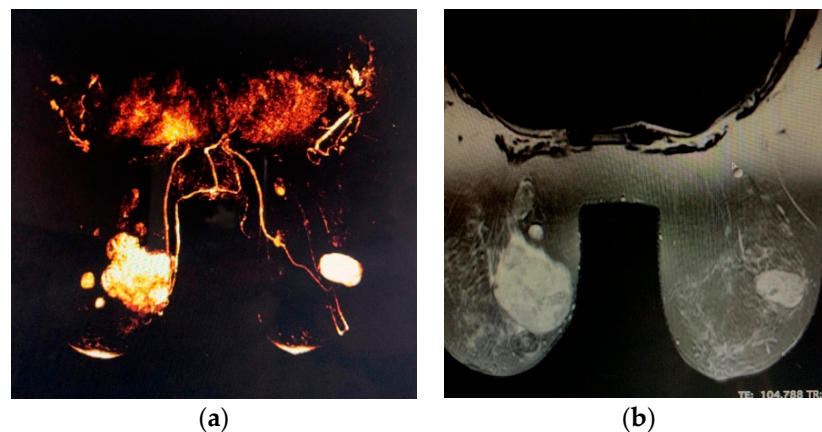


Figure 2. Giant tumor of the breast on magnetic resonance imaging (MRI), (a) three-dimensional (3D) reconstructions for lesion mapping, (b) the giant lesion at the intersections of the inner quadrants of the left breast has an inhomogeneous structure, with hyposignal zones, diffusion restriction and washout areas, and on the lower inner quadrant (LIQ) of the right breast, an area with benign tumor characteristics.

For these reasons, the patient was hospitalized for a secondary surgery without biopsy, since it was considered a local recurrence of the previous benign phyllodes tumor. Clinically, the patient presented a marked deformation of the left breast in the UIQ, with an 8 cm long postoperative scar resulting from the previous surgical intervention and a significant thinning of the skin above the tumor, with an accentuation of the superficial venous system. On palpation, a solid, painful, in-tension, mobile tumor mass could be detected (Figure 3). The chest CT and abdominal ultrasound did not show any metastases. Given the age and family medical history of breast cancer, a genetic testing for BRCA1 and BRCA2 proteins was performed showing the absence of clinically significant mutations.

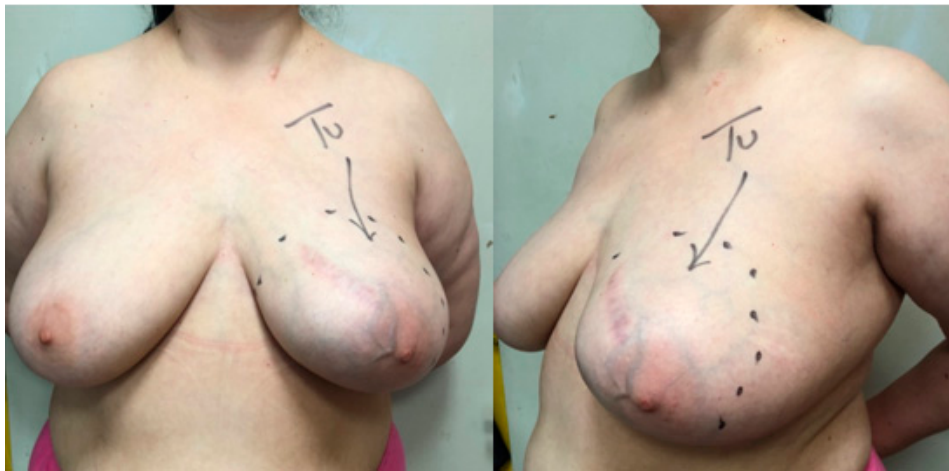

Figure 3. Preoperative images of bilateral hypertrophic breasts; the postoperative scar, enlargement and deformation of the left breast are to be noted.

The patient's status was assessed as "0", based on the criteria of the Eastern Cooperative Oncology Group [14].

Given the multifocality, bilaterality, and recurrence of the lumps, the decision was made to perform skin-reducing mastectomy on the left breast, followed by reconstruction with a 425 cc. breast implant mentor cohesive II (Mentor Medical Systems B.V., Leiden, Netherlands) inserted in a submuscular pocket formed by the pectoralis major and serratus anterior muscle, with a free nipple areola graft and symmetrization, and with the excision of the lumps in the right breast through reduction mammoplasty, inferior pedicle technique, and anchor pattern (Figure 4).

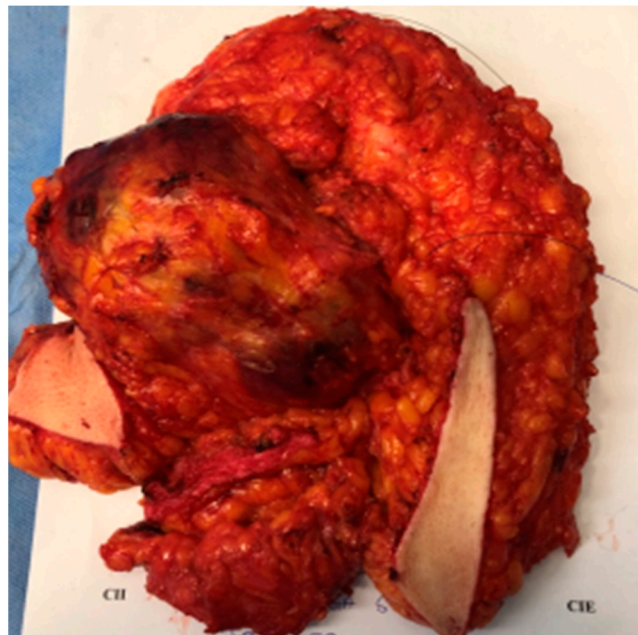


Figure 4. Macroscopic appearance of the breast PT. Excision specimen—skin-reducing mastectomy in the left breast.

The histopathological examination revealed, in the left breast, a low-grade (borderline) malignant phyllodes tumor with marked pleomorphism and an increased rate of mitosis, i.e., 7–9, associated with multiple fibroadenomas with a complex morphological picture and proliferative fibrocystic mastopathy (Figures 5 and 6), and in the right breast, fibroadenomas and proliferative fibrocystic breast disease. The tumor margins ranged between 0.4 and

0.6 cm and the pathology showed no residual Phyllodes tumor. The immunohistochemical staining performed with S100 and desmin antibody excluded a possible liposarcomatous and muscular differentiation.

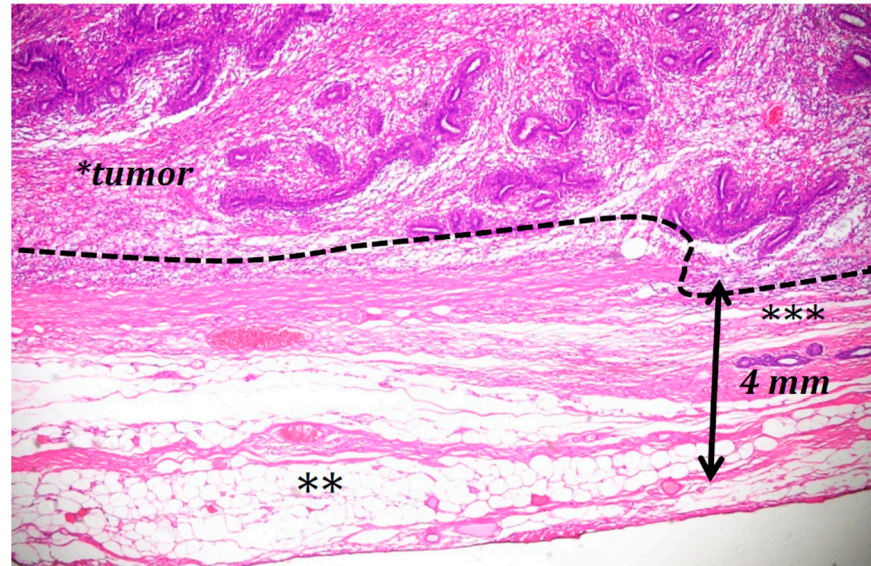


Figure 5. Borderline phyllodes tumor (*) with a negative surgical margin; the distance between the ink on the resection margin (black arrow) and tumor borders (dotted line) varying from 4 to 6 mm; the adipose tissue ** and a few normal ducts *** are present at the edge of the histological section (H&E staining).

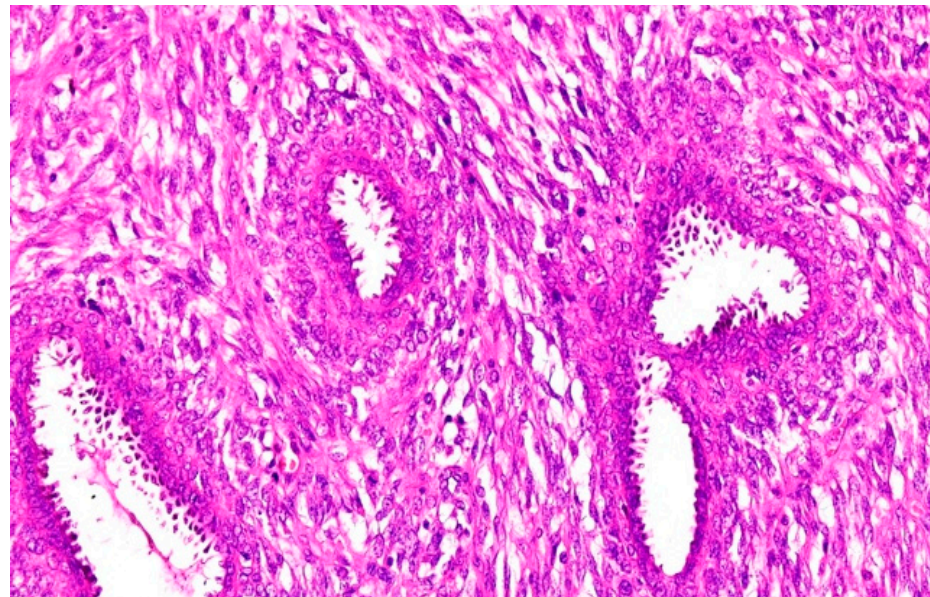


Figure 6. Borderline phyllodes tumor with moderate stromal cell atypia and stromal cell mitosis (H&E staining).

The patient was registered by the oncological department service but, due to the fact that she had margins free of disease, a low histological grade, and an immediate reconstruction with final prosthesis, radiotherapy was not indicated. A clinical follow-up after surgery was scheduled by an annual review for up to 3 years following the completion of the definitive surgical treatment. The 2019 NCCN guidelines showed that there are no randomized clinical trials proving the effectiveness of radiotherapy in this case.

After 14 months of follow-up, there was no recurrence of the lesions on a clinical examination, ultrasonography, and MRI (Figure 7).

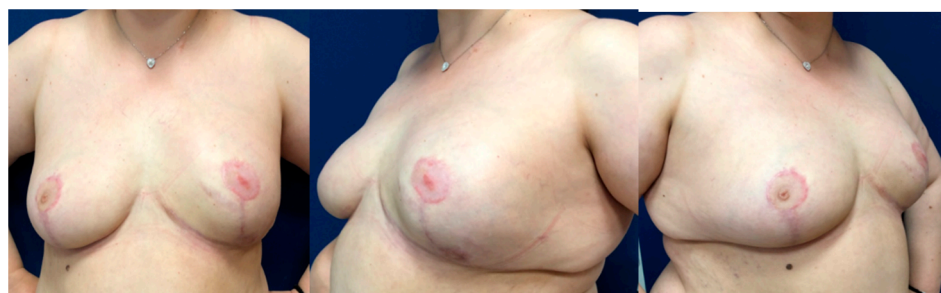

Figure 7. Appearance at 14 months after surgery.

Consent for the publication of this case report and any additional related information, including pictures, was taken from the patient.

3. Case Discussion

Due to the high incidence of fibroadenomas in all breast tumors, phyllodes tumors are often misdiagnosed and the operative time is delayed. The fact that, most of the time, tumor masses are not painful, makes patients neglect treatment and delay their presentation to the doctor. The rapid growth of the tumor, with breast deformation, is the reason that makes patients seek medical assistance. The etiology of these tumors remains unknown. Studies show that the left breast is possible to be more affected than the right one [15]. An ultrasound and mammography may raise the suspicion of a phyllodes tumor, although studies show that 20% of the phyllodes tumors are diagnosed by the screening mammography [16]. More recently, the mammographic texture analysis has provided information on how to differentiate benign phyllodes tumors from G2/G3 malignant tumors and may be useful for planning surgery [17]. Tumors are usually multinodular, and may turn into multicenter, mobile, painless tumor masses with sizes larger than 4.1 cm, and well-defined margins [18]. Tumors larger than 10 cm are considered giant tumors, being found in 20% of the total phyllodes tumors [19]. Tumors measuring more than 30 cm have also been reported. Some cases identified in men have also been published [20].

The fine needle biopsy, even ultrasound-guided, is inconclusive due to the false negative results. The core-needle biopsy is much more reliable, but it also has a rate of false-negative results as high as 25–30% [21–23]. It is difficult to differentiate fibroadenomas from the phyllodes tumor by biopsy, as it is impossible to assess whether tumor margins are perfectly circumscribed or have irregularities, with both tumors having the same characteristics of increased stromal cellularity. Moreover, the distinction between benign and borderline phyllodes tumors based on microscopic characteristics may be subjective [24]. An histopathological diagnosis of malignant phyllodes tumors is based on the presence of a marked stromal cellularity, cell atypia, infiltrative margins, and an intense mitotic activity of at least 10/10 high-power fields (HPF), compared to the borderline ones which do not exceed 7–9 mitoses/10 HPF. The literature shows a higher percentage of malignant phyllodes tumors in the case of recurrences [25].

The tumor growth can also be influenced by trauma, lactation, an increase in the estrogenic activity, and an increased endothelin-1 level [26]. The genetic mutations (TP53) in the Li-Fraumeni syndrome are also present in patients with phyllodes tumors, suggesting the possibility of a genetic predisposition [27]. So far, no immunological marker has been identified to distinguish between benign and malignant tumors. For more difficult cases, the Ki67 labeling index and p53 immunohistological staining, along with the EGFR and c-Kit expression, increased the number of chromosomal gains (e.g.4q12), 9p deletion (loss of a p 16INK4a), stromal p16 and stromal/epithelial pRb expression, methylation of RASSF1A and TWIST, which proved to be useful, but much more studies are necessary to predict a clinical behavior [28].

The gold standard treatment for phyllodes tumors is total excision with the tumor margins free of the disease, without an axillary lymph node dissection. There are authors who consider that the NCCN guidelines advocating a 1 cm margin for surgical therapy in the phyllodes tumor is an over-treatment [29].

Small tumors located in large breasts can be excised with wide safety limits, with safety margins free of the disease larger than 1 cm, and breasts can be reconstructed by oncoplastic surgery techniques. Tumors that spread on more than $1/2$ of the breast volume, which are recurrent, are candidates for total mastectomy and immediate reconstruction, usually by a tissue expander or breast implant placed at the submuscular level.

Published clinical studies, showed different opinions regarding surgical approaches to phyllodes tumors: Some recommend extensive tumor excisions, others recommend mastectomies, although it has been proven that there are no differences between the two, in terms of the recurrence rate [30–32]. A skin-reducing mastectomy is considered safe from the oncological point of view, as studies have shown no increase of local recurrence. Recurrence generally occurs 2 years after, the time being shorter in the case of malignant tumors compared to borderline and benign tumors [33]. Some studies indicate that it is necessary to perform the sentinel lymph node biopsy procedure or axillary lymphadenectomy [31]. For recurrent phyllodes tumors, the treatment is re-excision and radiotherapy. Radiotherapy is also indicated for cases with positive margins, studies showing that there are no major differences between the conservative surgery with clear margins, and positive margins tumorectomy and radiotherapy, in terms of the survival rate [34]. There are no prospective randomized data supporting the use of radiation treatment with phyllodes tumors. However, in the setting where additional recurrence would create significant morbidity (e.g., chest wall recurrence following mastectomy), radiotherapy may be considered following the same principles, which are applied to the treatment of soft tissue sarcoma [35–37].

In return, there is no protocol regarding the use of the adjuvant role of chemotherapy (doxorubicin/dacarbazine in combination with cisplatin or ifosfamide) and hormonal therapy in phyllodes tumors, which is more correlated with the histological grade and mitotic activity of the cells, suggesting that these tumors should be treated as sarcomas, rather than as carcinomas [38,39]. The 5-year survival rate for benign and borderline phyllodes tumors is 91–93.8%, and 70–82% for malignant phyllodes [19,40].

In the case presented here, the excision with negative, but probably insufficient, tumor-free margins, has led to the local recurrence and transformation into malignant phyllodes. Initially, in 2016, the patient underwent surgery in an oncological surgery department, but they did not consider the re-excision of the tumor margins. The patient came to our medical unit 2 years after, when the size of the recurrent tumor was much larger, and with the issue of a much wider excision or mastectomy with immediate reconstruction. We consider mastectomy a radical operation, therefore, the rules of wide margins of safety cannot be applied, especially since the tumor was already subtegumentary. In the case of large recurrent tumors, in which safe excision margins cannot be ensured, the best option is mastectomy. We conclude that in the case presentation of our patient, with a large, recurrent multifocal tumor, in which a mastectomy with negative excision margins and a low histological grade was performed, radiotherapy and adjuvant chemotherapy were not recommended.

4. Conclusions

Phyllodes tumors are characterized by a rapid growth, have a high potential for recurrence, as well as the potential for malignant transformation.

Large phyllodes tumors, those with onsets at an older age, and recurrent phyllodes tumors are more often associated with borderline or malignant tumors, have an indication for wide excision up to a simple mastectomy, without lymph node dissection. An accurate preoperative histopathological diagnosis allows the correct planning of surgery, with immediate breast reconstruction, when necessary, thus avoiding re-operations.

Tumor prognosis is very good if surgical excision is wide enough and adjuvant therapy is no longer necessary.

Author Contributions: Conceptualization, D.G., T.H., H.C., C.D.M., S.C., L.G., C.O.; Data curation, D.G. and T.H.; Formal analysis, C.D.M. and T.H.; Investigation, S.C. and C.O.; Methodology, D.G., T.H., H.C., C.D.M., L.G.; Project administration, L.G.; Resources, S.C. and C.O.; Software, D.G. and T.H.; Supervision, D.G., T.H., C.D.M. and L.G.; Validation T.H., D.G., C.D.M., T.H. and S.C.; Visualization, S.C.; Writing—original draft, D.G., T.H., C.D.M. and C.O.; Writing—review and editing, D.G., T.H., and H.C. All authors have read and agreed to the published version of the manuscript.

Funding: This research received no external funding.

Institutional Review Board Statement: The study was conducted according to the guidelines of the Declaration of Helsinki, and approved by the Institutional Review Board (or Ethics Committee, protocol code CLECS-2019-3, 27th of January, 2019).

Informed Consent Statement: Informed consent was obtained from subject involved in this paper.

Data Availability Statement: The data presented in this study are available on request from the corresponding author. The data are not publicly available due to ethical reasons (data being registry data).

Conflicts of Interest: The authors declare no conflict of interest.

References

- Muller, J. Uber den feinen Bau und Die Formen der Kraefte Geschwulste. *Berl. G. Reiner* **1838**, *1*, 54–57.
- Venter, A.C.; Roşca, E.; Daina, L.G.; Muşiu, G.; Pirte, A.N.; Rahotă, D. Phyllodes tumor: Diagnostic imaging and histopathology findings. *Rom. J. Morphol. Embryol.* **2015**, *56*, 1397–1402. [[PubMed](#)]
- Plaza, M.J.; Swintelski, C.; Yaziji, H.; Torres-Salichs, M.; Esserman, L.E. Phyllodes tumor: Review of key imaging characteristics. *Breast Dis.* **2015**, *35*, 79–86. [[CrossRef](#)] [[PubMed](#)]
- Salvadori, B.; Cusumano, F.; Del Bo, R.; Delledonne, V.; Grassi, M.; Rovini, D.; Saccozzi, R.; Andreola, S.; Clemente, C. Surgical treatment of phyllodes tumors of the breast. *Cancer* **1989**, *63*, 2532–2536. [[CrossRef](#)]
- Bernstein, L.; Deapen, D.; Ross, R.K. The descriptive epidemiology of malignant cystosarcoma phyllodes tumors of the breast. *Cancer* **1993**, *71*, 3020–3024. [[CrossRef](#)]
- Lakhani, S.R.; Ellis, I.O.; Schnitt, S.J.; Tan, P.H.; van der Vijver, M.J. (Eds.) *World Health Organisation Classification of Tumors of the Breast*; IARC Press: Lyon, France, 2012.
- Ang, M.K.; Ooi, A.S.; Thike, A.A.; Tan, P.; Zhang, Z.; Dykema, K.; Furge, K.; Teh, B.T.; Tan, P.H. Molecular classification of breast phyllodes tumors: Validation of the histologic grading scheme and insights into malignant progression. *Breast Cancer Res. Treat.* **2011**, *129*, 319–329. [[CrossRef](#)]
- Tan, P.H.; Thike, A.A.; Tan, W.J.; Thu, M.M.M.; Busmanis, I.; Li, H.; Chay, W.Y.; Tan, M.; Singapore, T.P.T.N. Predicting clinical behaviour of breast phyllodes tumours: A nomogram based on histological criteria and surgical margins. *J. Clin. Pathol.* **2012**, *65*, 69–76. [[CrossRef](#)]
- Tan, P.H.; Jayabaskar, T.; Yip, G.; Tan, Y.; Hilmy, M.; Selvajaran, S. P53 and C-Kit (CD117) protein expression as prognostic indicators in breast phyllodes tumors: A tissue microarray study. *Mod. Pathol.* **2005**, *18*, 1527–1534. [[CrossRef](#)]
- Parker, S.J.; Harries, S.A. Phyllodes tumours. *Postgrad. Med. J.* **2001**, *77*, 428–435. [[CrossRef](#)]
- Khosravi-Shahi, P. Management of non metastatic phyllodes tumors of the breast: Review of the literature. *Surg. Oncol.* **2011**, *20*, e143–e148. [[CrossRef](#)]
- National Comprehensive Cancer Network. Phyllodes tumor, version 1. 2018. Plymouth Meeting (PA). Available online: <https://www.nccn.org> (accessed on 17 December 2020).
- Sedgwick, E.L.; Ebuoma, L.; Hamame, A.; Phalak, K.; Ruiz-Flores, L.; Ortiz-Pérez, T.; Sepulveda, K.A. BI-RADS update for breast cancer caregivers. *Breast Cancer Res. Treat.* **2015**, *150*, 243–254. [[CrossRef](#)] [[PubMed](#)]
- Oken, M.M.; Creech, R.H.; Tormey, D.C.; Horton, J.; Davis, T.E.; McFadden, E.T.; Carbone, P.P. Toxicity and response criteria of the Eastern Cooperative Oncology Group. *Am. J. Clin. Oncol.* **1982**, *5*, 649–655. [[CrossRef](#)] [[PubMed](#)]
- Adamietz, B.R.; Kahmann, L.; Fasching, P.A.; Schulz-Wendtland, R.; Uder, M.; Beckmann, M.W.; Meier-Meitingner, M. Differentiation between phyllodes tumor and fibroadenoma using real-time elastography. *Ultraschall Med.* **2011**, *32* (Suppl. 2), E75–E79. [[CrossRef](#)] [[PubMed](#)]
- Macdonald, O.K.; Lee, C.M.; Tward, J.D.; Chappel, C.D.; Gaffney, D.K. Malignant phyllodes tumor of the female breast: Association of primary therapy with cause-specific survival from the Surveillance, Epidemiology, and End Results (SEER) program. *Cancer* **2006**, *107*, 2127–2133. [[CrossRef](#)]
- Cui, W.J.; Wang, C.; Jia, L.; Ren, S.; Duan, S.F.; Cui, C.; Chen, X.; Wang, Z.Q. Differentiation Between G1 and G2/G3 Phyllodes Tumors of Breast Using Mammography and Mammographic Texture Analysis. *Front. Oncol.* **2019**, *9*, 433. [[CrossRef](#)]

18. Kundes, M.F.; Cetin, K.; Kaya, S.; Kucuk, H.F. Is the surgical approach very important to treatment for phyllodes tumors? *South. Clin. Istanbul. Eurasia* **2019**, *30*, 130–134. [[CrossRef](#)]
19. Karim, R.Z.; Gerega, S.K.; Yang, Y.H.; Spillane, A.; Carmalt, H.; Scolyer, R.; Lee, C. Phyllodes tumours of the breast: A clinicopathological analysis of 65 cases from a single institution. *Breast* **2009**, *18*, 165–170. [[CrossRef](#)]
20. Bapat, K.; Oropeza, R.; Sahoo, S. Benign phyllodes tumor of the male breast. *Breast J.* **2002**, *8*, 115–116. [[CrossRef](#)]
21. Dillon, M.F.; Quinn, C.M.; McDermott, E.W.; O'Doherty, A.; O'Higgins, N.; Hill, A.D. Needle core biopsy in the diagnosis of phyllodes neoplasm. *Surgery* **2006**, *140*, 779–784. [[CrossRef](#)]
22. Lee, A.H.; Hodi, Z.; Ellis, I.O.; Elston, C.W. Histological features useful in the distinction of phyllodes tumour and fibroadenoma on needle core biopsy of the breast. *Histopathology* **2007**, *51*, 336–344. [[CrossRef](#)]
23. de Roos, W.K.; Kaye, P.; Dent, D.M. Factors leading to local recurrence or death after surgical resection of phyllodes tumours of the breast. *Br. J. Surg.* **1999**, *86*, 396–399. [[CrossRef](#)] [[PubMed](#)]
24. Tan, B.Y.; Acs, G.; Apple, S.K.; Badve, S.; Bleiweiss, I.J.; Brogi, E.; Calvo, J.P.; Dabbs, D.J.; Ellis, I.O.; Eusebi, V.; et al. Phyllodes tumours of the breast: A consensus review. *Histopathology* **2016**, *68*, 5–21. [[CrossRef](#)] [[PubMed](#)]
25. Pant, N.K.; Singh, A.; Kumar, D.; Pandey, H. A rare case of a phyllodes tumour of the breast converting to a fibrosarcoma with successful treatment. *Ecancermedicalscience* **2012**, *6*, 247. [[CrossRef](#)] [[PubMed](#)]
26. Ur Rab, A.Z.; Alim, S.S.; Wasif, M.A. Giant phyllodes tumor of breast post fibroadenoma excision: A rare case report and review of literature. *Int. J. Surg. Sci.* **2020**, *4*, 188–190. [[CrossRef](#)]
27. Toh, Y.F.; Cheah, P.L.; Looi, L.M.; Teoh, K.H.; Tan, P.H. Phyllodes tumours of the breast: Retrospective analysis of a University Hospital's experience. *Malays. J. Pathol.* **2016**, *38*, 19–24.
28. Spitaleri, G.; Toesca, A.; Botteri, E.; Bottiglieri, L.; Rotmensz, N.; Boselli, S.; Sangalli, C.; Catania, C.; Toffalorio, F.; Noberasco, C.; et al. Breast phyllodes tumor: A review of literature and a single center retrospective series analysis. *Crit. Rev. Oncol. Hematol.* **2013**, *88*, 427–436. [[CrossRef](#)]
29. Ogunbiyi, S.; Perry, A.; Jakate, K.; Simpson, J.; George, R. Phyllodes tumour of the breast and margins: How much is enough. *Can. J. Surg.* **2019**, *62*, E19–E21. [[CrossRef](#)]
30. Sotheran, W.; Domjan, J.; Jeffrey, M.; Wise, M.H.; Perry, P.M. Phyllodes tumours of the breast—a retrospective study from 1982–2000 of 50 cases in Portsmouth. *Ann. R. Coll. Surg. Engl.* **2005**, *87*, 339–344. [[CrossRef](#)]
31. Ben Hassouna, J.; Damak, T.; Gamoudi, A.; Chargui, R.; Khomsi, F.; Mahjoub, S.; Slimene, M.; Ben Dhiab, T.; Hechiche, M.; Boussen, H.; et al. Phyllodes tumors of the breast: A case series of 106 patients. *Am. J. Surg.* **2006**, *192*, 141–147. [[CrossRef](#)]
32. Kapiris, I.; Nasiri, N.; A'Hern, R.; Healy, V.; Gui, G.P. Outcome and predictive factors of local recurrence and distant metastases following primary surgical treatment of high-grade malignant phyllodes tumours of the breast. *Eur. J. Surg. Oncol.* **2001**, *27*, 723–730. [[CrossRef](#)]
33. Barrio, A.V.; Clark, B.D.; Goldberg, J.I.; Hoque, L.W.; Bernik, S.F.; Flynn, L.W.; Susnik, B.; Giri, D.; Polo, K.; Patil, S.; et al. Clinicopathologic features and long-term outcomes of 293 phyllodes tumors of the breast. *Ann. Surg. Oncol.* **2007**, *14*, 2961–2970. [[CrossRef](#)] [[PubMed](#)]
34. Reinfuss, M.; Mituś, J.; Duda, K.; Stelmach, A.; Ryś, J.; Smolak, K. The treatment and prognosis of patients with phyllodes tumor of the breast: An analysis of 170 cases. *Cancer* **1996**, *77*, 910–916. [[CrossRef](#)]
35. NCCN Clinical Practice Guidelines in Oncology (NCCN Guidelines) Breast Cancer, Version 4.2020–may 8,2020. Available online: <https://www.nccn.org/> (accessed on 17 December 2020).
36. Hoinoiu, T.; Grujic, D.; Prilipceanu, G.; Folescu, R.; Hoinoiu, B.; Bratu, T.; Poroach, V.; Grujic, L. The Use of Collagen-Glycosaminoglycan Biodegradable Matrix (Integra®) in the Management of Neck Postburn Hypertrophic Scars and Contractures. *Appl. Sci.* **2020**, *10*, 3731. [[CrossRef](#)]
37. Oprean, C.M.; Negru, S.M.; Popovici, D.I.; Saftescu, S.; Han, R.-A.; Dragomir, G.-M.; Hoinoiu, T.; Dema, A. Postmenopausal Breast Cancer in Women, Clinical and Epidemiological Factors Related to the Molecular Subtype: A Retrospective Cohort Study in a Single Institution for 13 Years. Follow-Up Data. *Int. J. Environ. Res. Public Health* **2020**, *17*, 8722. [[CrossRef](#)] [[PubMed](#)]
38. Zhou, Z.R.; Wang, C.C.; Yang, Z.Z.; Yu, X.L.; Guo, X.M. Phyllodes tumors of the breast: Diagnosis, treatment and prognostic factors related to recurrence. *J. Thorac. Dis.* **2016**, *8*, 3361–3368. [[CrossRef](#)]
39. Suzuki-Uematsu, S.; Shiraishi, K.; Ito, T.; Adachi, N.; Inage, Y.; Taeda, Y.; Ueki, H.; Ohtani, H. Malignant phyllodes tumor composed almost exclusively of a fibrosarcomatous component: A case report and review of malignant phyllodes tumors with metastases. *Breast Cancer* **2010**, *17*, 218–224. [[CrossRef](#)]
40. Chaney, A.W.; Pollack, A.; McNeese, M.D.; Zagars, G.K.; Pisters, P.W.; Pollock, R.E.; Hunt, K.K. Primary treatment of cystosarcoma phyllodes of the breast. *Cancer* **2000**, *89*, 1502–1511. [[CrossRef](#)]