applied sciences

MDPI

Article

Biomechanical Evaluation of a Novel Expandable Vertebral Augmentation System Using Human Cadaveric Vertebrae

Ming-Kai Hsieh [1], Wen-Jer Chen [1], Mel S. Lee [1], Sheng-Yu Lin [2], Mu-Yi Liu [3], De-Mei Lee [2,*] and Ching-Lung Tai [1,3,*]

[1] Department of Orthopedic Surgery, Spine Section, Bone and Joint Research Center, Chang Gung Memorial Hospital, Taoyuan 333, Taiwan
[2] Department of Mechanical Engineering, Chang Gung University, Taoyuan 333, Taiwan
[3] Department of Biomedical Engineering, Chang Gung University, Taoyuan 333, Taiwan
* Correspondence: dmlee@mail.cgu.edu.tw (D.-M.L.); taicl@mail.cgu.edu.tw (C.-L.T.)

Abstract: Unacceptable sagittal alignment and cement leakage are major concerns of percutaneous vertebroplasty when treating patients with painful vertebral osteoporotic compression fractures. To maintain the restored vertebral height and reduce the reliance on cement as the major stabilizer, an expandable vertebral augment system (EVA®) made of titanium alloy consisting of a rigid tube encased by a barrel with an anterior expansion mechanism was developed. The aim of the current study was to determine whether this novel design is as effective as existing procedures in terms of height restoration and biomechanical performance. Eight osteoporotic vertebrae (T12-L3) confirmed by dual-energy X-ray absorptiometry from two fresh-frozen human cadavers (70- and 72-year-old females) were used. Twenty-five percent reduced anterior wedge vertebral compression fractures were created using a material testing machine. Four randomized specimens were augmented with EVA® (Chang Gu Biotechnology Co. Ltd., Taipei city, Taiwan), and another four randomized specimens were augmented with OsseoFix® (AlphaTec Spine Inc., Carlsbad, CA, USA). The implant size and cement volume were controlled. The anterior vertebral body height (VBH) ratio and pre/postaugmented ultimate strength and stiffness were measured and compared. The mean anterior VBH restoration ratio was 8.54% in the EVA® group and 8.26% in the OsseoFix® groups. A significant difference from augmentation was measured in both groups ($p < 0.05$), but there was no significant difference between the EVA® and OsseoFix® groups in anterior VBH restoration. The ultimate strengths of the EVA® and OsseoFix® groups were 6071.4 ± 352.6 N and 6262.9 ± 529.2 N, respectively, both of which were statistically significantly higher than that of the intact group (4589.9 ± 474.6 N) ($p < 0.05$). The stiffnesses of the EVA®, OsseoFix®, and intact groups were 1087.2 ± 176.9, 1154.9 ± 168.9, and 1637.3 ± 340.8 N/mm, respectively, indicating that the stiffness was significantly higher in the intact group than in both the EVA® and OsseoFix® groups ($p < 0.05$). No significant differences were observed between the two augmentation procedures in height restoration or ultimate strength and stiffness. This novel EVA® system showed comparable height restoration and biomechanical performance to those of existing implants for human cadaveric osteoporotic compression fractures. Potential advantages of preventing cement posterior leakage and promoting cement interdigitation are expected with this ameliorated design.

Keywords: vertebral osteoporotic compression fracture; expandable vertebral augmentation; human cadaveric vertebrae; vertebral body height restoration ratio; mechanical test

check for updates

Citation: Hsieh, M.-K.; Chen, W.-J.; Lee, M.S.; Lin, S.-Y.; Liu, M.-Y.; Lee, D.-M.; Tai, C.-L. Biomechanical Evaluation of a Novel Expandable Vertebral Augmentation System Using Human Cadaveric Vertebrae. *Appl. Sci.* **2022**, *12*, 10165. https://doi.org/10.3390/app121910165

Academic Editor: Hanatsu Nagano

Received: 24 August 2022
Accepted: 8 October 2022
Published: 10 October 2022

Publisher's Note: MDPI stays neutral with regard to jurisdictional claims in published maps and institutional affiliations.

Copyright: © 2022 by the authors. Licensee MDPI, Basel, Switzerland. This article is an open access article distributed under the terms and conditions of the Creative Commons Attribution (CC BY) license (https://creativecommons.org/licenses/by/4.0/).

1. Introduction

Painful vertebral osteoporotic compression fractures (VCFs) occur in 20% of people over the age of 70 years and significantly impact quality of life and physical function [1,2]. Progressive kyphosis of the thoracolumbar VCF results in decreased pulmonary function, chronic pain, and poor nutritional status, and thus increases the mortality rate [3–5].

When pain persists after conservative treatment for one month, surgical solutions including percutaneous vertebroplasty with polymethylmethacrylate (PMMA) cement for pain relief or percutaneous kyphoplasty for further vertebral height restoration might be considered [6–8]. There have been three theoretical concerns about potential adverse effects with the use of these procedures: (1) Uncontrolled bone cement leakage over the venous plexus and epidural space, which can result in pulmonary embolism and neurological damage [2,9]; a cement leakage rate from percutaneous vertebroplasty reaching 69.1% was reported for the epidural space, disk space, and paraspinal tissues through defects of the fractured vertebra [9,10]. Percutaneous balloon kyphoplasty was designed to reduce the cement leakage rate during augmentation. Clinical evidence has shown a reduced cement leakage rate for kyphoplasty compared with vertebroplasty in osteoporotic cases, but the resulting devastating symptomatic complications still need to be alerted [9–14]. (2) Adverse bone union process due to thermal effect may induce inflammatory reaction and inadequate biological scaffold properties [15,16]. Although new bone formation was observed radiographically in 40% of patients who received vertebroplasty in long-term follow-up [17], histological evidence still showed a decreased quantity and quality of callus mineralization surrounding bone cement in vertebroplasty groups [18,19]. (3) Unacceptable sagittal alignment. Balloon kyphoplasty involves the inflation of a balloon inside the collapsed fractured vertebral body, which restores its height before the fracture is stabilized with cement. However, significantly restored vertebral height loss after balloon deflation worsens the reduction achievement.

To maintain the restored vertebral height and reduce the reliance on cement as the major stabilizer, an expandable titanium device, OsseoFix® (AlphaTec Spine Inc., Carlsbad, CA, USA), which was accompanied by a mechanical working system that allows progressive and controlled vertebral fracture reduction, was developed [20,21]. However, the spinal canal compression risk resulting from the retropulsed expansion mechanism limits its clinical application. An expandable titanium alloy (Ti-6Al-4V) device with an anterior expansion mechanism, EVA® (Expandable Vertebral Augment system, Chang Gu Biotechnology Co. Ltd., Taipei city, Taiwan), was developed. It consists of a rigid tube encased by a barrel that can be expanded to a desired expansive range by an externally applied compression force through an operation device. Compared with balloon kyphoplasty in which the fractured vertebrae is inflated by water/fluid filling, a mechanical advantage of the EVA® system is that the fracture reduction is achieved by the eight expanded blades via the forward-advancing novel barrel design, correcting the kyphotic deformity and compacting the surrounding trabecular bone by a multiple-bladed expansion design, thus creating a low-pressure space for cement interdigitation.

The purpose of our study was to compare the differences in height restoration and biomechanical performance between EVA® and OsseoFix® in human cadaveric osteoporotic compression fracture vertebrae and determine whether this novel design has a biomechanical advantage over existing procedures.

2. Materials and Methods

2.1. Specimen Preparation

This study was approved by the committee of Ministry of Science and Technology in Taiwan. Eight osteoporotic vertebrae were used in this study (T12 to L3) from two fresh-frozen human cadavers (70- and 72-year-old females). There was no radiographic evidence of deformity, malignancy, fracture or previous surgery of our testing specimens. To confirm that the tested specimens were osteoporotic, vertebrae were selected with anteroposterior (AP) bone mineral density (BMD) measurements (DXA, QDR 2000, Hologic, Inc., Boston, MA, USA) of less than 0.7 g/cm^2 [22]. All vertebrae were disarticulated, and their surrounding soft tissues were removed before mechanical compression.

2.2. Fracture Generation

All specimens were thawed at room temperature for 24 h before testing. The end plates of each vertebra were embedded in a common epoxy resin (Fastray, Bosworth, Skokie, IL, USA). Anterior vertebral body height (VBH) was measured at the anterior aspect of the vertebral body with a digital caliper with an accuracy of 0.01 mm (Model PB-1B, Mitutoyo, Tokyo, Japan). The measured VBH values were defined as the initial height of intact vertebra for the subsequent calculation of the VBH ratio. Following intact VBH measurement, a compressive preload of 89 N was applied for 2 min [23]. To create a wedge compression of the anterior half of the vertebral body, the main vector of the axial force was centered at the end plate of the anterior fourth of the vertebral body [24]. Each vertebra was compressed at a rate of 5 mm/min using a hinged-plated device mounted on a material testing machine (Bionix 858; MTS Systems Corp., Minneapolis, MN, USA) to create an anterior wedge fracture and reduce anterior height by 25% of the initial value. To protect the posterior wall from compression fracture, the specimen was completely contacted with the custom-made resin apparatus (Figure 1). Force (N) and displacement (mm) data were recorded at 10 Hz, and the ultimate strength and stiffness of the specimens were recorded as intact groups and compared with the two following augmented groups. Ultimate strength was defined as the highest load value with increasing compression, which is the turning point on the force versus displacement curve. Compression stiffness was arbitrarily defined as the slope of the force-displacement curve between 500 N and 1500 N [25,26]. The specimens were returned to the plastic bags and floated in a bath maintained at 37 °C for at least 1 h before augmentation.



Figure 1. Photograph showing the experimental setup of the compression test. The main vector of the axial force was centered at the end plate of the anterior fourth of the vertebral body to create wedge compression of the anterior vertebral body.

After fractures were created by mechanical compression, all specimens from T12 to L3 were randomly allocated into two treatment groups: the EVA® group (n = 4) and the OsseoFix® group (n = 4).

2.3. Implantation of EVA®

An EVA® was made of titanium alloy (Ti-6Al-4V) and consisted of a rigid central hollow tube equipped with a barrel with eight expandable blades (length × diameter, 20 mm × 6 mm). The eight blades were gradually expanded following the forward advancing of the barrel relative to the central tube by the clockwise rotation of the expander handle (Figure 2). The EVA® operation device has multiple apertures for delivering PMMA bone cement to the expanded barrel through a long cannulated sheath. Following the full expansion of the EVA® device (length × diameter, 17 mm × 13.5 mm), the barrel component formed of eight expanded blades is capable of structurally supporting the damaged bone, and the hollow tube allows cement to be injected through its central tunnel (Figure 3).

For all specimens in the EVA® group, a channel was created for placement of the EVA® device using a 5.5 mm diameter drill bit through the left pedicle. The procedures were carried out fluoroscopically to confirm adequate position and expansion were achieved. Following the implantation of the EVA® device, the expander handle of the operation device was removed, and the cement injection apertures to be filled with PMMA bone cement (Simplex P, Stryker, Kalamazoo, MI, USA) were assembled into the EVA operation device. PMMA cement (3cc) was injected into the vertebral body by the clockwise rotation of the cement injection handle, and after the cement had hardened completely, the EVA® operation device was rotated counterclockwise to disconnect it (Figure 3).

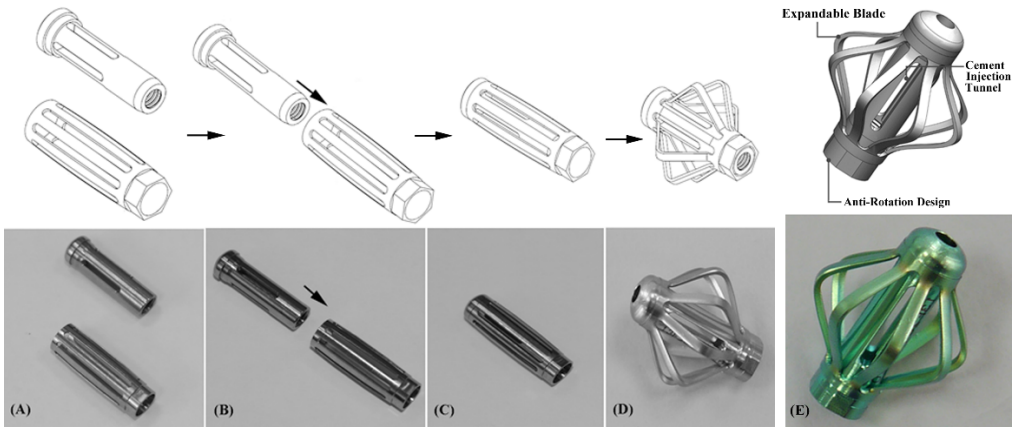

Figure 2. Schematic drawing (upper) and photograph (lower) showing the EVA® device. (**A**) EVA® including a rigid tube component and a barrel component before assembly; (**B**) assembling the tube into the barrel; (**C**) after assembly of tube and barrel (unexpanded EVA®); (**D**) expanded EVA®; and (**E**) following the expansion of EVA® using an operation device, the barrel component forms eight expanded blades capable of providing structural support to the bone tissue, and the tube tunnel allows cement to be injected through its central tunnel.

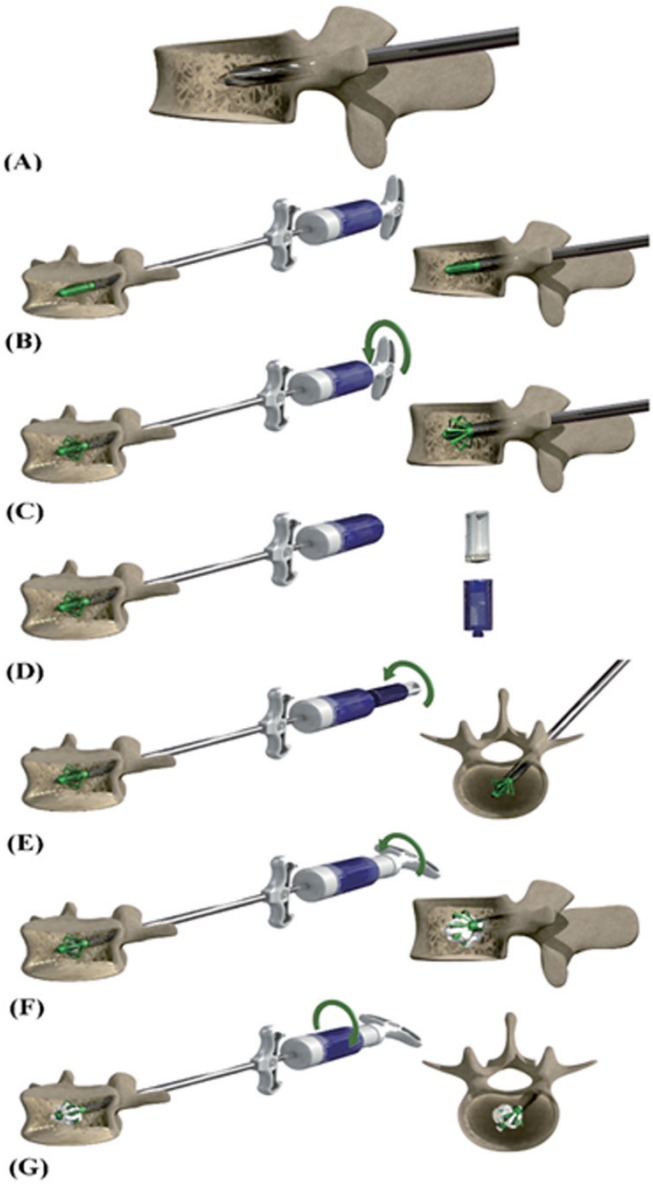

Figure 3. Schematic drawing showing the surgical procedure of EVA® implantation. (**A**) Rotating the bone drill to drill into the desired position of vertebral body; (**B**) inserting the EVA® implant into the vertebral body with the EVA® operation device; (**C**) rotating the expander handle to expand the EVA® implant. A fluoroscope was used to ensure the implant's position and expansion; (**D**) the expander handle was completely unscrewed to disengage it. The cement injection syringe was filled with the cement mixture; (**E**) the cement injection syringe was insert into the EVA® operation device, and the cement injection handle was attached to the EVA® operation device; (**F**) the cement injection handle was rotated to inject the cement; and (**G**) the EVA® operation device was rotated counterclockwise to disassemble the system and complete the procedure.

2.4. Implantation of OsseoFix®

A same-sized drill bit with the same tract under fluoroscopic control in two planes was also used in the OsseoFix® group. The implant consisted of a combination of titanium alloy (Ti-6Al-4V) and pure titanium (Ti-CP2) [27,28]. With a similar size as the EVA groups, i.e., an initial length×diameter size of 30 mm × 5.5 mm and maximally expanded size to 26.4 mm × 13.0 mm, OsseoFix® devices were implanted in all 4 vertebrae in the OsseoFix® group. After the inserted OsseoFix® devices were fully expanded by the delivery system,

3 cc PMMA liquid cement was injected. After the cement hardened, the delivery system was disconnected and removed.

Following implantation of EVA® or OsseoFix® devices, the postaugmentation anterior VBH was measured with an identical method to that previously described. The preaugmentation and postaugmentation anterior VBH ratios in both groups were measured and compared.

The pre- and postaugmentation anterior VBH ratios are defined as follows:

$$\text{Preaugmentation VBH ratio} = (\text{Fractured VBH})/(\text{Intact VBH}) \times 100\%$$

$$\text{Postaugmentation VBH ratio} = (\text{Postaugmentation VBH})/(\text{Intact VBH}) \times 100\%$$

2.5. Biomechanical Testing

Postaugmentation specimens were thawed at room temperature (20 °C) for 24 h before biomechanical testing. An impression of the end plates of each vertebra was made with a common epoxy resin (Fastray, Bosworth, Skokie, IL, USA) (Figure 1). Each vertebra was seated between its respective impressions and placed between platens on an MTS materials testing machine (Bionix 858; MTS Systems Corp., Minneapolis, MN, USA). A compressive preload of 89 N was applied for 2 min. Subsequently, vertical uniaxial compressive force was applied to each specimen at a speed of 5 mm/min, and the force–displacement curve was recorded with a data acquisition rate of 10 Hz, from which the ultimate strength and stiffness in both groups were measured and compared.

2.6. Statistical Analysis

Means and standard deviations were calculated for descriptive purposes. Multiple comparisons between the two different device designs were performed using a one-way ANOVA test, with the significance level set at $p < 0.05$.

3. Results

The average BMD of the vertebral bodies was 0.63 ± 0.04 in the EVA® groups and 0.61 ± 0.03 in the OsseoFix® groups. No statistically significant difference in mean BMD was found between any of the preaugmentation groups.

Before implantation, anterior wedge fractures were created without posterior wall destruction (Figure 4). The VBH was restored in both groups, and injected cement surrounding the implants (Figure 5). It was observed that there was no cement leakage out of the vertebral bodies, which might have interfered with the biomechanical value results.

Anterior wedge compression fractures were established in all specimens. The average force needed to create the fracture was 4589.9 N (range, 3834.1–5092.2 N). The mean anterior VBH ratio was 86.05 ± 3.24% before augmentation and 94.59 ± 1.67% after augmentation in the EVA® groups and 86.37 ± 4.66% before augmentation and 94.63 ± 5.81% after augmentation in the OsseoFix® groups. No statistically significant difference in the anterior VBH ratio was found between any of the preaugmentation groups. A significant difference from augmentation was measured in both groups ($p < 0.05$), but there was no significant difference in the VBH ratio restoration between the EVA and OsseoFix® groups (8.54% compared to 8.26%) (Figure 6). The ultimate strength of the vertebral body of the EVA® and OsseoFix® groups were 6071.4 ± 352.6 N and 6262.9 ± 529.2 N, respectively, both of which were statistically significantly higher than that of the intact group (4589.9 ± 474.6 N) ($p < 0.05$) (Figure 7). The stiffnesses of the EVA®, OsseoFix®, and intact groups were 1087.2 ± 176.9, 1154.9 ± 168.9, and 1637.3 ± 340.8 N/mm, respectively. Stiffness was significantly higher in the intact group than in both the EVA® and OsseoFix® groups. There were no significant differences in stiffness between the EVA® and OsseoFix® groups ($p > 0.05$) (Figure 8).

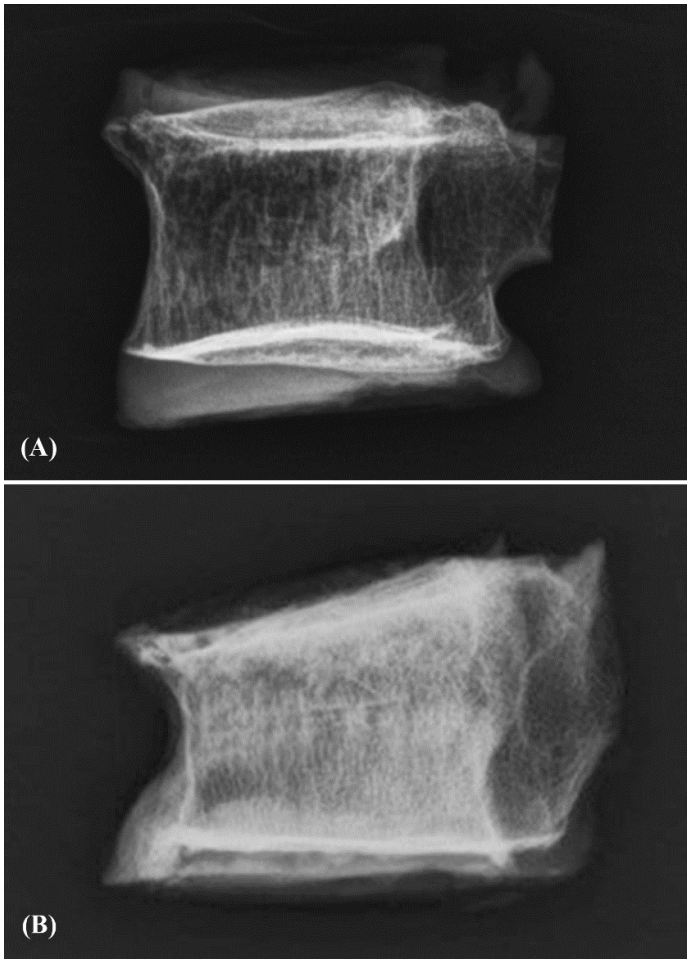

Figure 4. Photograph showing the vertebra (**A**) before and (**B**) after the creation of anterior wedge compression fracture. Anterior wedge fractures were created without posterior wall destruction.

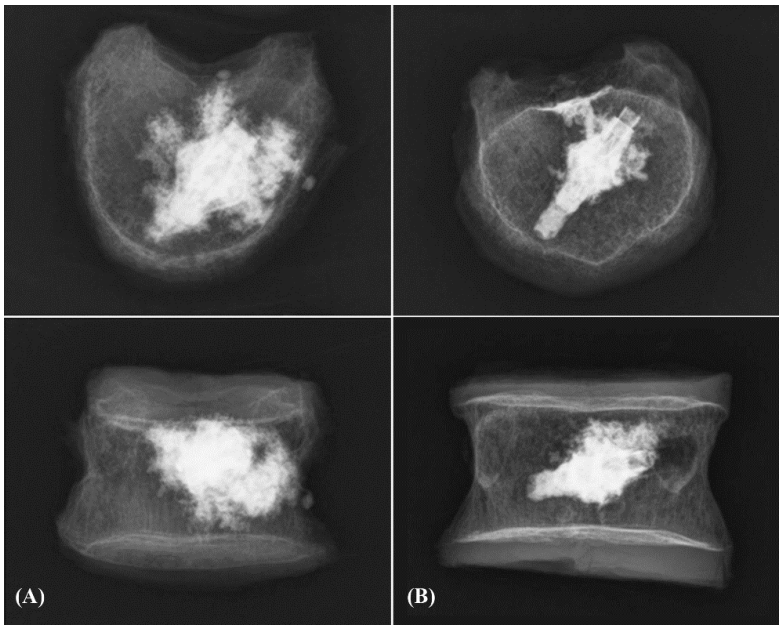

Figure 5. X-ray images showing vertebrae implanted with (**A**) EVA® and (**B**) OsseoFix® following bone cement injection. Top view (**upper**) and frontal view (**lower**).

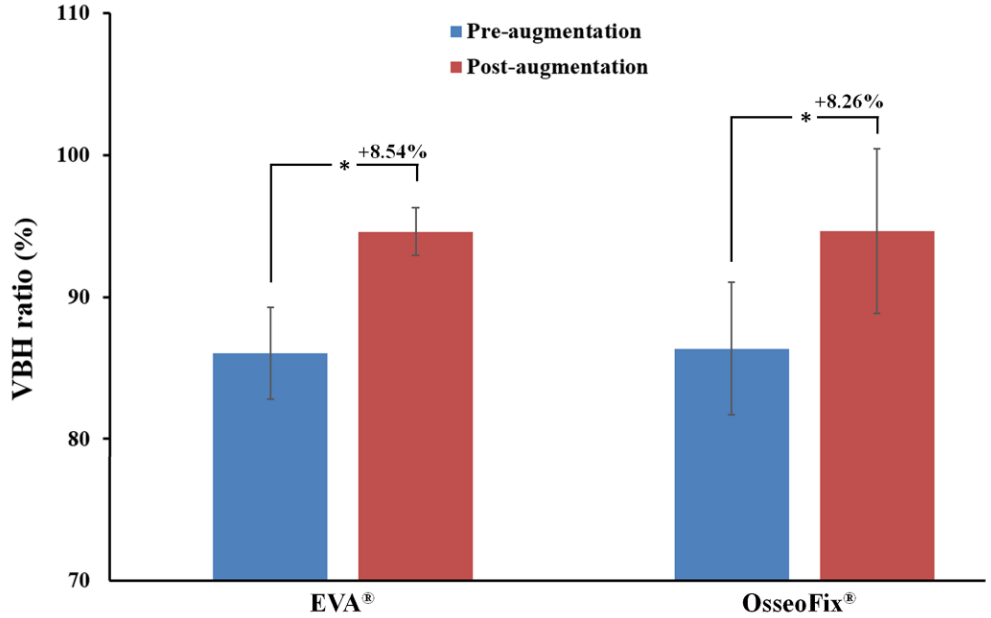

Figure 6. Mean anterior VBH ratio of preaugmentation and postaugmentation in the EVA®and OsseoFix®groups. Groups with significant differences ($p < 0.05$) are indicated with the "*" symbol.

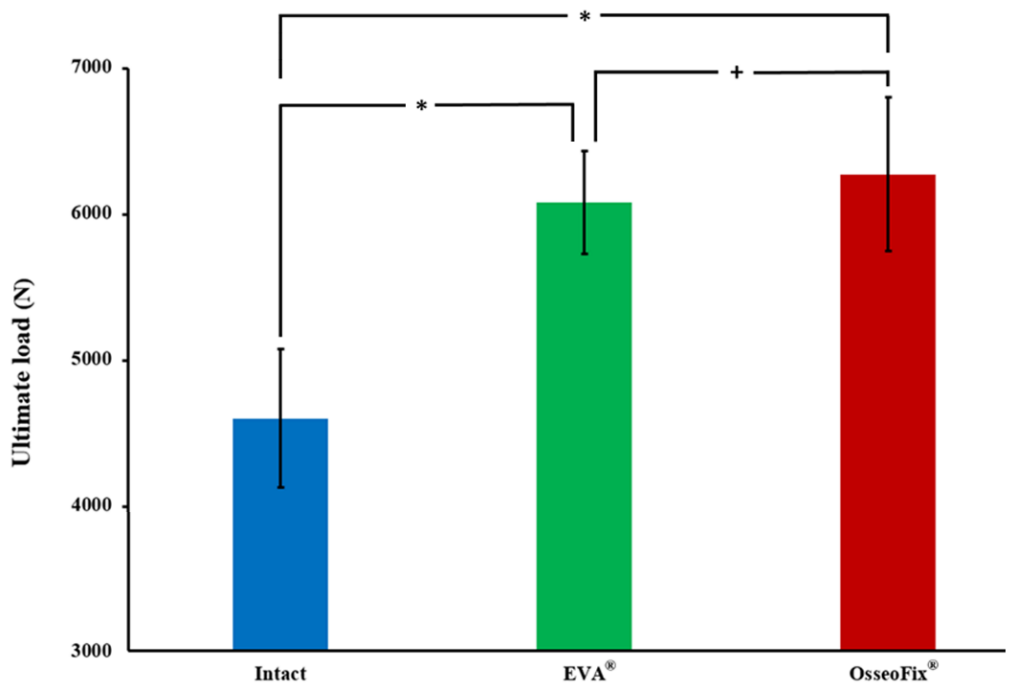

Figure 7. Mean ultimate strength in the intact, EVA®and OsseoFix®groups. Groups with significant differences ($p < 0.05$) are indicated with the "*" symbol.

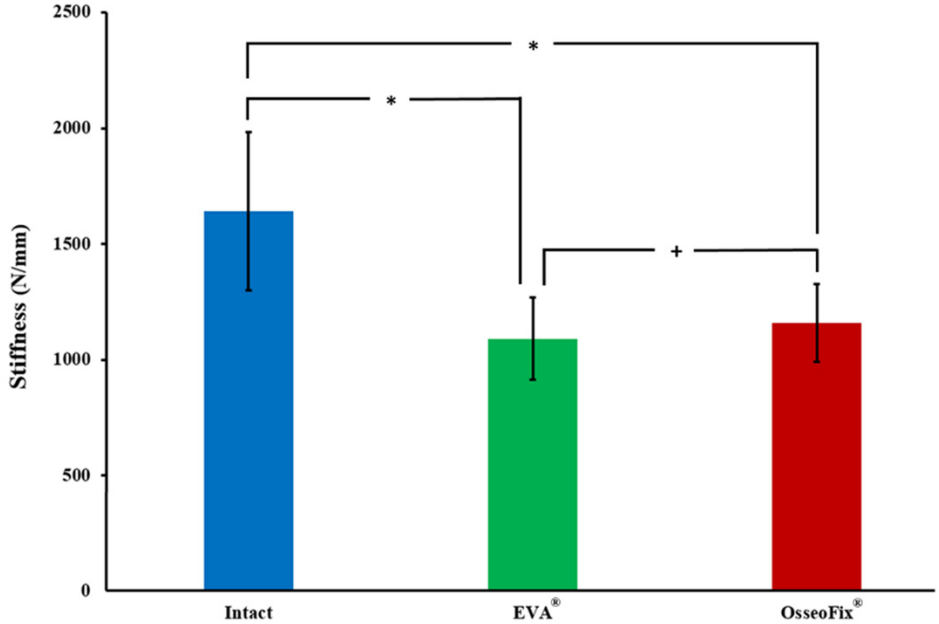

Figure 8. Mean stiffness in the intact, EVA®and OsseoFix®groups. Groups with significant differences ($p < 0.05$) are indicated with the "*" symbol.

Figure 9 shows representative force vs. displacement curves for the EVA®, OsseoFix®, and intact groups for the compression test. For all three group, a lower increasing rate of force was found at the initial phase. This might be attributed to the presence of cancellous bone between bone cement and end plate within vertebra. Following the destruction of cancellous bone, the vertebra became more compact, leading to a higher increase rate of force. In order to exclude such uncertain factors, compression stiffness was arbitrarily defined, for each specimen, as the slope of the straight line connecting the two force values of 500 N and 1500 N.

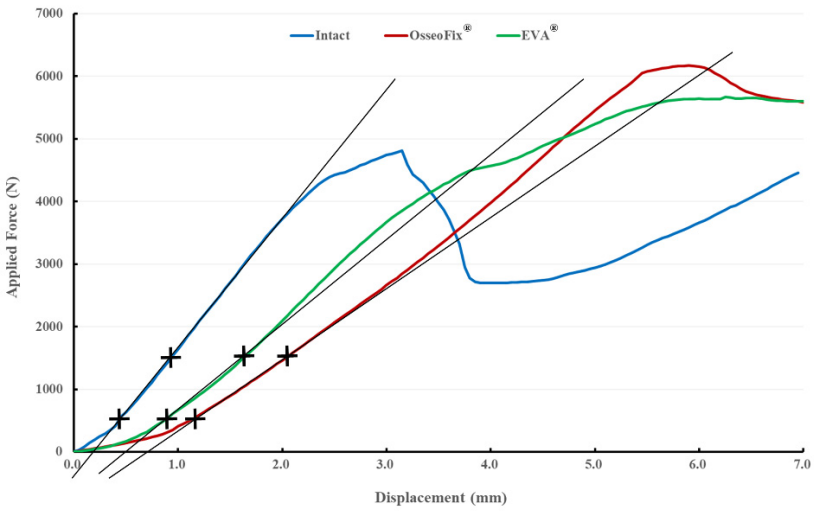

Figure 9. A typical force versus displacement curve for calculation of compression stiffness in the compression test. Compression stiffness was arbitrarily defined as the slope of the force-displacement curve between 500 N and 1500 N. Forces at 500 N and 1500 N are indicated with the "+" symbol.

4. Discussion

Vertebroplasty and kyphoplasty have been established in recent decades as minimally invasive techniques for stabilizing osteoporotic vertebral compression fractures [1,5,29]. Studies showed that better sagittal profiles were restored with kyphoplasty than with

vertebroplasty [7,29]. However, VBH recovery was often lost after the balloon was deflated and withdrawn from the catheter [27,28]. Several intravertebral augmentation systems aimed at the permanent reduction in the fractured vertebral body have been widely used in recent years [21,30]. Among these vertebral augmentation devices, the Vertebral Body Stenting® (VBS) device (Synthes, Soletta, Switzerland) consists of an expandable stent delivered into the vertebral body before bone cement injection. Rotter R. et al. [31] compared VBS device and kyphoplasty treatments of 24 fresh-frozen human cadaveric spines and found significant VBH restoration in the VBS group and no significance in stiffness or ultimate strength between systems. The SpineJack® device (Vexim, SA, Balma, France) consists of two parallel titanium plates, which can be used to elevate the fracture end plates craniocaudally and restore the collapsed vertebrae. It was reported that this device was superior to kyphoplasty in restoring vertebral heights and in decreasing cement leakage [32–34]. Intravertebral augmentation with polymer and memory alloys has also been widely used in recent years [22,35–37]. The KIVA® (Benvenue Medical Inc., Santa Clara, CA, USA) system [22] uses a flexible polyetheretherketone (PEEK) to restore the VBH and hold the cement; the Tektona® system consists of a flexible lamella nickel–titanium alloy that can be shaped by a vertebral fragment reduction instrument and allows for cement augmentation [35,37]. Intravertebral augmentation devices have been proven to have a better vertebral height restoration and a comparable biomechanical performance to balloon kyphoplasty in studies [20–22,32–38]; therefore, considering the similar expansion mechanism and material properties, OsseoFix® was chosen for comparison with our design [20,21,38]. Randomized specimens, controlled implant size, and the same cement volume allowed our biomechanical data to be reliable.

Osteoporotic human fresh-frozen vertebrae are the ideal model for vertebral augmentation biomechanical studies. In our study, a BMD of less than 0.7 g/cm^2 of each specimen was observed by DXA measurements [22]. Most of the vertebral compression fractures caused by osteoporosis clinically have an anterior wedge shape of varying degrees [3,5,6]. The contact point of axial force was determined for each specimen in the anterior half of the superior end plate to create an anterior 25% compression fracture unit that could present the clinical condition [22,25,35].

The mean VBH ratio were efficiently restored to above 94% postoperatively in both groups, which is in agreement with results of other studies using a 25% anterior wedge fractured vertebral model [24,27,28]. Vertebral height restoration-induced correction of local kyphosis was believed to be positively correlated with the sagittal vertical axis and improved spinopelvic parameters; thus, long-term satisfactory clinical outcomes were achieved [39–41]. Controversies exist about the adjacent vertebral fracture resulting from altered biomechanics in the augmented vertebra due to resistant kyphosis [42,43]. Clinical consensus suggests that the adjacent fracture rate did not increase with the augmentation procedure or the vertebral height reduction in treated vertebrae but did increase with the degree of osteoporosis [44].

Comparable strength and stiffness were also measured in both groups. It has been estimated that ultimate strength restoration compared with the intact group was 132.3% in the EVA® group and 136.5% in the OsseoFix® group. The results demonstrate that the EVA® vertebral body reduction implants are able to achieve effective endplate reduction and provide similar biomechanical stability to that of the OsseoFix® implant. Another issue of concern in vertebroplasty is the refracture of cemented vertebrae, which occurs in up to 30% of osteoporotic patients [45,46]; associated risk factors include intraosseous vacuum cleft, overcorrection of the anterior VBH, low BMD, and mostly inadequate cement filling pattern [45,46]. The advantage of the EVA® device is not only the increased strength compared with the intact groups but also the enhanced symmetric distribution of cement into the surrounding trabeculae by the expanded blades. Thus, more interdigitated cement distribution resulting in less recollapse incidence could be expected [45,46].

There was no significant difference in stiffness between the two augmentation groups; interestingly, the values in both groups were significantly lower than those in the intact

group. Similar results were also observed for kyphoplasty and vertebroplasty in cadaveric biomechanical studies [47,48]. The inversely proportional ultimate strength results indicate that vertebral body stiffness is not solely dependent on the mechanical properties of cement or implant. The cement filling volume percentage, cement distribution, heterogeneous osteoporotic region, and degree of decreased bone mineral density all contributed to the final stiffness of the augmented vertebral body. Because of the lower compression stiffness for vertebral augmentation with EVA® and OsseoFix®, fewer adjacent vertebral fractures can be expected in our future study.

The goal of this study was to determine whether the EVA® system is as effective as the OsseoFix® reduction system, which has been proven effective and safe in vertebral augmentation since 2009 in the U.S. and Europe [20,27,38]. No significant differences were seen between the two procedures for VBH restoration, ultimate strength, and stiffness. Nonetheless, the advantages in the novel design of EVA® are as follows: (1) Expanding mechanism: eight blades were gradually expanded following the forward advancing of the barrel relative to the central tube by the clockwise rotation of the expander handle. In contrast, a retrograde expansion of mesh is incorporated in the OsseoFix® design, which might cause fractured bony fragment shift posteriorly and create larger posterior defect, which could induce devastating posterior cement leakage. (2) The central tube design of the EVA® system provides higher strength than the hollow mesh in OsseoFix®, but there is no significant difference in ultimate strength and stiffness in both the EVA® and OsseoFix® groups. Studies 23,25 showed that ultimate strength reached 120–127% of the intact level with only PMMA cement augmentation. In our study, the biomechanical performance (132.3% in the EVA® group and 136.5% in the OsseoFix® group) would mostly be affected by cement instead of implant, and we believe that the difference would appear if only comparing the implant; however, the comparison is non-practical clinically. Two shield designs (blades and central tube) preventing low-viscosity cement from leakage are rationally more effective than the mesh-only designs in OsseoFix® [49,50].

There are some limitations in the current study. First, an axial compressive loading was used to create the fracture model in the current study, whereas the native trauma mechanism is much more complex. Second, a single cadaveric vertebra without the attachment of discs, ligaments, facet joints, and muscles cannot clinically represent the complicated biomechanical performance of a fractured spine. Third, ultimate strength and stiffness cannot completely characterize daily activities, and different directional and cyclic loadings should be examined to expand the clinical application range. Fourth, only one implant size and one uncontrolled injected cement volume were examined, more varieties should be compared to obtain consistent results. Finally, the studied implant showed comparable height restoration and biomechanical performance to that of existing augmentation implants, but the native obstacles such as non-biological property or cement leakage of PMMA still cannot be totally overcome.

5. Conclusions

This novel EVA® system showed comparable height restoration and biomechanical performance to that of existing augmentation implants in human cadaveric osteoporotic compression fractures. Potential advantages of preventing cement posterior leakage and promoting cement interdigitation are expected from this novel design. Additional studies with more complicated fracture models and cement filling volumes will help us better clarify this issue.

Author Contributions: Conceptualization, M.-K.H., M.S.L. and C.-L.T.; methodology, S.-Y.L. and M.-Y.L.; software, D.-M.L., M.-Y.L. and S.-Y.L.; validation, W.-J.C. and M.S.L.; formal analysis, M.-K.H., D.-M.L. and C.-L.T.; investigation, M.-K.H., W.-J.C., D.-M.L. and C.-L.T.; data curation: W.-J.C. and M.S.L.; supervision: W.-J.C.; writing—original draft preparation, M.-K.H.; writing—review and editing, D.-M.L. and C.-L.T.; funding acquisition, M.S.L. All authors have read and agreed to the published version of the manuscript.

Funding: This work was supported by the Ministry of Science and Technology in Taiwan (Grant No. NSC100-2321-B-182-011). The funders had no role in study design, data collection and analysis, decision to publish, or preparation of the manuscript.

Institutional Review Board Statement: This study was conducted in accordance with the Declaration of Helsinki and approved by the Ministry of Science and Technology in Taiwan (Grant No. NSC100-2321-B-182-011).

Informed Consent Statement: Not applicable.

Data Availability Statement: The data used to support the finding of this study are available from the corresponding author upon request.

Conflicts of Interest: The authors declare no conflict of interest.

References

1. Long, Y.; Yi, W.; Yang, D. Advances in Vertebral Augmentation Systems for Osteoporotic Vertebral Compression Fractures. *Pain Res. Manag.* **2020**, *2020*, 3947368. [CrossRef]
2. Semaan, H.; Obri, T.; Bazerbashi, M.; Paull, D.; Liu, X.; Sarrouj, M.; Elgafy, H. Clinical outcome and subsequent sequelae of cement extravasation after percutaneous kyphoplasty and vertebroplasty: A comparative review. *Acta Radiol.* **2018**, *59*, 861–868. [CrossRef] [PubMed]
3. Goldstein, C.L.; Chutkan, N.B.; Choma, T.J.; Orr, R.D. Management of the Elderly With Vertebral Compression Fractures. *Neurosurgery* **2015**, *77*, S33–S45. [CrossRef] [PubMed]
4. Hoyt, D.; Urits, I.; Orhurhu, V.; Orhurhu, M.S.; Callan, J.; Powell, J.; Manchikanti, L.; Kaye, A.D.; Kaye, R.J.; Viswanath, O. Current Concepts in the Management of Vertebral Compression Fractures. *Curr. Pain Headache Rep.* **2020**, *24*, 16. [CrossRef] [PubMed]
5. Prost, S.; Pesenti, S.; Fuentes, S.; Tropiano, P.; Blondel, B. Treatment of osteoporotic vertebral fractures. *Orthop. Traumatol. Surg. Res.* **2020**, *107*, 102779. [CrossRef]
6. Chandra, R.; Maingard, J.; Asadi, H.; Slater, L.-A.; Mazwi, T.-L.; Marcia, S.; Barr, J.; Hirsch, J. Vertebroplasty and Kyphoplasty for Osteoporotic Vertebral Fractures: What Are the Latest Data? *Am. J. Neuroradiol.* **2018**, *39*, 798–806. [CrossRef] [PubMed]
7. Langner, S.; Henker, C. Vertebroplastie und Kyphoplastie. *Der Radiol.* **2020**, *60*, 138–143. [CrossRef] [PubMed]
8. Boss, S.; Srivastava, V.; Anitescu, M. Vertebroplasty and Kyphoplasty. *Phys. Med. Rehabilitation Clin. North Am.* **2022**, *33*, 425–453. [CrossRef]
9. Hsieh, M.-K.; Kao, F.-C.; Chiu, P.-Y.; Chen, L.-H.; Yu, C.-W.; Niu, C.-C.; Lai, P.-L.; Tsai, T.-T. Risk factors of neurological deficit and pulmonary cement embolism after percutaneous vertebroplasty. *J. Orthop. Surg. Res.* **2019**, *14*, 406. [CrossRef]
10. Zhan, Y.; Jiang, J.; Liao, H.; Tan, H.; Yang, K. Risk Factors for Cement Leakage After Vertebroplasty or Kyphoplasty: A Meta-Analysis of Published Evidence. *World Neurosurg.* **2017**, *101*, 633–642. [CrossRef]
11. Baek, I.-H.; Park, H.-Y.; Kim, K.-W.; Jang, T.-Y.; Lee, J.-S. Paraplegia due to intradural cement leakage after vertebroplasty: A case report and literature review. *BMC Musculoskelet. Disord.* **2021**, *22*, 741. [CrossRef] [PubMed]
12. Chen, W.C.; Tsai, S.H.L.; Goyal, A.; Fu, T.-S.; Lin, T.-Y.; Bydon, M. Comparison between vertebroplasty with high or low viscosity cement augmentation or kyphoplasty in cement leakage rate for patients with vertebral compression fracture: A systematic review and network meta-analysis. *Eur. Spine J.* **2021**, *30*, 2680–2690. [CrossRef] [PubMed]
13. Arana-Guajardo, A.C.; Cavazos-Aranda, A.L. Embolismo pulmonar asintomático secundario a fuga de cemento tras vertebroplastia. *Reumatol. Clínica* **2021**, *17*, 302–303. [CrossRef]
14. Chen, L.-H.; Hsieh, M.-K.; Chen, W.-J.; Mk, H.; Lh, C.; Wj, C. Current concepts of percutaneous balloon kyphoplasty for the treatment of osteoporotic vertebral compression fractures: Evidence-based review. *Biomed. J.* **2013**, *36*, 154–161. [CrossRef]
15. Filippiadis, D.; Tutton, S.; Kelekis, A. Pain management: The rising role of interventional oncology. *Diagn. Interv. Imaging* **2017**, *98*, 627–634. [CrossRef] [PubMed]
16. Tomas, C.; Jensen, A.; Ahmed, F.; Ho, C.K.; Jesse, M.K. Minding the Gap in Vertebroplasty: Vertebral Body Fracture Clefts and Cement Nonunion. *Pain Physician* **2021**, *24*, E221–E230. [PubMed]
17. Kuo, Y.-R.; Cheng, T.-A.; Chou, P.-H.; Liu, Y.-F.; Chang, C.-J.; Chuang, C.-F.; Su, P.-F.; Lin, R.-M.; Lin, C.-L. Healing of Vertebral Compression Fractures in the Elderly after Percutaneous Vertebroplasty—An Analysis of New Bone Formation and Sagittal Alignment in a 3-Year Follow-Up. *J. Clin. Med.* **2022**, *11*, 708. [CrossRef]
18. Turner, T.M.; Urban, R.M.; Singh, K.; Hall, D.J.; Renner, S.M.; Lim, T.-H.; Tomlinson, M.J.; An, H.S. Vertebroplasty comparing injectable calcium phosphate cement compared with polymethylmethacrylate in a unique canine vertebral body large defect model. *Spine J.* **2008**, *8*, 482–487. [CrossRef]
19. Wichlas, F.; Trzenschik, H.; Tsitsilonis, S.; Rohlmann, A.; Bail, H.-J. Biomechanical behavior of MRI-signal-inducing bone cements after vertebroplasty in osteoporotic vertebral bodies: An experimental cadaver study. *Clin. Biomech.* **2014**, *29*, 571–576. [CrossRef] [PubMed]

20. Ender, S.A.; Gradl, G.; Ender, M.; Langner, S.; Merk, H.R.; Kayser, R. Osseofix®System for Percutaneous Stabilization of Osteoporotic and Tumorous Vertebral Compression Fractures—Clinical and Radiological Results After 12 Months. In *RöFo-Fortschritte auf dem Gebiet der Röntgenstrahlen und der bildgebenden Verfahren*; © Georg Thieme Verlag KG: New York, NY, USA, 2013; Volume 186, pp. 380–387. [CrossRef]
21. Vanni, D.; Galzio, R.; Kazakova, A.; Pantalone, A.; Grillea, G.; Bartolo, M.; Salini, V.; Magliani, V. Third-generation percutaneous vertebral augmentation systems. *J. Spine Surg.* **2016**, *2*, 13–20. [CrossRef] [PubMed]
22. Wilson, D.C.; Connolly, R.J.; Zhu, Q.; Emery, J.L.; Kingwell, S.P.; Kitchel, S.; Cripton, P.A.; Wilson, D.R. An ex vivo biomechanical comparison of a novel vertebral compression fracture treatment system to kyphoplasty. *Clin. Biomech.* **2012**, *27*, 346–353. [CrossRef] [PubMed]
23. Haddad, R.; Peltz, T.; Bertollo, N.; Walsh, W.R.; Nicklin, S. Looped suture properties: Implications for multistranded flexor tendon repair. *J. Hand Surg. (Eur. Vol.)* **2015**, *40*, 234–238. [CrossRef]
24. Krüger, A.; Oberkircher, L.; Figiel, J.; Floßdorf, F.; Bolzinger, F.; Noriega, D.C.; Ruchholtz, S. Height restoration of osteoporotic vertebral compression fractures using different intravertebral reduction devices: A cadaveric study. *Spine J.* **2015**, *15*, 1092–1098. [CrossRef]
25. Kim, C.; Mahar, A.; Perry, A.; Massie, J.; Lu, L.; Currier, B.; Yaszemski, M.J. Biomechanical Evaluation of an Injectable Radiopaque Polypropylene Fumarate Cement for Kyphoplasty in a Cadaveric Osteoporotic Vertebral Compression Fracture Model. *J. Spinal Disord. Tech.* **2007**, *20*, 604–609. [CrossRef]
26. Trost, M.; Schmoelz, W.; Wimmer, D.; Hörmann, R.; Frey, S.; Schulte, T.L. Local osteo-enhancement of osteoporotic vertebra with a triphasic bone implant material increases strength—A biomechanical study. *Arch. Orthop. Trauma. Surg.* **2020**, *140*, 1395–1401. [CrossRef]
27. Ender, S.A.; Eschler, A.; Ender, M.; Merk, H.R.; Kayser, R. Fracture care using percutaneously applied titanium mesh cages (OsseoFix®) for unstable osteoporotic thoracolumbar burst fractures is able to reduce cement-associated complications—Results after 12 months. *J. Orthop. Surg. Res.* **2015**, *10*, 175. [CrossRef]
28. Eschler, A.; Ender, S.A.; Ulmar, B.; Herlyn, P.; Mittlmeier, T.; Gradl, G. Cementless Fixation of Osteoporotic VCFs Using Titanium Mesh Implants (OsseoFix): Preliminary Results. *BioMed Res. Int.* **2014**, *2014*, 853897. [CrossRef] [PubMed]
29. Filippiadis, D.K.; Marcia, S.; Masala, S.; Deschamps, F.; Kelekis, A. Percutaneous Vertebroplasty and Kyphoplasty: Current Status, New Developments and Old Controversies. *Cardiovasc. Interv. Radiol.* **2017**, *40*, 1815–1823. [CrossRef] [PubMed]
30. Moura, D.L.; Gabriel, J.P. Expandable Intravertebral Implants: A Narrative Review on the Concept, Biomechanics, and Outcomes in Traumatology. *Cureus* **2021**, *13*, e17795. [CrossRef] [PubMed]
31. Rotter, R.; Martin, H.; Fuerderer, S.; Gabl, M.; Roeder, C.; Heini, P.; Mittlmeier, T. Vertebral body stenting: A new method for vertebral augmentation versus kyphoplasty. *Eur. Spine J.* **2010**, *19*, 916–923. [CrossRef]
32. Premat, K.; Perre, S.V.; Cormier, É.; Shotar, E.; Degos, V.; Morardet, L.; Fargeot, C.; Clarençon, F.; Chiras, J. Vertebral augmentation with the SpineJack®in chronic vertebral compression fractures with major kyphosis. *Eur. Radiol.* **2018**, *28*, 4985–4991. [CrossRef] [PubMed]
33. Kerschbaumer, G.; Gaulin, B.; Ruatti, S.; Tonetti, J.; Boudissa, M. Clinical and radiological outcomes in thoracolumbar fractures using the SpineJack device. A prospective study of seventy-four patients with a two point three year mean of follow-up. *Int. Orthop.* **2019**, *43*, 2773–2779. [CrossRef] [PubMed]
34. Lofrese, G.; Ricciardi, L.; De Bonis, P.; Cultrera, F.; Cappuccio, M.; Scerrati, A.; Martucci, A.; Musio, A.; Tosatto, L.; De Iure, F. Use of the SpineJack direct reduction for treating type A2, A3 and A4 fractures of the thoracolumbar spine: A retrospective case series. *J. NeuroInterventional Surg.* **2022**, *14*, 931–937. [CrossRef]
35. Chen, B.; Zheng, Y.-H.; Zheng, T.; Sun, C.-H.; Lu, J.; Cao, P.; Zhou, J.-H. The implantation of a Nickel-Titanium shape memory alloy ameliorates vertebral body compression fractures: A cadaveric study. *Int. J. Clin. Exp. Med.* **2015**, *8*, 16899–16906. [PubMed]
36. Seel, E.H.; Davies, E.M. A biomechanical comparison of kyphoplasty using a balloon bone tamp *versus* an expandable polymer bone tamp in a deer spine model. *J. Bone Jt. Surgery. Br. Vol.* **2007**, *89*, 253–257. [CrossRef] [PubMed]
37. Marcia, S.; Piras, E.; Hirsch, J.A.; Mereu, A.; Marras, M.; Spinelli, A.; Saba, L. Efficacy of a Novel Vertebral Body Augmentation System in the Treatment of Patients with Symptomatic Vertebral Body Fractures. *Cardiovasc. Interv. Radiol.* **2021**, *44*, 289–299. [CrossRef]
38. Ender, S.A.; Wetterau, E.; Ender, M.; Kühn, J.-P.; Merk, H.R.; Kayser, R. Percutaneous Stabilization System Osseofix®for Treatment of Osteoporotic Vertebral Compression Fractures—Clinical and Radiological Results after 12 Months. *PLoS ONE* **2013**, *8*, e65119. [CrossRef]
39. Kim, K.-H.; Kuh, S.; Chin, D.K.; Jin, B.-H.; Kim, K.S.; Yoon, Y.-S.; Cho, Y.-E. Kyphoplasty Versus Vertebroplasty: Restoration of vertebral body height and correction of kyphotic deformity with special attention to the shape of the fractured vertebrae. *J. Spinal Disord. Tech.* **2012**, *25*, 338–344. [CrossRef]
40. Pumberger, M.; Schitz, F.; Bürger, J.; Schömig, F.; Putzier, M.; Palmowski, Y. Kyphoplasty Restores the Global Sagittal Balance of the Spine Independently from Pain Reduction. *Sci. Rep.* **2020**, *10*, 8894. [CrossRef]
41. Rodriguez, A.J.; Fink, H.A.; Mirigian, L.; Guañabens, N.; Eastell, R.; Akesson, K.; Bauer, U.C.; Ebeling, P.R. Pain, Quality of Life, and Safety Outcomes of Kyphoplasty for Vertebral Compression Fractures: Report of a Task Force of the American Society for Bone and Mineral Research. *J. Bone Miner. Res.* **2017**, *32*, 1935–1944. [CrossRef]

42. Zhang, T. Does Percutaneous Vertebroplasty or Balloon Kyphoplasty for Osteoporotic Vertebral Compression Fractures Increase the Incidence of New Vertebral Fractures? A Meta-Analysis. *Pain Physician* **2017**, *20*, E13–E28. [CrossRef] [PubMed]
43. Zhai, G.; Li, A.; Liu, B.; Lv, D.; Zhang, J.; Sheng, W.; Yang, G.; Gao, Y. A meta-analysis of the secondary fractures for osteoporotic vertebral compression fractures after percutaneous vertebroplasty. *Medicine* **2021**, *100*, e25396. [CrossRef] [PubMed]
44. Movrin, I.; Vengust, R.; Komadina, R. Adjacent vertebral fractures after percutaneous vertebral augmentation of osteoporotic vertebral compression fracture: A comparison of balloon kyphoplasty and vertebroplasty. *Arch. Orthop. Trauma. Surg.* **2010**, *130*, 1157–1166. [CrossRef] [PubMed]
45. Hu, L.; Sun, H.; Wang, H.; Cai, J.; Tao, Y.; Feng, X.; Wang, Y. Cement injection and postoperative vertebral fractures during vertebroplasty. *J. Orthop. Surg. Res.* **2019**, *14*, 228. [CrossRef] [PubMed]
46. Xiong, Y.-C.; Guo, W.; Xu, F.; Zhang, C.-C.; Liang, Z.-P.; Wu, L.; Chen, S.; Zeng, X.-W. Refracture of the cemented vertebrae after percutaneous vertebroplasty: Risk factors and imaging findings. *BMC Musculoskelet. Disord.* **2021**, *22*, 459. [CrossRef]
47. Kim, M.J.; Lindsey, D.P.; Hannibal, M.; Alamin, T.F. Vertebroplasty Versus Kyphoplasty: Biomechanical Behavior Under Repetitive Loading Conditions. *Spine* **2006**, *31*, 2079–2084. [CrossRef]
48. McCann, H.; Lepine, M.; Glaser, J. Biomechanical Comparison of Augmentation Techniques for Insufficiency Fractures. *Spine* **2006**, *31*, E499–E502. [CrossRef]
49. Cianfoni, A.; Distefano, D.; Pravatà, E.; Espeli, V.; Pesce, G.; Mordasini, P.; La Barbera, L.; Scarone, P.; Bonaldi, G. Vertebral body stent augmentation to reconstruct the anterior column in neoplastic extreme osteolysis. *J. NeuroInterventional Surg.* **2019**, *11*, 313–318. [CrossRef]
50. Noriega, D.C.; Ramajo, R.H.; Lite, I.S.; Toribio, B.; Corredera, R.; Ardura, F.; Krüger, A. Safety and clinical performance of kyphoplasty and SpineJack®procedures in the treatment of osteoporotic vertebral compression fractures: A pilot, monocentric, investigator-initiated study. *Osteoporos. Int.* **2016**, *276*, 2047–2055. [CrossRef]