


# Incidence of Chronic Pain following Oral Soft Tissue Biopsies: A Retrospective Study

Adir Cohen <sup>1</sup>, Rame Daod <sup>2</sup>, Rakefet Czerninski <sup>3</sup>, Naama Keshet <sup>3</sup>, Robert Yanko <sup>3</sup>, Andra Rettman <sup>3</sup>, Yair Sharav <sup>3</sup>, Doron J. Aframian <sup>3</sup> and Yaron Haviv <sup>3,\*</sup>

<sup>1</sup> Department of Maxillofacial Surgery, Hebrew University-Hadassah School of Dental Medicine, Jerusalem 91120, Israel; dr.adir.cohen@gmail.com

<sup>2</sup> In Partial Fulfillment of DMD Requirements, Hebrew University-Hadassah School of Dental Medicine, Jerusalem 91120, Israel; rame.daod@mail.huji.ac.il

<sup>3</sup> Faculty of Dental Medicine, Department of Oral Medicine, Sedation and Imaging, Hadassah Medical Center, Hebrew University of Jerusalem, Jerusalem 91120, Israel; rakefetc@hadassah.org.il (R.C.); naamak@hadassah.org.il (N.K.); roberty@hadassah.org.il (R.Y.); andrar@hadassah.org.il (A.R.); sharavy@mail.huji.ac.il (Y.S.); dorona@hadassah.org.il (D.J.A.)

\* Correspondence: yaronha@hadassah.org.il; Tel.: +972-2-677-6140; Fax: +972-2-644-7919

**Abstract:** Soft tissue oral biopsies (STOB) are commonly performed in the medical field to obtain tissue samples for diagnostic purposes. However, like all invasive procedures, these biopsies may carry risks, such as the development of chronic long-lasting neuropathic pain. This study aims to examine the occurrence of chronic pain following STOBs. A retrospective study was conducted on the medical records of 695 patients who underwent STOBs at the Maxillofacial Surgery Department of Hadassah Medical Center between the years 2013 and 2022. Demographic information, details of the procedure, histopathological diagnosis, and data related to post-procedure pain in the biopsy area were collected and analyzed. Out of the 695 patients, only 4 reports of chronic pain with mild intensity lasting more than three months following oral biopsy were documented, with incidence rate of 0.57%; all were females with a median age of  $59 \pm 2.0$  years. The biopsies were taken from various sites and the common diagnoses were lichen planus, venous malformation, and fibromas. In conclusion, chronic pain after oral soft-tissue biopsies is rare, generally mild, and typically does not require extra therapy. These insights can aid clinicians and patients in making informed decisions about these procedures.

**Keywords:** post-traumatic neuropathy; neuropathic pain; biopsy; soft-tissue biopsy; orofacial pain



**Citation:** Cohen, A.; Daod, R.; Czerninski, R.; Keshet, N.; Yanko, R.; Rettman, A.; Sharav, Y.; Aframian, D.J.; Haviv, Y. Incidence of Chronic Pain following Oral Soft Tissue Biopsies: A Retrospective Study. *Appl. Sci.* **2023**, *13*, 6719. <https://doi.org/10.3390/app13116719>

Academic Editor: Bruno Chrcanovic

Received: 27 April 2023

Revised: 29 May 2023

Accepted: 30 May 2023

Published: 31 May 2023



**Copyright:** © 2023 by the authors. Licensee MDPI, Basel, Switzerland. This article is an open access article distributed under the terms and conditions of the Creative Commons Attribution (CC BY) license (<https://creativecommons.org/licenses/by/4.0/>).

## 1. Introduction

Biopsies of the mucosal tissues of the oral cavity are often used for histopathological evaluation and the diagnosis of abnormalities such as persistent non-healing lesions; suspected malignant lesions; rapidly expanding lesions; mucosal color changes; and the evaluation of systemic conditions with oral manifestations such as vesiculobullous diseases [1]. Incisional and excisional biopsies are the most prevalent procedures in the mouth, whereas fine-needle biopsy, core needle biopsy and punch biopsies [2] are used less often.

Orofacial pain following injury has been divided into acute and chronic pain by the International Classification of Orofacial Pain (ICOP) [3]. Chronic pain lasts more than 3 months and occurs on at least 15 days per month. The International Classification of Headache Disorders (ICHD) [4] states that chronic pain due to traumatic injury (following trauma) occurs within 7 days of the event and persists for more than 3 months.

Chronic neuropathic pain occurs due to damage or injury to peripheral nerves and presents as dull, deep, aching pain, in conjunction with episodic sharp pain [5,6].

The term painful post-traumatic trigeminal neuropathy (PPTTN) was recently proposed by the International Headache Society [4], and ICOP [3] to reflect neuropathic pain of

traumatic origin affecting the trigeminal nerve and resulting in long-lasting pain. PPTTN, like other post-traumatic neuropathies, is very resistant to therapy, including extensive pharmacotherapeutic protocols [6].

Considerable research has evaluated the incidence of PPTTN following various minor oral procedures including root-canals, extractions or implants [7]. There is no clear evidence regarding the incidence of long-term neuropathic pain or long-term neuropathic changes such as dysesthesia following a biopsy of the oral mucosa.

The aim of our study was to investigate the incidence of chronic pain after oral soft-tissue biopsies and determine whether there is a correlation with lesion site or pathology. This study may provide insights into the potential risks associated with oral soft-tissue biopsies and aid healthcare professionals and patients in making informed decisions regarding these procedures.

## 2. Materials and Methods

A retrospective study examined all the medical records of patients undergoing soft-tissue Oral Biopsy (STOB) in the Department of Oral and Maxillofacial Surgery at Hadassah Medical center, Jerusalem Israel between the years 2003 to 2022.

The institutional review board approved the study (#0329-21-HMO).

Records of patients with a history of chronic pain at the biopsy site (before the procedure), and of individuals younger than 18 were excluded (2).

Primary and resultant data were recorded on an intake form. Demographic data included gender and age. Lesion location was recorded as buccal mucosa, gingiva, tongue, lips, hard/soft palate, floor of the mouth, retromolar pad and vestibule area (Table 1). Histopathological diagnosis was recorded and included 64 malignant and nonmalignant lesions (Supplementary Materials, Table S1); these were divided to 8 general groups (Figure 1). The patients with malignant lesions underwent extensive surgery within 3 months of the biopsy and were therefore excluded from our statistical analysis of chronic pain.

**Table 1.** The distribution of oral cavity biopsies by location.

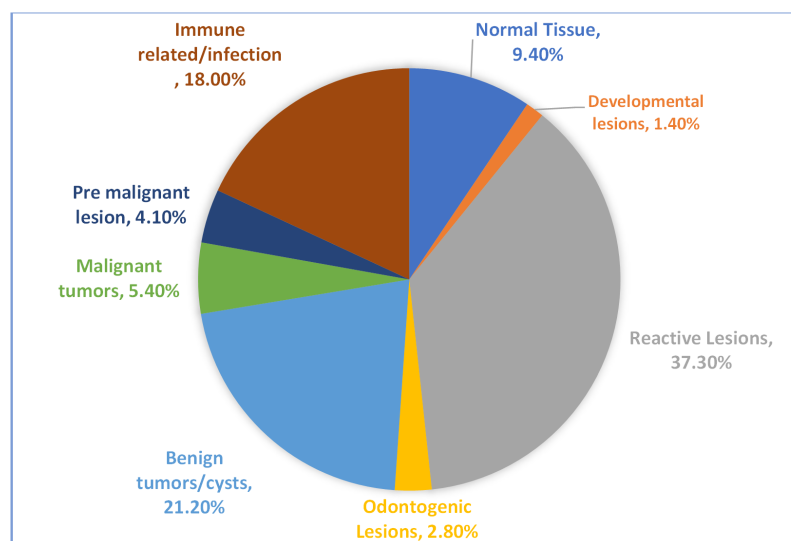
Location of the Biopsy	Percent (%)	Number (N)
Buccal mucosa	31.00%	216
Gingiva	21.20%	148
Tongue	19.60%	137
Lips	18.80%	131
Hard/soft palate	6.50%	45
Floor of the mouth	1.40%	10
Retro molar pad	0.90%	6
Vestibule of mouth	0.10%	2

Descriptive clinical pre-biopsy features included exophytic, endophytic, leukoplakia, erythroplakia, submucosal, cystic, malignant appearance and fibrotic appearance.

The routine instructions following an oral biopsy procedure include contacting the clinic regarding any questions and to return if experiencing any symptoms. All patients with at least 3 months of pain at the biopsy site were examined and details of pain characteristics were recorded. The criteria used for chronic post traumatic pain was based on ICHD-3 [4].

Exclusion criteria for chronic pain following biopsy (II): (1) Pain due to local pathology (such as: dental, masticatory muscles, TMJ, salivary glands, maxillary sinus), (2) pain that from major surgery in the same area as the biopsy, e.g., squamous cell carcinoma removal, (3) pain from the underlying pathology such as lichen planus that was not due to the biopsy itself (these patients were included in the total 695), (4) patients with other pain diagnoses such as migraine symptomatology fulfilling ICHD criteria [4], or suspected trigeminal cutonomic cephalgias (TACs) or intra cranial pathology. Additional data recorded for patients diagnosed with PPTTN after the biopsy included pain onset, pain duration, pain intensity, whether the pain is constant or intermittent or both, need for analgesics and treatment recommendations.

Descriptive analysis was used for qualitative variables and presented as absolute numbers and percentages. There was no need for comparative statistics. SPSS software version 22.0 was used.



**Figure 1.** Histological diagnosis of biopsies divided by groups.

### 3. Results

In total, 695 patient records were examined: 392 (56%) were women, and 303 (43%) were men. The median age was  $59 \pm 2.0$  years. The most common biopsy area was the buccal mucosa, the complete list of sites and frequencies can be seen in Table 1.

Histopathological analysis identified 64 lesions, both malignant and non-malignant, stratified into eight categories (Figure 1). The majority were reactive lesions (37.3%), followed by non-malignant tumors (21%), and immune-related/infectious lesions (18%).

The most common histological diagnoses were fibroma (220, 31.8%), lichen planus (88, 12%), mucocele (87, 12.5%), squamous cell carcinoma (35, 5%), pemphigus vulgaris (26, 3.7%), pyogenic granuloma (19, 2.7%), and papilloma (16, 2.6%); see Supplementary Material for the complete list (Table S1).

Four patients (out of 695) reported at least 3 months of post-biopsy pain. The pain was mainly episodic in nature, and there was no need for persistent analgesics. The histopathological diagnosis, biopsy location and other clinically relevant information are detailed in Table 2.

**Table 2.** Medical records and follow-up summary of patients with pain lasting Over 3 months.

	Patient 1	Patient 2	Patient 3	Patient 4
Age (years)	36	43	81	76
Gender	Female	Female	Female	Female
Histopathological diagnosis	Fibroma	Venous malformation	Lichen planus	Lichen planus
Location of the biopsy	Gingiva	Lower lip	Left buccal mucosa	Tongue
Timing of pain after biopsy	Immediate	Immediate	Immediate	Immediate
Constant or episodic pain	Episodic	Episodic	Episodic	Episodic
Intensity of pain	Mild	Mild	Mild	Mild
Duration of pain after biopsy	1 year	6 months	3 years	3 years
Physical examination	On the top of the papilla of tooth 42 slight hyperplasia 2–3 mm, sensitive area	Residual internal scar 3 mm, sensitive to touch	Normal	Normal
Need for analgesics	No	No	No	No
Recommendation for treatment	Maintaining oral hygiene	No intervention recommended	No intervention recommended	Maintaining oral hygiene

#### 4. Discussion

In this study, we aimed to evaluate the incidence of chronic, possibly neuropathic, pain following soft-tissue biopsies in the oral mucosa and to correlate it with the biopsy site and histopathological diagnosis. To best of our knowledge, this is the first study on the incidence of chronic pain following oral soft-tissue biopsies.

The files of 695 patients who underwent an intra-oral soft tissue biopsy were examined retrospectively. Four patients developed chronic pain at the biopsy site with no correlation to location or histopathological results (Table 2). The prevalence of PPTN development after other common procedures in the oral area has been studied extensively [8–11], including local anesthesia in mandibular injections [12]. Interestingly, the chance of developing chronic pain after oral procedures with no bone involvement is relatively high. For example, PPTN or sensory abnormalities after root canal therapy including pulp tissue removal occurs in 3–13% of cases [7,13]. A systematic review and meta-analysis estimated the frequency of all-cause persistent tooth pain after endodontic procedures to be 5.3% [14].

Biopsy for pathological investigation is a routine procedure that obviously causes tissue injury/trauma. Wound healing is the process of restoration of tissue integrity after trauma and has four major phases: hemostasis, inflammation, proliferation, and tissue remodeling [15]. This process is faster and leaves less scarring in the oral cavity than the skin due to accelerated immune response, and higher extracellular matrix remodeling rate [15]. Previous studies evaluated acute pain during tissue healing following oral biopsy. Kearns et al., assessed immediate pain up to 7 days after biopsy and noted that only 0.03% of patients had pain for more than 3 days after the procedure [16]. Camecho et al. recorded maximum pain and swelling after oral mucosal biopsy during the first 48 h [17]. Navbi et al., assessed pain during three days after oral mucosal biopsy. A total of 40% of patients reported moderate pain on the day of the biopsy and 58% of patients did not have any pain at all on the third day after the biopsy. Moreover, there was no relationship between the average level of pain and the location of the biopsy, type of biopsy, type of coverage, maximum diameter and type of lesion [18]. This agrees with the results of the present study, where no correlation was found between pain, biopsy site or diagnosis. The rate of pain after skin biopsy is also not well defined and seems related to the size and location of the biopsy site, the depth of the biopsy, the technique used, and individual patient factors.

However, various studies indicate that the Mohs procedure (for treating skin cancer, where individual layers of skin are removed and examined to determine if they are cancer-free) is comparable to oral soft tissue biopsy, because it is generally non-painful and well-tolerated by all genders across all ages [19,20]. In our study, 4 patients out of 695 (0.575%), reported chronic pain at the biopsy site 3 months after the procedure (see Table 2 for pain and patient characteristics). All four were women, which is congruent with most other publications that describe a higher rate of post-operative pain in women, e.g., female gender was associated with more severe postoperative pain after root-canal treatment in a cohort of 270 patients [21], and after Mohs Micrographic Surgery [19].

Although we did not include a VAS pain score in the long-term follow-up of the four patients with PPTN, the fact that they did not need analgesics means that they were experiencing mild pain. It is important to note the considerable overlap between inflammatory and neuropathic pain processes, making it difficult to differentiate whether a particular chronic pain is nociceptive, inflammatory or neuropathic since all three mechanisms are involved in healing following trauma [22]. Yet, the mild pain that started immediately after minor surgery, at the site of the procedure may have a non-inflammatory source; most probably neuropathic rather than somatic.

The very low incidence of chronic pain lasting more than 3 months in the large cohort of the current investigation compared to other oral procedures (e.g., root canal treatments, implants, extractions) may be due to the superficial nature of the soft tissue biopsy procedure, i.e., far from the major sensory nerves, the lack of bone involvement and/or the rapid healing of the oral mucosa.

Due to the retrospective design of this study, certain details pertaining to pain characteristics, including the diagnostic methodology, employed pain assessment scale, frequency of examinations for persistent pain, and the temporal dynamics of pain, were not documented. However, it is noteworthy that the observed pain intensity in the study cohort was as mild, thereby obviating the need for specialized pain clinic evaluation and intervention. Notwithstanding these limitations, the manuscript still offers valuable contributions to the scientific discourse in this field.

In conclusion, the study revealed an exceedingly low occurrence of chronic pain persisting for more than 3 months after intraoral soft-tissue biopsies (0.57%). All cases of chronic pain following the biopsy procedure occurred in female patients, and their pain was mild without the need for medications. There was no apparent correlation between the biopsy site, histopathological diagnosis, and pain occurrence, suggesting that pain can arise at different sizes and depths of biopsy sampling.

Future research should focus on investigating chronic neuropathic pain following hard tissue biopsies in the oral cavity. It is also important to examine the factors that influence the occurrence of chronic pain, such as analgesic use. These findings will provide additional insights into the safety and efficacy of oral biopsies and help inform clinical decision-making for both healthcare providers and patients.

**Supplementary Materials:** The following supporting information can be downloaded at: <https://www.mdpi.com/article/10.3390/app13116719/s1>, Table S1: Soft tissue biopsy specific diagnosis list.

**Author Contributions:** A.C., R.D., R.Y., A.R. and Y.H. made substantial contributions to the study conception and design, acquisition of data, and analysis and interpretation of data; Y.S., R.C. and N.K. drafted the manuscript and provided critical psychological interpretation. D.J.A., Y.H. and R.D. wrote, revised and approved the manuscript. All authors have read and agreed to the published version of the manuscript.

**Funding:** This research received no external funding.

**Institutional Review Board Statement:** The institutional review board approved the study (#0329-21-HMO).

**Informed Consent Statement:** Informed consent was obtained from all subjects involved in the study.

**Conflicts of Interest:** The authors have declared no conflict of interest.

## References

1. Mota-Ramírez, A.; Silvestre, F.J.; Simó, J.M. Oral biopsy in dental practice. *Med. Oral Patol. Oral Cir. Bucal* **2007**, *12*, E504–E510. [[PubMed](#)]
2. Else, R. Biopsy—Principles and specimen management: In practice. *InPractice* **1986**, *8*, 112–116. [[CrossRef](#)] [[PubMed](#)]
3. International Classification of Orofacial Pain, 1st edition (ICOP). *Cephalalgia Int. J. Headache* **2020**, *40*, 129–221. [[CrossRef](#)]
4. Headache Classification Committee of the International Headache Society (IHS). The International Classification of Headache Disorders, 3rd edition. *Cephalalgia Int. J. Headache* **2018**, *38*, 1–211. [[CrossRef](#)]
5. Marbach, J.J. Is phantom tooth pain a deafferentation (neuropathic) syndrome?: Part I: Evidence derived from pathophysiology and treatment. *Oral Surg. Oral Med. Oral Pathol.* **1993**, *75*, 95–105. [[CrossRef](#)] [[PubMed](#)]
6. Haviv, Y.; Zadik, Y.; Sharav, Y.; Benoliel, R. Painful Traumatic Trigeminal Neuropathy: An Open Study on the Pharmacotherapeutic Response to Stepped Treatment. *J. Oral Facial Pain Headache* **2014**, *28*, 52–60. [[CrossRef](#)] [[PubMed](#)]
7. Tinastepe, N.; Oral, K. Neuropathic pain after dental treatment. *Ağrı* **2013**, *25*, 1–6. [[CrossRef](#)] [[PubMed](#)]
8. Polycarpou, N.; Ng, Y.-L.; Canavan, D.; Moles, D.R.; Gulabivala, K. Prevalence of persistent pain after endodontic treatment and factors affecting its occurrence in cases with complete radiographic healing. *Int. Endod. J.* **2005**, *38*, 169–178. [[CrossRef](#)]
9. Renton, T.; Yilmaz, Z. Profiling of patients presenting with posttraumatic neuropathy of the trigeminal nerve. *J. Orofac. Pain* **2011**, *25*, 333–344.
10. Renton, T. Persistent Pain after Dental Surgery. *Rev. Pain* **2011**, *5*, 8–17. [[CrossRef](#)]
11. Peñarrocha, M.A.; Peñarrocha, D.; Bagán, J.V.; Peñarrocha, M. Post-traumatic trigeminal neuropathy. A study of 63 cases. *Med. Oral. Patol. Oral Cir. Bucal* **2012**, *17*, e297–e300. [[CrossRef](#)]
12. Renton, T.; Adey-Viscuso, D.; Meechan, J.G.; Yilmaz, Z. Trigeminal nerve injuries in relation to the local anaesthesia in mandibular injections. *Br. Dent. J.* **2010**, *209*, E15. [[CrossRef](#)]
13. Benoliel, R.; Kahn, J.; Eliav, E. Peripheral painful traumatic trigeminal neuropathies. *Oral Dis.* **2012**, *18*, 317–332. [[CrossRef](#)] [[PubMed](#)]

14. Nixdorf, D.R.; Moana-Filho, E.; Law, A.S.; McGuire, L.; Hodges, J.S.; John, M.T. Frequency of Persistent Tooth Pain after Root Canal Therapy: A Systematic Review and Meta-Analysis. *J. Endod.* **2010**, *36*, 224–230. [[CrossRef](#)] [[PubMed](#)]
15. Waasdorp, M.; Krom, B.P.; Bikker, F.J.; van Zuijlen, P.P.M.; Niessen, F.B.; Gibbs, S. The Bigger Picture: Why Oral Mucosa Heals Better Than Skin. *Biomolecules* **2021**, *11*, 1165. [[CrossRef](#)]
16. Kearns, H.P.; McCartan, B.E.; Lamey, P.J. Patients' pain experience following oral mucosal biopsy under local anaesthesia. *Br. Dent. J.* **2001**, *190*, 33–35. [[CrossRef](#)] [[PubMed](#)]
17. Camacho-Alonso, F.; Lopez-Jornet, P. Study of pain and swelling after oral mucosal biopsy. *Br. J. Oral Maxillofac. Surg.* **2008**, *46*, 301–303. [[CrossRef](#)] [[PubMed](#)]
18. Navabi, N.; Salehi, A.; Zarei, M.; Borna, R. Pain experience after oral mucosal biopsy: A quasi-experimental study. *J. Oral Health Oral Epidemiol.* **2012**, *1*, 87–92.
19. Shir-Az, O.; Berl, A.; Shalom, A. Evaluation of Pain After Mohs Micrographic Surgery: A Prospective Study. *Dermatol. Surg.* **2022**, *48*, 601–605. [[CrossRef](#)]
20. Brahe, C.A.; Hardy, C.L.; Miladi, A. Postoperative Pain After Mohs Micrographic Surgery is Well Tolerated Regardless of Psychological and Pain-Related Comorbidities. *Dermatol. Surg.* **2021**, *47*, 462–466. [[CrossRef](#)]
21. Alí, A.; Olivieri, J.G.; Duran-Sindreu, F.; Abella, F.; Roig, M.; García-Font, M. Influence of preoperative pain intensity on postoperative pain after root canal treatment: A prospective clinical study. *J. Dent.* **2016**, *45*, 39–42. [[CrossRef](#)] [[PubMed](#)]
22. Sharav, Y.; Benoliel, R. *Orofacial Pain and Headache*, 2nd ed.; Quintessence Publishing: Batavia, IL, USA, 2015.

**Disclaimer/Publisher's Note:** The statements, opinions and data contained in all publications are solely those of the individual author(s) and contributor(s) and not of MDPI and/or the editor(s). MDPI and/or the editor(s) disclaim responsibility for any injury to people or property resulting from any ideas, methods, instructions or products referred to in the content.