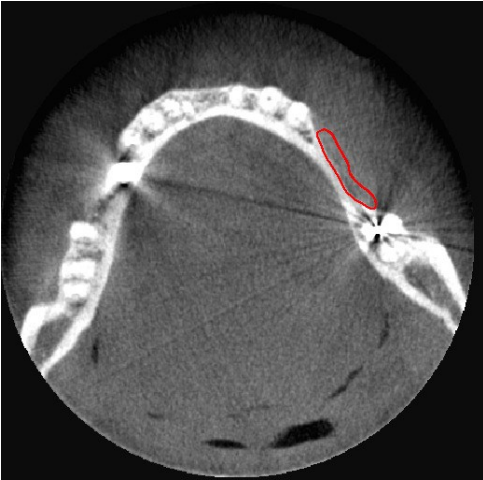
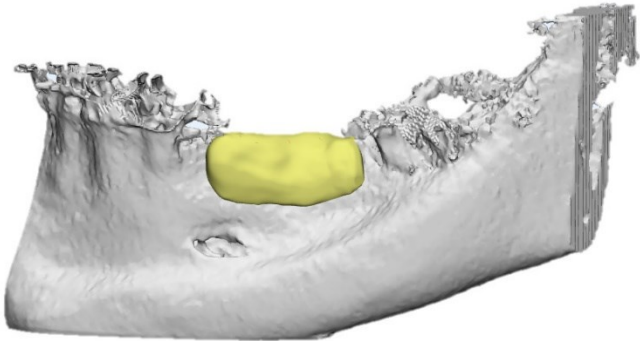


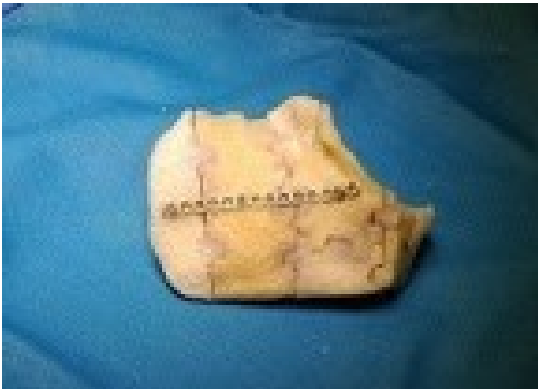# Supplementary Materials



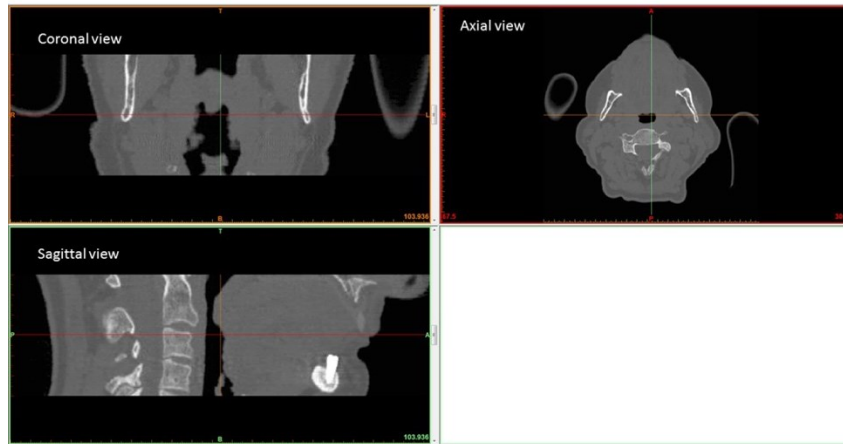
**Figure S1.** clinical case #1, patient with hypodontia in the lower dental arch, highlighted in red.



**Figure S2.** clinical case #1, patient with hypodontia in the lower dental arch; 3D render model of mandibular bone with the design of the custom made SmartBone® on Demand™ graft.



**Figure S3.** case #5, custom-made SBoD grafts built bed-side, prior to implantation, to reconstruct the temporal and sphenoid bones of the skull which had been previously removed due to the tumor.



**Figure S4.** exemplificative clinical images converted and displayed by Mimics software, according to specific instructions regarding the orientation of the individual slices.