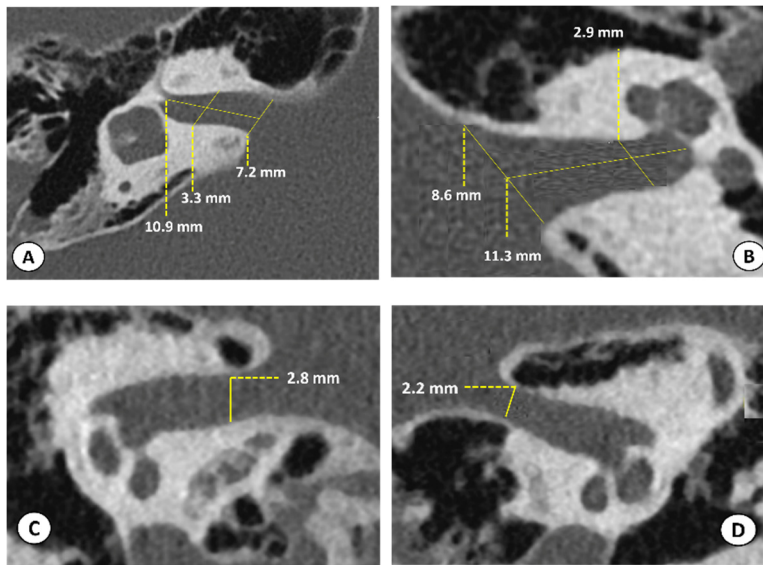


Supplementary Data

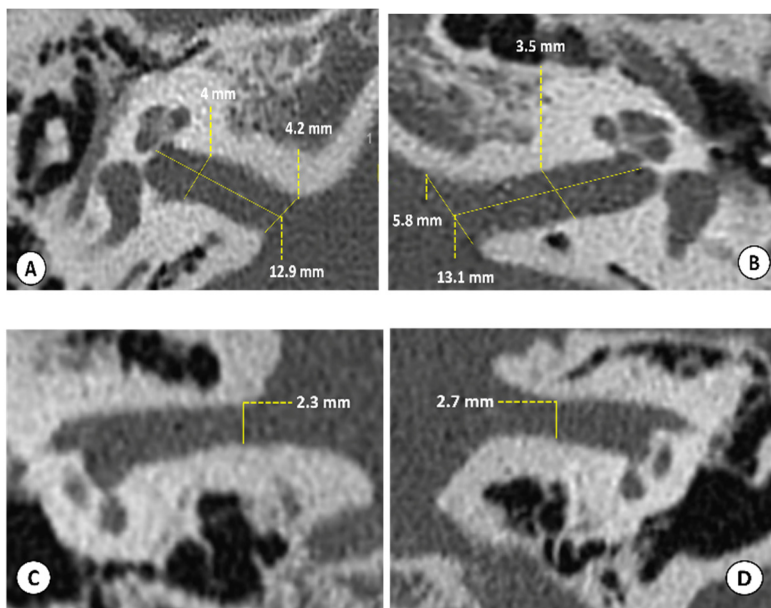
HRCT of temporal bones (IAC sections), for the right and left ear, in both axial and coronal plans of Group I patients (1 to 8). A: Right ear, axial plane, B: Left ear, axial plane, C: Right ear, coronal plane, and D: Left ear, coronal plane.

Note that these figures show uni- or bilateral narrowing of the IAC. Narrowing can be visualized in both axial and/or coronal plans, more pronounced in the coronal plans suggesting a developmental process.

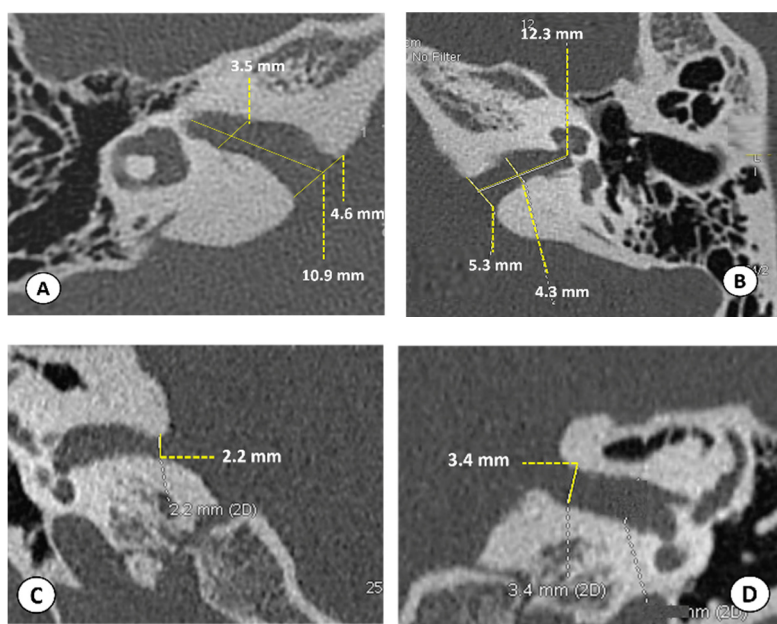
1:



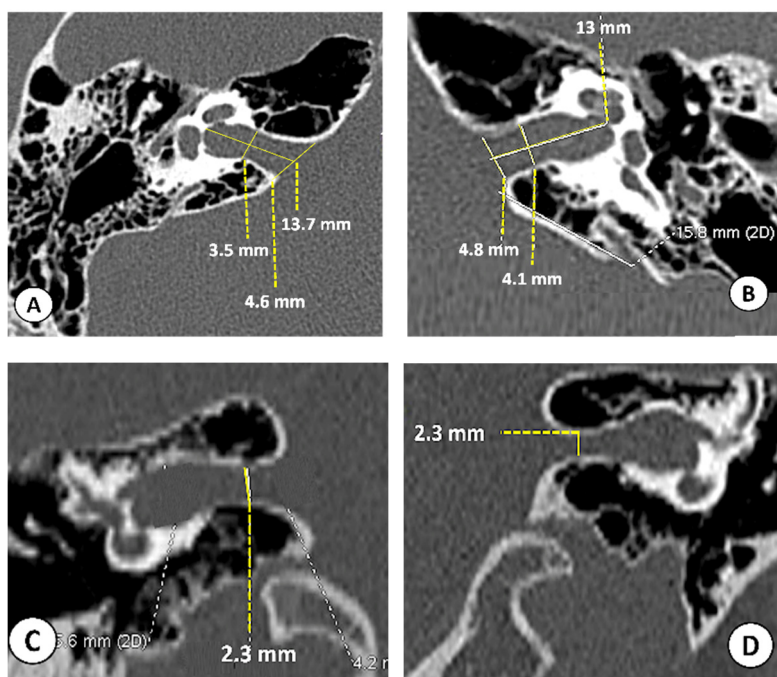
2:



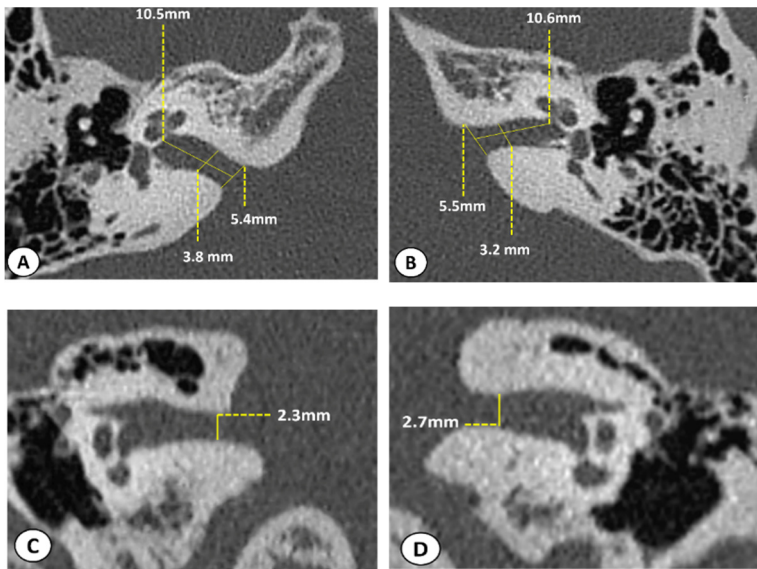
3:



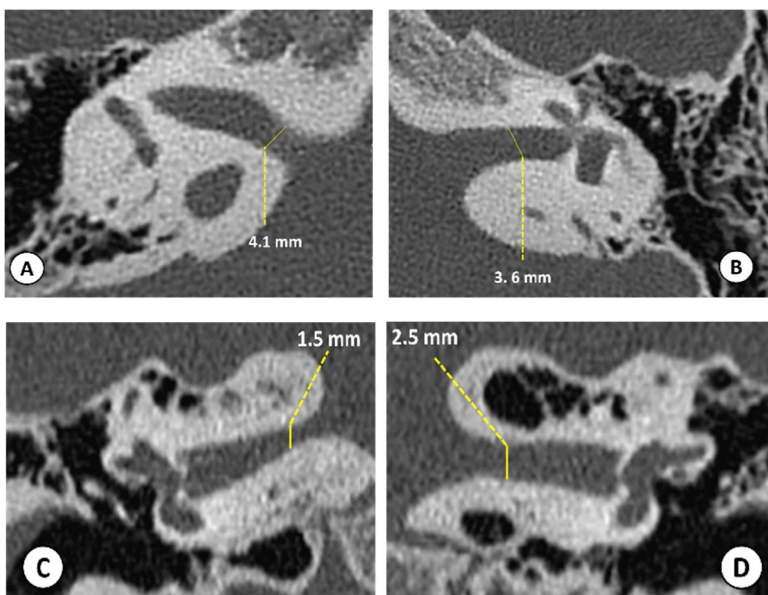
4:



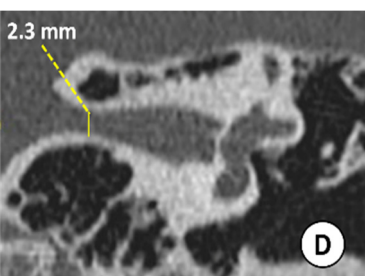
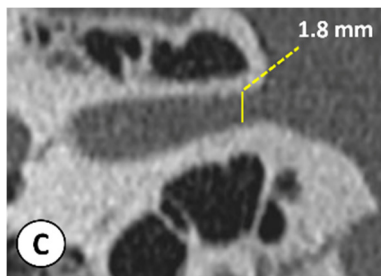
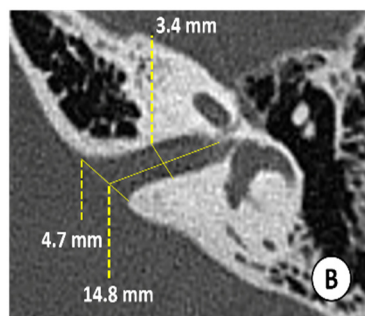
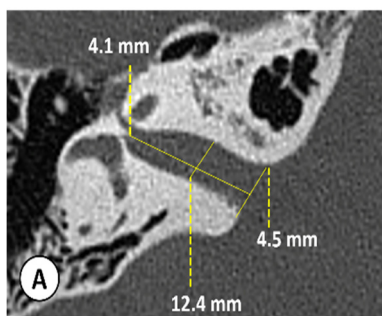
5:



6:



7:



8:

