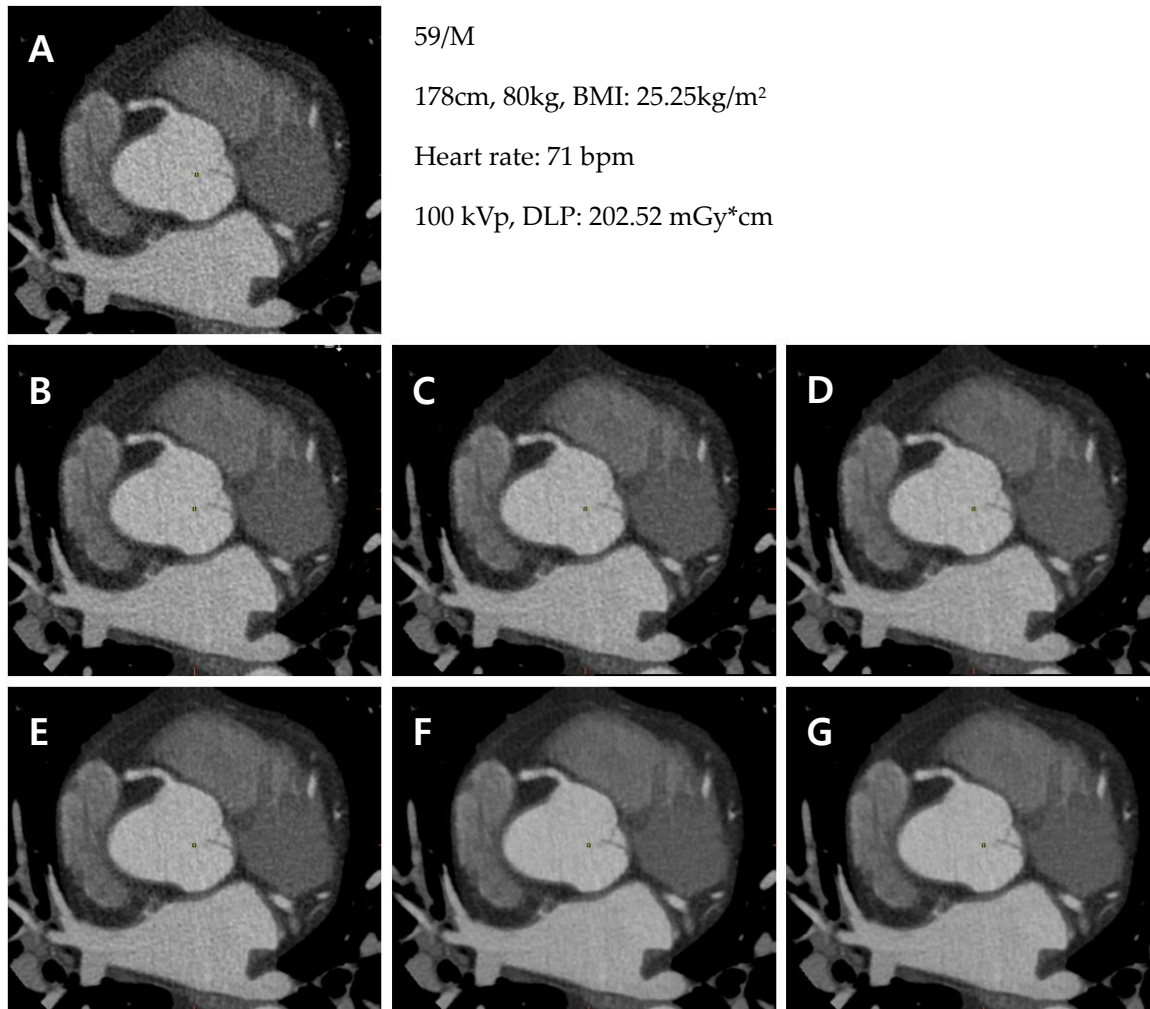


Supplementary Figure

Figure S1. Representative CCTA images with 7-different reconstruction methods



CCTA of a 59-year-old male.

(A) Reconstructed to FBP;

(B) Reconstructed to MBIR-40%; (C) Reconstructed to MBIR-60%; (D) Reconstructed to MBIR-80%;

(E) Reconstructed to DLIR-L; (F) Reconstructed to DLIR-M; (G) Reconstructed DLIR-H