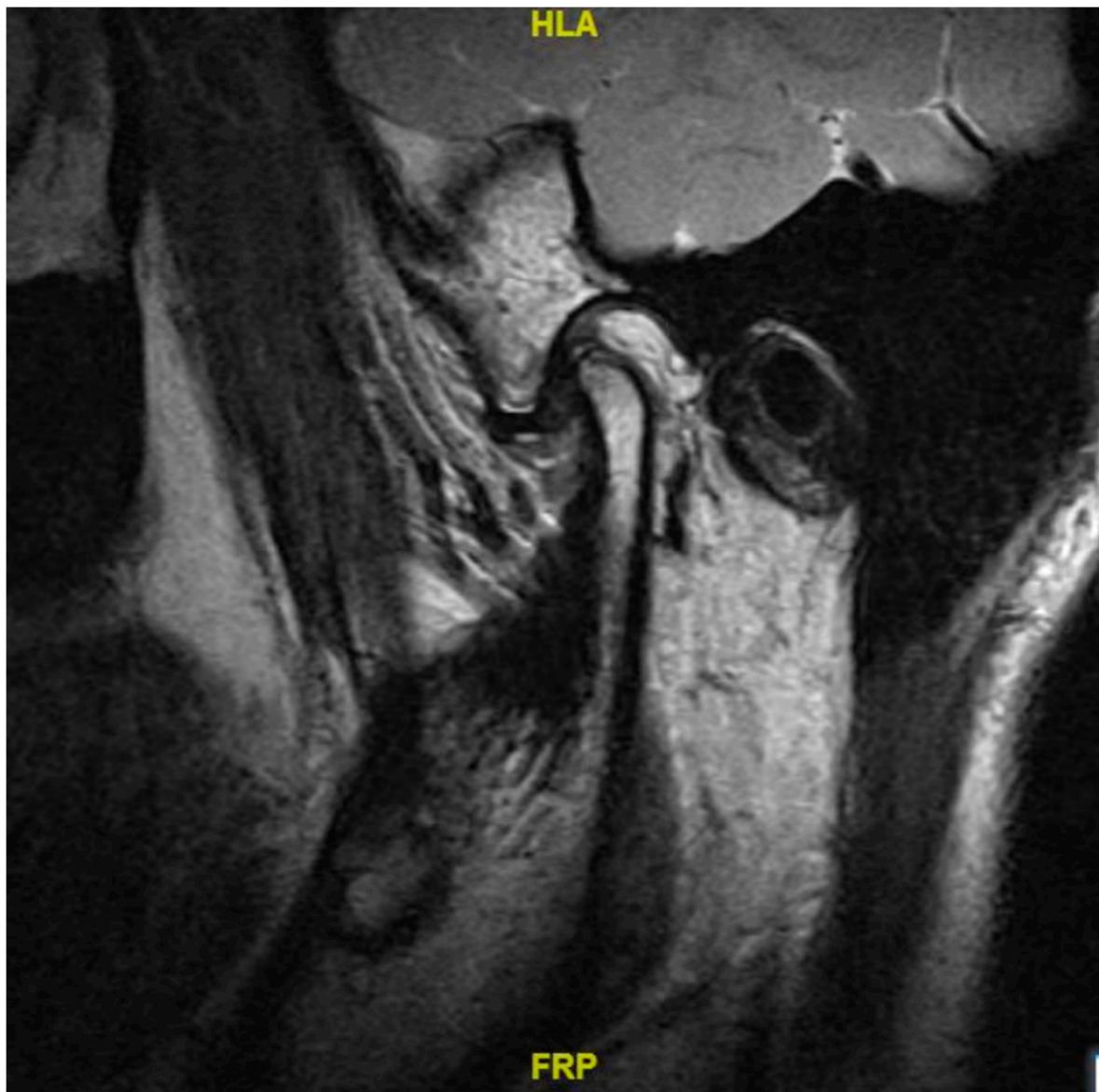
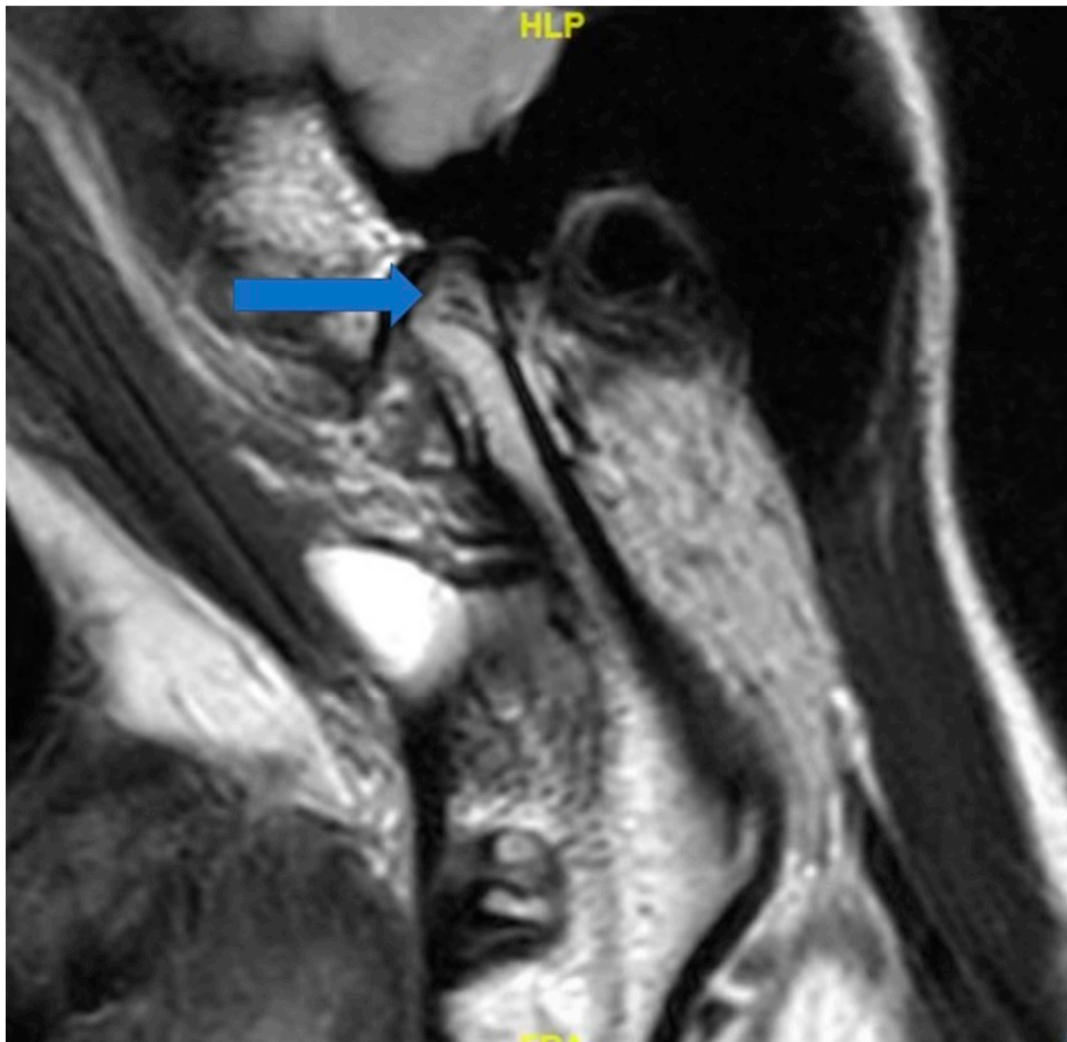

Supplementary Materials:



**Figure S1.** TMJ MRI revealed bone destruction pretreatment and disc displacement without reduction.



**Figure S2.** New bone(blue arrow) was found by MRI 6 months after surgery and the disc is reduced to normal position by surgery.