

Review

Treatment of Melasma on Darker Skin Types: A Scoping Review

Nomakhosi Mpfana ^{1,2,*} , Buyisile Chibi ³, Tronel Visser ⁴, Michael Paulse ⁵, Avenal Jane Finlayson ⁶ , Shanaz Ghuman ², Nceba Gqaleni ^{7,8}, Ahmed A. Hussein ⁹  and Ncoza Cordelia Dlova ¹

¹ Dermatology Department, Nelson R Mandela School of Medicine, University of KwaZulu-Natal, Durban 4000, South Africa

² Department of Somatology, Durban University of Technology, Durban 4000, South Africa

³ Centre for Rural Health, School of Nursing and Public Health, University of KwaZulu-Natal, Durban 4000, South Africa

⁴ Tuks Undergraduate Research Forum, University of Pretoria, Pretoria 0028, South Africa

⁵ Faculty of Health and Wellness Sciences, Cape Peninsula University of Technology, Cape Town 8000, South Africa

⁶ Alan Pittendrigh Library, Durban University of Technology, Durban 4000, South Africa

⁷ Discipline of Traditional Medicine, University of KwaZulu-Natal, Durban 4000, South Africa

⁸ Faculty of Health Sciences, Durban University of Technology, Durban 4000, South Africa

⁹ Department of Chemistry, Cape Peninsula University of Technology, Bellville 7535, South Africa

* Correspondence: mpofananpcut@gmail.com; Tel.: +21-313-735-863 or +27-786-087-119

Abstract: Melasma is a challenging chronic skin condition associated with hyperpigmentation and unknown aetiology. This scoping review maps evidence of available treatments and their effectiveness in darker skin types. A comprehensive, systematic online search was conducted in Scopus, PubMed, CINAHL Complete, Cochrane, ScienceDirect, and Web of Science Core Collection. All eligible titles were exported to an EndNote20 library (Clarivate analytics, US). Thematic content analysis was performed to summarise data on current melasma treatments for darker skin types. The quality of included articles was appraised using the Mixed Methods Appraisal Tool (MMAT) 2018 version. A total of 2863 articles were retrieved from the databases, and 10 met the eligibility criteria following abstract and full-text screening. Our findings demonstrate that topical treatments, chemical peels, lasers, and tranexamic acid are common treatment modalities used in darker skin types. Although these treatments may be effective in the short term, they bring about undesirable side effects and sometimes worsen or result in reoccurrences of melasma. Based on the evidence mapped, current treatment modalities are not suitable for darker skin types. There are very few studies conducted on individuals of African descent. Further research is necessary to investigate treatment interventions that may be user-friendly when dealing with darker skin types.

Keywords: melasma; treatment; darker skin types; Fitzpatrick skin types IV–VI; mapping review



Citation: Mpfana, N.; Chibi, B.; Visser, T.; Paulse, M.; Finlayson, A.J.; Ghuman, S.; Gqaleni, N.; Hussein, A.A.; Dlova, N.C. Treatment of Melasma on Darker Skin Types: A Scoping Review. *Cosmetics* **2023**, *10*, 25. <https://doi.org/10.3390/cosmetics10010025>

Academic Editors: Mohamad Goldust and George Kroumpouzou

Received: 10 January 2023

Revised: 22 January 2023

Accepted: 23 January 2023

Published: 27 January 2023



Copyright: © 2023 by the authors. Licensee MDPI, Basel, Switzerland. This article is an open access article distributed under the terms and conditions of the Creative Commons Attribution (CC BY) license (<https://creativecommons.org/licenses/by/4.0/>).

1. Introduction

Melasma is a common and acquired human melanogenesis dysfunction characterised by symmetric hyper-pigmented macules with irregular borders and patches of light to dark-brown skin on the face's forehead, cheeks, upper lip, and chin [1–3]. While being characterised as a facial disorder, melasma also occurs in non-facial areas such as the chest, arms, and neck [4]. Although melasma pathogenesis has not been linked to any specific gene, it is found to be more common in females and males of Hispanic, Asian, and African descent [5–8]. A study conducted in South Africa reported that pigmentation disorders are among the top five skin conditions, with melasma accounting for many of the cases [9].

The specific cause of melasma remains unknown; however, its onset is often linked to various aetiological factors. Pregnancy, the use of oral contraceptives, improper safe sun practices, pollution, stress, genetic predisposition, hormonal changes, some cosmetic ingredients, phototoxic drugs, and hypothyroidism have been associated with the onset

of melasma [10,11]. Some studies suggest a genetic predisposition for melasma in those of African ancestry [12,13]. Exposure to ultraviolet (UV) rays is another risk factor for melasma as it is more prevalent in equatorial countries. Melasma is difficult to treat due to its complicated pathogenesis, particularly in darker-skinned individuals [14,15]. Melasma is traditionally treated using a variety of treatment strategies such as trigger avoidance, photo-protection, chemical peels, lasers, and topical medications such as Kligman's formula and hydroquinone, with variable success rates [1,10,16,17].

Being a facial-disfiguring lesion, melasma has been reported to impact negatively upon patients' overall well-being. Quality of life (QoL) studies have revealed that melasma affects interpersonal interactions, especially since melasma alters a person's appearance [18–22]. The World Health Organization (WHO) describes QoL as a multi-dimensional concept that assesses a person's insights into holistic well-being. This includes physical, mental, and social health [3,15,22–24]. The feelings of shame, frustration, embarrassment, suicidal thoughts, low self-esteem, and demotivation to socialise have also been reported [19,25]. Many patients afflicted with the condition may spend a fortune on medical and cosmetic treatments; sadly, most treatment results are poor and unsatisfactory.

Challenges in treating melasma have resulted in a plethora of anti-melanogenesis treatments. Hydroquinone is a first-line topical medical depigmentation therapy that is used alone or in combination with other treatments such as lasers and tranexamic acid [26–28]. The majority of documented treatments have relied primarily on the use of chemical methods [29–32], laser therapy [33–38], and topical creams [39–43]. However, the effectiveness of these therapeutic modalities is limited by their adverse effects, especially in darker skin types [44]. For this study, darker skin types refer to the Fitzpatrick skin type scale (i.e., types IV–VI). Recent research has revealed the effectiveness of tranexamic acid (TA) against hypermelanosis; however, shortfalls in the number of controlled studies, a lack of follow-up treatment periods, and the establishment of optimum doses remain underexplored and provide scope for further investigation. Most documented studies have been performed with Indian and Asian patients, making it a challenge to generalise the results [11,45–48].

Despite numerous treatment options available to treat melasma, it remains a medical concern, as the problem still exists. There is growing interest in the potential use of medicinal plants in managing hypermelanosis and uneven skin tone, as they are perceived as being safe [49]. Historically, one of the most medicinally beneficial plants in rural areas of South Africa's Eastern Cape and KwaZulu-Natal provinces is the *Cassipourea flanaganii* (*C. flanaganii*). The ground crude bark is used to protect the skin from the sun, enhance the complexion, and even out skin tone [49–52]. The use of *C. flanaganii* as a hypopigmentation therapy requires further study to investigate its potential use as a substitute for hydroquinone. Recently, *C. flanaganii* isolates were identified to have low cytotoxicity toward melanin-producing skin cells in vitro, as demonstrated by a significant decrease in melanin content in these cells [50]. The purpose of this scoping review is to identify and summarise the most effective, tolerable, and safe treatment interventions for melasma in people with darker skin. Gleaned evidence will be used to promote best practices and add value to the development of products specifically for darker skin individuals.

2. Methods and Materials

2.1. Overview

This scoping review aims to develop a novel approach to enhance the scientific understanding of the use of medicinal plants for the treatment of hypermelanosis, which can be produced locally in South Africa, and which may help address melasma in people with darker skin.

The research was carried out following the study protocol available at <https://osf.io/ru3jc/> (accessed on 25 January 2023). The review was guided by the Arksey and O'Malley framework [53], further advanced by Levac et al., and the Joanna Briggs Institute 2020 recommendations [54]. By this methodological framework, the review was carried out in the five stages

listed: 1. determining the research question, 2. locating relevant studies, 3. study selection, 4. data charting, and 5. data collation, summarising and reporting on the articles. The sixth optional stage involving consultation (knowledge translation) with stakeholders to provide greater insight beyond those found in the literature (Arksey and O'Malley (2005) [53]) was not required, as this scoping review did not include stakeholder consultation. The findings of this study were reported according to the Preferred Reporting Items for Systematic Reviews and Meta-Analyses extension for Scoping Reviews (PRISMA-ScR) checklist, File S4 [55] available on figshare at 10.6084/m9.figshare.21730970 (accessed on 27 January 2023).

2.1.1. Identifying the Research Question

This paper aims to systematically evaluate evidence from the literature on treatment interventions used for melasma in darker-skin-type individuals and to answer the research question: *What are the most effective, tolerable, and safe treatment interventions for melasma in darker skin types?* To answer this research question, the Population, Exposure, and Outcome (PEO) framework, as illustrated in Table 1 below, was used to assess the research question's eligibility for review. Both males and females with darker skin types and melasma on the face participated in the studies. For exposure, all studies on melasma treatments were included. In the outcomes, the efficacy of treatment, reported toxicity, and side effects were all considered.

Table 1. The framework for determining the research question's eligibility.

Criteria	Determinants
Population	Darker-skin-type people (skin types IV–VI) with diagnosed epidermal, dermal, or mixed melasma.
Exposure	All types of treatment for melasma, e.g., self-applied topical interventions or combinations of topical interventions and oral interventions.
Outcome	(1) Was the treatment effective? (2) Was the treatment safe? (3) Reported toxicity or relapse.

2.1.2. Identifying Appropriate Studies

We carried out a broad and replicable literature search using six academic databases, namely Scopus, PubMed, Cochrane, CINAHL Complete, ScienceDirect, and the Web of Science Core Collection (Supplementary Material File S1) to retrieve published peer-reviewed articles reporting on primary research based on experiments, observations, or simulations [56]. All articles published from database inception to November 2021 were considered. Search strategies were developed by the principal investigator (PI) together with a librarian. A combination of free-text keywords as well as Medical Subject Headings (MeSH) was used when conducting the literature searches. Search terms used included "melanosis", "melasma", "skin pigmentation", "dyschromia", "hyperpigmentation", "chloasma", "Fitzpatrick skin IV to VI", "Fitzpatrick skin IV–VI", "Fitzpatrick VI", "Fitzpatrick IV", "Black", "Indian", "mixed ancestry", "darker skin type*", "African Continental Ancestry Group", "mixed race", "quality of life", "prevalence", "therapy", "therapeutics", and "treatment". The Boolean terms OR and AND were used to combine the keywords into search strings. For example: (melasma OR pigmentation OR dyschromia OR hyperpigmentation OR chloasma) AND ("quality of life" OR prevalence OR therapy OR therapeutics OR treatment).

Peer-reviewed articles in any language were considered if they met the following criteria for inclusion:

- Evidence of facial melasma
- Evidence of facial melasma treatment interventions;
- Evidence of facial melasma prevalence;
- Evidence of facial melasma's impact on quality of life.

Studies were excluded if they were review studies or grey literature or if they did not meet any of the criteria for inclusion.

2.1.3. Selecting Studies

An EndNote20 library (Clarivate analytics, US) was used to save all eligible articles as well as identify and eliminate all duplicates. Articles were screened in three stages according to the title, abstract, and full text. A screening tool that factored the inclusion and exclusion criteria and the PEO elements was created by the principal investigator and piloted by the reviewers using 10 articles. The tool was then adjusted accordingly.

In the second phase of selection, the PI, in parallel with the co-reviewer (TV), screened the abstracts of the included articles using the screening tool. Following this, the reviewers discussed the selected articles and any discrepancies were resolved by consensus. In the last phase, two reviewers (NM) and (TV) screened the full-text articles for all eligible abstracts. Any discrepancies were resolved by a third screener (SG). The level of agreement after the full-text screening was determined using Kappa statistics. The following is how the Kappa statistics were interpreted: 0.1 indicates no agreement, 0.10–0.20 indicates no to slight agreement, 0.21–0.40 indicates fair, 0.41–0.60 indicates moderate, 0.61–0.80 indicates substantial, and 0.81–1.00 indicates almost perfect agreement.

2.1.4. Charting the Data

Using an electronic data-charting form, data were collected from each of the included articles. For consistency, the two independent reviewers piloted the data-charting form with a random sample of five included articles. All recommended modifications were implemented by the feedback provided by the two independent reviewers. Extracted data from the included studies summarised the most effective, tolerable, and safe treatment interventions for melasma on darker skin types.

2.2. Quality Appraisal

The Mixed Methods Appraisal Tool (MMAT), version 2018, was used to assess the methodological quality of the included studies [57]. As stipulated in the MMAT guidelines, each article's research design was evaluated. Each study's scores were calculated as a percentage, and then a specific rank was allocated. Studies were ranked low in quality if the score was below or equal to 50%, deemed average quality if the score was between 51 and 75%, and received a high-quality rating if it ranged from 76 to 100%.

2.3. Results Collection, Summarisation, and Reporting

We used thematic analysis to extract evidence to answer the research question. The emerging themes from the data were narratively summarised.

2.4. Ethical Consideration

This scoping review did not require ethical approval as the review relied on the synthesis of existing literature available in the public domain.

3. Results

3.1. Screening Results

The flowchart of the PRISMA-ScR method (Figure 1) reports on the inclusion and exclusion of studies used for this review. Firstly, the literature search yielded 2853 articles (Table 2, also available at [10.6084/m9.figshare.21730970](https://doi.org/10.6084/m9.figshare.21730970)) (accessed on 27 January 2023) from six different databases. Following the removal of 867 duplicate titles, 1986 titles were identified to be eligible. A further 1566 records were removed. The remaining 420 articles were included for abstract screening. Of the 420 articles, 341 articles did not meet the inclusion criteria, as some studies were conducted on all skin types and some were conducted on animals or investigated extra-facial melasma and were excluded. The remaining 79 articles met the inclusion criteria for full-article screening. Following the full-article screening, 69 articles were excluded, as 42 articles included all skin types, 20 articles did not meet the eligibility requirements, 1 article was based on an animal study, 4 articles were reviews (not original research), and 1 was a case report. Ultimately, data were extracted from 10 articles.

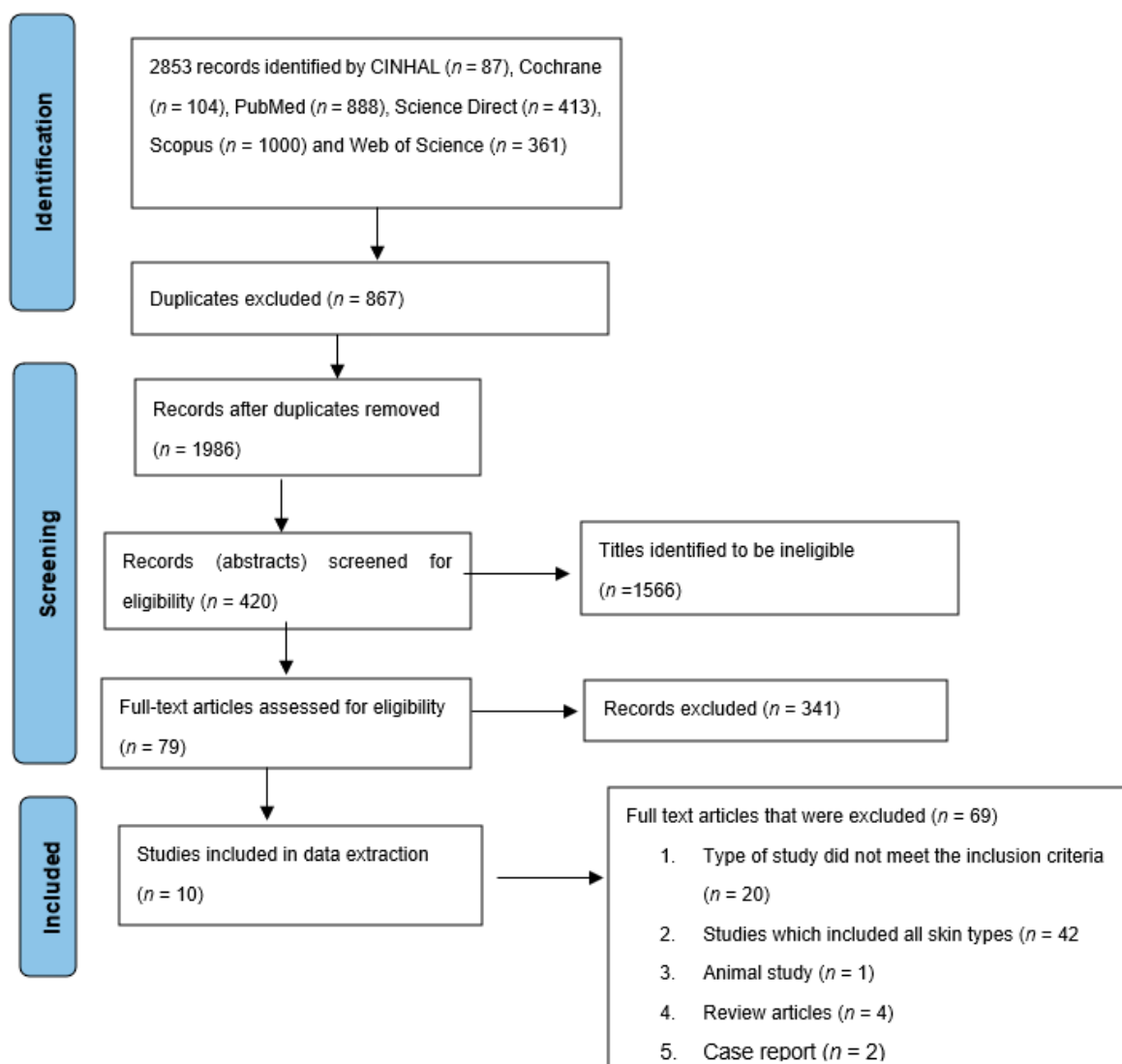


Figure 1. Flow diagram demonstrating the literature search and study selection.

There was 96.2% agreement versus 50.0% expected by chance, which, according to the Cohen Kappa value of 0.901 (SE = 0.056, $t = 7.960$, $p < 0.001$), is indicative of an “almost perfect” agreement [58]. Similarly, McNemar’s Chi-squared statistic, $\chi^2 = 0.333$, suggests that there is no statistically significant difference in the proportions of yes/no responses by the reviewers with a p -value = 0.564. This confirms the agreement between the reviewers.

3.2. Characteristics of the Studies Included

Table 3 summarises the characteristics of the articles included. The studies that were considered were published between 1994 and 2020. These articles provide evidence of research carried out in the listed countries: India [6,11,59–61], USA [62], Thailand [63], South Africa [15], Korea [64], and China [65]. Findings from these articles were conveyed as randomised comparative [11,60], prospective randomised single-blind [6], prospective single-blind [6,59], randomised vehicle-controlled [62], prospective pilot [65], randomised controlled trial [8], and experimental studies [15,63,64]. The primary healthcare settings included dermatology outpatient clinics, medical schools, tertiary care hospitals, as well as private practice rooms. Study participants were mainly Indian [6,11,59–61]. The total number of participants from all included studies was 420, of which 398 were female participants and 22 were male (Table 3). Drop-outs due to side effects did not make a significant difference in any of the included studies as the number was very low [6].

Table 2. Results from searched data bases.

Date of Search	Electronic Data base	Keywords searched	Number of publications retrieved
12/10/21	PubMed	((“melanosis”[MeSH Terms] OR Melasma [Text Word] OR melanosis [Text Word] OR “skin pigmentation”[MeSH Terms] OR Skin Pigmentation [Text Word] OR dyschromia [Text Word] OR “hyperpigmentation”[MeSH Terms] OR hyperpigmentation [Text Word] OR Chloasma [Text Word] AND (humans[Filter])) AND ((“Quality of Life”[Mesh]) OR “Prevalence”[Mesh] OR “quality of life”[TW] OR prevalence[tw] OR “therapy”[Subheading] OR “therapeutics”[MeSH Terms] OR treatment[Text Word] AND (Fitzpatrick skin IV to VI[TW] OR Fitzpatrick skin IV—VI[TW] OR Fitzpatrick VI[TW] OR Fitzpatrick IV[TW] OR Black[TW] OR Indian[TW] OR “mixed ancestry”[TW] OR “darker skin type*”[TW] OR “African Continental Ancestry Group”[Mesh] OR “mixed race”[TW])	888
15/10/21	Scopus	melanosis OR Melasma OR “skin pigmentation” OR dyschromia OR hyperpigmentation OR Chloasma AND “Fitzpatrick skin IV to VI” OR “Fitzpatrick skin IV—VI” OR “Fitzpatrick VI” OR “Fitzpatrick IV” OR Black OR Indian OR “Mixed ancestry” OR “darker skin types” OR “African Continental Ancestry Group” OR “mixed race” AND “quality of life” OR prevalence OR therapy OR therapeutics OR treatment	1000
15/10/21	CINAHL	AB (melanosis OR Melasma OR “skin pigmentation” OR dyschromia OR hyperpigmentation OR Chloasma) AND AB (Black OR Indian OR “Mixed ancestry” OR “darker skin type*” OR “African Continental Ancestry Group” OR “mixed race”) AND AB (“quality of life” OR prevalence OR therapy OR therapeutics OR treatment)	87
15/10/21	ScienceDirect	(Melasma OR hyperpigmentation) AND (“quality of life” OR prevalence OR treatment) AND (“Mixed ancestry” OR “darker skin type)	413
15/10/21	Web of Science Core Collection	melanosis OR Melasma OR “skin pigmentation” OR dyschromia OR hyperpigmentation OR Chloasma (Topic) AND “Fitzpatrick skin IV to VI” OR “Fitzpatrick skin IV—VI” OR “Fitzpatrick VI” OR “Fitzpatrick IV” OR Black OR Indian OR “Mixed ancestry” OR “darker skin types” OR “African Continental Ancestry Group” OR “mixed race” (Topic) AND “quality of life” OR prevalence OR therapy OR therapeutics OR treatment (Topic)	361
15/10/21	Cochrane Library	melanosis OR Melasma OR “skin pigmentation” OR dyschromia OR hyperpigmentation OR Chloasma [in Title Abstract Keyword] AND “Fitzpatrick skin IV to VI” OR “Fitzpatrick skin IV—VI” OR “Fitzpatrick VI” OR “Fitzpatrick IV” OR Black OR Indian OR “Mixed ancestry” OR “darker skin types” OR “African Continental Ancestry Group” OR “mixed race” [in Title Abstract Keyword] AND “quality of life” OR prevalence OR therapy OR therapeutics OR treatment [in Title Abstract Keyword]—(Word variations have been searched)	104

Table 3. Study characteristics.

Author (Year)	Title of the Study	Aim of the Study	Country	Study Design, N	Study Setting	Population and Ethnicity	Gender	Age	Skin Types
Chen 2019 [65]	Efficacy and Safety Evaluation of Picosecond Alexandrite Laser with a Diffractive Lens Array for Treatment of Melasma in Asian Patients by VISIA Imaging System	To evaluate the efficacy and safety of ps 755-nm alexandrite laser with a DLA-generating, laser-induced optical breakdown, which may be beneficial for melasma treatment.	China	Prospective, pilot study, 20	Dermatology centre	Asian	Female (<i>n</i> = 20)	27–55	IV
Dev 2018 [61]	A Split Face Randomized Controlled Trial Comparing 1064 Nm Q-Switched Nd-YAG Laser and Modified Kligman’s Formulation in Patients with Melasma in Darker Skin.	To compare the efficacy and safety of QSNYL and Kingman’s TC in the treatment of melasma in Fitzpatrick skin types IV and V. More specifically, is QS Nd-YAG laser more efficacious than modified Kligman’s formulation in patients with melasma in darker skin types?	India	Split-face randomised controlled trial, 38	Hospital	Indian	Female (<i>n</i> = 38)	20–50	IV–V
CHUN 2004 [64]	Focal Trichloroacetic Acid Peel Method for Benign Pigmented Lesions in Dark-Skinned Patients	To evaluate the clinical effects of focal TCA peel on pigmented lesions in dark-skinned patients.	Korea	Experimental, 20	Hospital	Korean	Female and male (gender ratio not specified)	24–73	IV–V
Mpofana and Abrahamse 2018 [15]	The Management of Melasma on Skin Types V and VI Using Light Emitting Diode Treatment	This study investigated LED treatment for patients with melasma on darker skin types.	South Africa	Experimental, 60	An aesthetic laser clinic at Life Hospital	Black, Indian, mixed ancestry	Female (<i>n</i> = 60)	25–60	V–VI
Polnikorn 2020 [63]	Treatment of Refractory Melasma in Asians with the Picosecond Alexandrite Laser	The ps alexandrite laser was studied in practice with the DLA and flat optic to treat melasma.	Thailand	Experimental, 60	Hospital	Asian	Female (<i>n</i> = 60)	Not stated	IV–VI
Sarkar et al. 2016 [6]	Comparative Evaluation of Efficacy and Tolerability of Glycolic Acid, Salicylic Mandelic Acid, and Phytic Acid Combination Peels in Melasma	To compare the therapeutic efficacy and tolerability of GA (35%) versus SM acid (20% salicylic/10% mandelic acid) versus phytic combination peels in Indian patients with melasma.	India	Prospective, randomised, single-blinded, 90	Outpatient clinic of Lok Nayak Hospital	Indian	Female (<i>n</i> = 61) and male (<i>n</i> = 11)	18–60	IV–V

Table 3. Cont.

Author (Year)	Title of the Study	Aim of the Study	Country	Study Design, N	Study Setting	Population and Ethnicity	Gender	Age	Skin Types
Sarkar, 2002 [59]	A Comparative Study of 20% Azelaic Acid Cream Monotherapy versus a Sequential Therapy in the Treatment of Melasma in Dark-Skinned Patients	To evaluate the usefulness of a sequential therapy of potent topical steroids +20% AZA cream versus only 20% AZA cream in the treatment of melasma	India	Prospective, single-blind, right-left comparison pilot study, 40	Not stated	Indian	Female ($n = 25$) and male ($n = 5$)	21- 45	IV-V
Kimbrough-green, 1994 [62]	Topical Retinoic Acid (Tretinoin) for Melasma in Black Patients. A Vehicle-Controlled Clinical Trial.	To investigate the efficacy of topical 0.1% all-trans-retinoic acid (tretinoin) in the treatment of melasma in Black patients.	United States	Randomised vehicle-controlled clinical trial, 30	University medical centre	Black	Female ($n = 29$) and male ($n = 1$)	44-67	V-VI
Kumari and Thappa 2010 [60]	Comparative Study of Trichloroacetic Acid versus Glycolic Acid Chemical Peels in the Treatment of Melasma	To compare the therapeutic response of melasma in Indian women to GA 20-35% versus TCA 10-20% for chemical peeling.	India	Comparative study, 30	Hospital	Indian	Female ($n = 38$) and male ($n = 2$)	18 -53	IV-VI
Sharma et al. 2017 [11]	Therapeutic Efficacy and Safety of Oral Tranexamic Acid and that of Tranexamic Acid Local Infiltration with Microinjections in Patients with Melasma: A Comparative Study	To ascertain the comparative efficacy of different routes of administration of TXA.	India	Randomised, comparative study, 100	Dr RP Govt Medical College	Indian	Female ($n = 92$) and male ($n = 8$)	18-55	IV

PS: picosecond; DLA: diffractive lens array; Nd-YAG: neodymium-doped yttrium aluminum garnet; QSNYL: Q-switched Nd: YAG laser; TC: triple combination; TCA: trichloroacetic acid; LED: light-emitting diode; GA: glycolic acid, SM: salicylic-mandelic acid; AZA: azelaic acid; TXA: Tranexamic acid.

3.3. The Level of Evidence

The methodological quality of the included articles was evaluated using the MMAT tool, 2018 version [57]. The ten studies that were evaluated for methodological quality received scores ranging from 70% to 90%, which indicated that their methodology was of high quality. Seven studies received the highest quality rating of 90%. Two studies scored 80%. The remaining article scored 70% (Files S2 and S3 available on figshare at: <https://10.6084/m9.figshare.21730970> accessed on 25 January 2023)).

3.4. Main Findings

The threads that emanated from the included articles were topical treatments, chemexfoliation, lasers and lights, and oral treatments. All of the included articles demonstrated at least one facet of PEO on melasma. The findings from all included studies are summarised in Table 4.

3.4.1. Topical Treatments

Azelaic acid (AZA) Cream

One study reported the efficacy of the topical application of 20% AZA cream as a monotherapy compared to sequential therapy with a steroid when treating melasma in Indian patients [59]. A study conducted to compare the efficacy of 20% azelaic acid cream monotherapy versus sequential therapy in the treatment of melasma in dark-skinned patients was conducted [59]. The overall response, which included clinical evaluation and photography, revealed melasma lightening. The improvement was significantly greater for those who received sequential therapy compared to those who received 20% AZA cream only. Although the difference remained significant at 24 weeks, as many as 96.7 and 90% of patients in each group had satisfactory to excellent treatment responses, respectively. Side effects were reported, though they were regarded as local irritant effects. Six patients reported itching and burning after using the 20% AZA cream, although this subsided with continued usage. In five cases, strong topical steroids were used, but the symptoms resolved once the steroids were stopped. As the side effects were only temporary, the patients were given AZA cream after eight weeks. It was not conclusive whether continuous treatment was required to manage melasma after the end of the study period.

Retinol/Tretinoin

The effects of topical retinoic acid (RA) on melasma in African Americans were studied in a randomised, vehicle-controlled clinical trial. The study trial was started with moderate to severe face hypermelanosis that was clinically compatible with melasma [62]. Follow-up evaluations were performed after 2 and 4 weeks of therapy, as well as at monthly intervals thereafter. The change in clinical appearance was compared to the baseline at each visit. The overall response showed improvement within the tretinoin treatment group compared to a 10% improvement in the vehicle group. Melasma lightened after 40 weeks of tretinoin treatment, according to colourimetric measurements. Histologic examination of the affected skin revealed that the tretinoin group had significantly less epidermal pigmentation than the vehicle group. The most common side effect was mild “retinoid dermatitis,” which occurred in 67% of the tretinoin-treated patients (Table 4).

3.4.2. Chemical Peels

Three studies investigated the application of various chemical peels to treat melasma. A comparative study assessed the effectiveness and tolerability of glycolic acid (GA), salicylic acid (SA), and mandelic acid (MA), as well as phytic combination peels [6]. In this study, participants were divided into three groups: group A used glycolic acid (35%), group B used SM acid (20% salicylic/10% mandelic acid), and group C used a phytic combination peel. It was evident from the results that both glycolic and SM acid peels were equally effective and safe treatment options for melasma in Indian skin, and they

were more effective than phytic acid peels [6]. Several undesirable side effects, including post-peel pigmentary changes, were reported as mild (Table 4).

The focal trichloroacetic acid (TCA) peel method presented an efficient modality for the treatment of melasma, without major complications [64]. Periocular melasma was treated with 10% to 20% TCA, while the rest of the facial melasma lesions received 30–50% TCA. Moreover, the choice of concentration was determined by the caustic chemical used, the concentration, the intensity of keratocoagulation, and the effectiveness of the peel modulated by the concentration and amount of each agent used, as well as the mode and number of applications, skin type, and dermatologic condition being treated. By pressing firmly with a sharpened wooden applicator, the TCA peel was applied to a focal pigmented area. The coagulation of the epidermal and dermal proteins was characterised by a frosted appearance and used as an indicator of the peel depth, marking the endpoint. TCA was applied selectively to each pigmented lesion, resulting in evenly frosted spots. Independent physicians who were double blind evaluated photographs taken before treatment and 6 months after the completion of treatment for independent clinical assessment. Six patients rated the results as exceptional (over 70% of the lesions disappeared), five patients indicated the results as good (50% to 70% of the lesions resolved completely), five obtained fair results (30% to 50% of the lesions disappeared), and four experienced poor results (less than 30% of the lesions disappeared). Although complications were regarded as insignificant, transient post-inflammatory hyperpigmentation occurred, which necessitated the use of 5% hydroquinone treatment (Table 4).

In one study, the therapeutic response of melasma in Indian women to GA (20–35%) versus TCA (10–20%) for chemical peeling was compared [60], and both men and women with epidermal melasma were enrolled in the study. The participants were split into two groups. GA (20–35%) was used in Group 1 and TCA (10–20%) was used in Group 2. Before the commencement of the study, both groups were enrolled in a pre-peel program that involved the daily application of 1% tretinoin at night before the peel procedure. The faces were divided into two sections: the right and left foreheads, the left and right cheeks, the nose and glabella, and the perioral area. A 20% glycolic acid peel and 10% TCA were applied for two minutes; the second peel, 20% GA/10%TCA, was applied for four minutes; the third peel application comprised 35% GA/20% TCA for two minutes; the fourth peel, 35% GA/20% TCA, was applied for four minutes. Both groups were treated the same, but the difference was the peel concentration, as group 1 was treated with GA (20–35%) and Group 2 with TCA (10–20%). All peels were applied every two weeks. The results of the study showed that the application of 20% GA cream at night for 2 weeks, followed by an increase in the GA and TCA concentrations of a facial peel for 2–4 min every two weeks for three months proved to be an equally effective treatment. There was no difference in the peels after six weeks; however, improvement in the TCA Group was noted after two weeks, compared with an improvement only after six weeks in the GA group. Side effects were well-treated (Table 4).

3.4.3. Lasers and Lights

Four studies evaluated the use of different lasers and lights as monotherapy or used with other therapies. One study assessed the efficacy of LED [15], another investigated the application of Q-switched neodymium-doped yttrium aluminium garnet (Nd-YAG) lasers combined with Kligman's triple combination [61], and the last two evaluated the safety and effectiveness of the picosecond alexandrite laser [63,65].

In a prospective trial, the picosecond alexandrite laser (755 nm), using a diffraction lens array and a flat optic, was utilised to treat refractory melasma [63]. All patients in this study had stopped all previous treatments/medications for at least one month before receiving treatment with the picosecond alexandrite laser. Participants were separated into two groups. Group 1 participants were treated with the picosecond alexandrite laser flat optic while group 2 participants were treated with the picosecond alexandrite laser with a diffractive lens array. After the study, patients showed a significant improvement with the

diffractive lens array compared with the flat optic lens. Both groups were dissatisfied as they experienced macular hypopigmentation (Table 4).

A split-face randomised controlled trial examined the safety and effectiveness of Q-switched neodymium-doped yttrium aluminium garnet laser (QSNYL) and topical creams (TCs) in treating melasma compared to the efficacy of 1064 nm Q-switched Nd-YAG laser and modified Kligman's formulation [61]. Both QSNYL and TC were studied as monotherapy for their efficacy. Seventeen patients (37.8%) had epidermal melasma, while the rest had dermal or mixed melasma types. Participants were randomised into two groups. Group A received QSNL treatment while group B was treated daily with TC. After the study period, four different outcome measures were used to assess treatment efficacy. The results revealed an overall improvement in both groups after 16 weeks. There were no statistically significant differences between low-fluence QSNYL and TC as monotherapy. The reappearance of melasma after stopping the therapy was one of the reported side effects experienced (Table 4).

Omnilux LED showed improvement in melasma in individuals with skin types V-VI [15]. Participants in this study were purposefully divided into two groups based on their skin tone. Both groups received two LED treatments for 12 weeks twice a week. After the study period, both groups showed improvement. Participants with skin type V rated their melasma to have improved more compared with that of skin type VI participants. In this study, there were no reported side effects; however, the study time was long, i.e., nine months, and people who suffer from melasma tend to be less patient (Table 4).

3.4.4. Tranexamic Acid

One study evaluated the effects of oral tranexamic acid (TXA) compared to intradermal microinjections of TXA when treating melasma [11]. In this comparative study, patients were randomly allocated to one of two groups (intradermal or oral), which comprised 50 participants [11]. The results of the study revealed that both treatment methods were equally effective. Some patients reported adverse effects, which necessitated treatment with oral ranitidine 150 mg twice daily, and some reported relapse (Table 4).

Table 4. Summary of included studies.

Treatment Intervention (Author, Year)	Study Design	Skin Types	Tx Period	Outcome (s)	Follow-Up Period	Side Effects	Recurrences
Group A: 250 mg oral TXA twice daily. Group B: TXA intradermal microinjections 4 mg/mL once every 4 weeks. Sharma et al. 2017 [11].	Randomised, comparative	IV	12 weeks	Reduction in MASI 4, 8, and 12 weeks was $21.29 \pm 17.24\%$, $53.32 \pm 16.50\%$, and $77.96 \pm 09.39\%$, respectively, in group A, and $18.27 \pm 15.34\%$, $51.32 \pm 17.20\%$, and $79.00 \pm 09.64\%$ in group B. Comparison between pre- and post-treatment clinical photographs showed overall improvement in both groups	24 weeks	Mild epigastric discomfort, hypomenorrhea, headache, and injection-site pain.	Two patients in group A had re-lapses at 24 weeks.
Group A: 35% GA, once every 2 weeks. Group B: 20% salicylic and 10% mandelic acid, once every 2 weeks. Group C: 50% phytic acid combination peel, once every 2 weeks. Sarkar et al. 2016 [6].	Prospective, randomised, single-blinded	IV–V	12 weeks	Reduction in MASI scoring after 12 weeks was 62.36% in GA group A, 60.98% in SM group B, and 44.71% in phytic acid group C.	20 weeks	Mild cutaneous persistent erythema, superficial desquamation, post-peel hyperpigmentation, burning sensation, herpes simplex.	N/A
Group A: 20% AZA cream, twice-daily application to one half of the face for 24 weeks. Group B: 0.05% clobetasol propionate cream, applied for 8 weeks only and then to be followed by 20% AZA cream only for the next 16 weeks on the other half of the face. Sarkar, 2002 [59].	Prospective, single-blind, right–left comparison pilot	IV–V	24 weeks	At 4, 8, and 16 weeks, the lightening of melasma was significantly more marked on the side receiving the sequential therapy rather than the side receiving only 20% AZA cream ($p < 0.001$). However, at 24 weeks, although the difference was still significant ($p = 0.0052$), as many as 96.7 and 90% of patients of each group (sequential therapy and AZA) had good to excellent responses to treatment	24 weeks	Atrophy, telangiectasia, burning, erythema itching, acneiform eruptions.	Three patients did not experience any changes.
Group A skin type V: twice-weekly LED 633 nm followed by an 830 nm treatment 2 days later. Group B skin type VI: twice-weekly LED 633 nm followed by an 830 nm treatment 2 days later. Mpofana and Abrahamse, 2018 [15].	Experimental	V–VI	12 weeks	Decreased MASI mean from 40.66% at baseline to 26.85%. Improved MHGS scores as shown by a p -value of 0.000 at a <0.05 level of significance. VISIA complexion analysis as well as histology images showed improvement of melasma. Response graded by patients as being “Excellent Response”	36 weeks	N/A	N/A

Table 4. Cont.

Treatment Intervention (Author, Year)	Study Design	Skin Types	Tx Period	Outcome (s)	Follow-Up Period	Side Effects	Recurrences
<p>Group A: two-week pre-peel program of daily application of 12% GA cream followed by 20–35% GA, then treated with graded concentrations of 20–35% GA.</p> <p>Group B: two-week pre-peel program of daily application of 0.1% tretinoin at night, followed by 10–20% TCA facial peel.</p> <p>Kumari and Thappa, 2010 [60].</p>	Comparative	IV–VI	12 weeks	Reduction in MASI scoring after 12 weeks was by 79% (from 26.6 to 5.6) in GA group A and by 73% in TCA group B (from a mean MASI of 29.1 to 8.2) but this difference was not significant. Subjective response, as graded by the patient, showed good or very good response in 75% in the GA group and 65% in the TCA group.		Moderate to severe burning, erythema, post-peel cracking.	N/A
<p>Group A: 0.1% tretinoin cream application of “pea-sized” amount of cream and slowly increase the amount used every night to increase tolerance.</p> <p>Group B: identical-appearing, colour-matched vehicle cream, application of “pea-sized” amount of cream and slowly increase the amount used every night to increase tolerance.</p> <p>Kimbrough-Green [62].</p>	Randomised vehicle-controlled clinical trial	V–VI	24 weeks	After 40 weeks, the average MASI score of the tretinoin-treated group decreased by 32%, from 15.0 ± 1.8 at baseline to 10.2 ± 2.0 , compared with a 10% decrease from 15.5 ± 2.4 to 13.9 ± 2.7 in the vehicle group. Colourimetric analysis revealed an increase in L^* in the tretinoin-treated group, from 45.5 ± 1.4 U at baseline to 48.7 ± 1.6 U at week 40, i.e., a lightening of 3.2 ± 0.9 U, compared with a change of 42.5 ± 1.6 to 42.8 ± 1.8 U in the vehicle-treated group, a lightening of 0.3 ± 0.9 U ($p = 0.02$). Histology produced an 8% decrease in epidermal pigmentation compared with a 55% increase with vehicle treatment ($p = 0.0007$). Dermal pigment decreased by 18% in the tretinoin-treated group and increased by 11% in the vehicle group. Significant increases in stratum corneum compaction and granular layer thickness were noted in the tretinoin vs the vehicle group after 40 weeks of treatment.	40 weeks	Erythema, peeling, retinoid dermatitis.	N/A

Table 4. Cont.

Treatment Intervention (Author, Year)	Study Design	Skin Types	Tx Period	Outcome (s)	Follow-Up Period	Side Effects	Recurrences
Group A: QSNYL once every week. Group B: daily application of modified Kligman's triple combination consisting of hydroquinone 4%, tretinoin 0.05%, and fluocinolone acetonide 0.01%. along with a broad-spectrum sunscreen. Dev, 2018 [61].	Split-face randomised controlled trial	IV–V	12 weeks	The mean baseline MI in groups A and B was 50.6 ± 5.9 and 49.9 ± 6.1 , respectively. That significantly decreased to 48.3 ± 5.9 ($p < 0.001$) and 47.8 ± 5.4 ($p < 0.01$), and the mean baseline mMASI in group A and group B was 3.3 ± 1.9 and 3.3 ± 2.0 , which decreased to 2.7 ± 1.5 ($p < 0.05$) and 2.3 ± 1.6 , respectively, ($p < 0.001$) after 12 weeks. Photographic assessment showed an overall significant improvement of 17.3% (95 CI%: 6.7–27.9) in group A and 20.9% (95% CI: 10.2–31.6%) in group B at the end of 12 weeks of intervention.	12 weeks	Group A developed acute urticaria, group B encountered erythema and telangiectasia.	All patients had a reappearance of pigmentation by the end of follow-up.
Group A: 10% to 50% TCA, low-potency topical corticosteroid (hydrocortisone lotion), antibiotic ointment. Group B: a focal TCA peel was performed every 4–8 weeks. Chun, 2004 [64].	Experimental	IV–V	12 weeks	Eleven of twenty (55%) patients with melasma experienced a good clinical response. Patient and physician satisfaction rates, recorded from interviews conducted 6 months after the last treatment, were absolutely and moderately satisfied with this therapy, respectively.	24 weeks	Mild erythema, transient post-inflammatory hyperpigmentation occurred in two patients.	N/A
Ps 755 nm alexandrite laser with DLA. The pulse duration was 750 ps. An 8-mm spot size and fluence of 0.4 J/cm ² was used over the target area with 2 passes per treatment area and around 2000–2500 passes in total. The repetition rate was 10 Hz. Treatments were performed in 4- to 6-week intervals. Chen, 2019 [65].	Prospective, pilot	IV	N/A	The mean MASI score of 20 patients was 9.4 ± 4.7 at baseline, which improved significantly to 6.9 ± 3.7 after 3 sessions of ps laser therapy ($p < 0.001$). The VISIA analysis showed improvement on the forehead, although only spots ($p = 0.007$) and porphyrins ($p = 0.032$) were markedly improved. In both malar regions, VISIA analysis showed significant improvement in UV spots ($p = 0.044$), brown spots ($p = 0.017$), and porphyrins ($p = 0.02$).	24 weeks	Erythema (25%), pruritus (20%), and scaling (20%). One patient (5%) developed mild PIH.	N/A

Table 4. Cont.

Treatment Intervention (Author, Year)	Study Design	Skin Types	Tx Period	Outcome (s)	Follow-Up Period	Side Effects	Recurrences
Group A: flat optic cases were treated with the ps alexandrite laser flat optic, 1.02 to 1.5 J/cm ² , 3 to 4 mm spot size x1 pass, treatments occurred every 2 weeks. Group B: ps alexandrite laser with DLA, 0.4 J/cm ² , 8 mm spot size (230 micro beams) with 1 pass, treatments occurred every 2 weeks. Polnikorn, 2020 [63].	Experimental	IV–VI	12 weeks	MSI score for Group 1 was 8.63, which improved to an average score of 3.16 at the 6-month follow-up. The MSI score was 2.4 pre-treatment, 6.8 after the first month, and 1.2 (50% improvement) at 6 months. There was an average improvement of 57.2% (636.1%) seen in the flat optic group, which was statistically significant ($p < 0.001$, 2-tailed paired t -test). Group 2 had an average baseline MSI score of 6.22, which improved to an average of 1.48 at the 6-month follow-up. Subjects treated with the DLA had an average improvement of 75.7% (647.1%), which was statistically significant ($p < 0.001$, 2-tailed paired t -test).	24 weeks	In Group 1, 3 cases (16%) developed darkening of melasma and macular hypopigmentation. Group 2, with DLA on the ps alexandrite laser, immediately after treatment, there was mild, transient erythema, and patients experienced a mild heating sensation.	At 6 months, there was a recurrence of melasma in 5% of the cases. Recurrence in 16% of the cases in the flat optic group and transient macular hyper-pigmentation in 21% of the cases.

TX: treatment; MASI: Melasma Area and Severity Index; N/A: not applicable; GA: glycolic acid, SM: salicylic–mandelic acid; TCA: trichloroacetic acid; AZA: azelaic acid; MHGS: Melasma Histology Grading Scale; LED: light-emitting diode; mMASI: modified Melasma Area and Severity Index; MSI: Melasma severity index; MI: Nd-YAG: neodymium-doped yttrium aluminium garnet; QSNYL: Q-switched Nd: YAG laser; DLA: diffractive lens array; Ps: picosecond; UV: ultraviolet; PIH: post-inflammatory hyperpigmentation; L*: a measure of skin pigmentation of an individual from the CIE L* a* b* system; *: multiplication sign; a* and b* are chromaticity co-ordinates.

4. Discussion

To map the evidence, we performed a scoping review of treatments used for melasma in darker skin types. In this review, all participants were adults aged between 18 and 67 years (Table 3). Many of the studies included both male and female participants [6,11,59,60,62,64], while four studies were conducted with only females [15,61,63,65]. The smallest sample size was 20 [64,65] and the largest was 100 [11]. The included studies were carried out on skin types IV–VI, and only four studies investigated skin type VI [15,60,62,63]. Reported treatment interventions included topical creams and solutions [59,61], chemical peels [6,60,64], picosecond alexandrite laser [63,65], Q-switched Nd-YAG laser [61], LEDs [15], and TXA via different routes [11] ($n = 1$). As part of their daily routine, all patients applied SPF on top of their daily moisturiser.

Melasma is a disfiguring skin condition that is more common in women with darker skin [15]. In one cross-sectional, multi-centric, clinico-epidemiological study of melasma in India [66], there was a strong correlation between family history and the prevalence of melasma, suggesting genetic predisposition [67]. Sun exposure is a major cause of melasma, so a broad-spectrum sunscreen with an SPF of 50 or higher was always recommended [1,5,15]. Other factors that may contribute to melasma include concurrent medication, chronic disease, multiple pregnancies, and the use of oral contraceptives [66].

4.1. Topical Treatments

Melasma is managed with TC cream as a first-line treatment. Kligman's formula contains 4% hydroquinone, 0.05% tretinoin, and 0.01% fluocinolone acetonide [68]. TC shows better results, as hydroquinone (HQ) prevents melanin production by inhibiting tyrosinase, whereas tretinoin has exfoliating properties that help enhance penetration. However, with this combination, it has been observed that it is easy to re-pigment due to the inflammation caused by tretinoin [69]. HQ 2–4% cream is often used; it has been reported to cause uneven depigmentation, contact dermatitis, post-inflammatory hyperpigmentation, temporary erythema, burning, and ochronosis [59,70].

Another commonly used TC is tretinoin. It is either used with other topical whitening creams as a penetration enhancer or alone. It reduces pigmentation by inhibiting tyrosinase induction as it disrupts pigment transfer and accelerates epidermal turnover [62,71]. The use of tretinoin has been proven to be effective; however, lightening takes more than 24 weeks, which is a lengthy period for patients, and thus inconvenient. Additionally, being a corticosteroid, it brings about undesirable side effects such as local irreversible thinning of the skin, scaling, dryness, burning, erythema, stinging, contact dermatitis, perioral dermatitis, or acne rosacea and hypertrichosis in some cases [62,70]. Although the side effects are reversible, retinoid dermatitis can cause hyperpigmentation, particularly in people with dark skin [62].

4.2. Chemical Peels

Superficial and medium-depth chemical peels, particularly glycolic acid, are effective in melasma but are not ideal for the treatment of melasma, especially when used alone [6,7,60]. There is a tendency for irritation, increased dryness, and photosensitivity. After chemical peels, darker skin types may experience pigmentation changes, including areas of hypopigmentation and hyperpigmentation [10,68]. TCA has long been used as a peeling agent in the treatment of several pigmented lesions, including melasma and photo-ageing. The use of higher TCA concentrations for deeper peels is associated with increased risks, primarily in dark-skinned patients whose skin tends to develop post-inflammatory hyperpigmentation [64].

4.3. Lasers and Lights

Although both ablative and non-ablative lasers can have a significant impact on melasma, the results are not always consistent, and complications have been reported. Adverse effects such as significant epidermal damage and peripheral hyperpigmentation,

rebound hyperpigmentation, mottled hypopigmentation, and petechiae have been recorded in varying degrees of frequency, more especially for those with darker skin tones [72,73].

4.4. Tranexamic Acid

TXA can be used safely and effectively to treat melasma in various forms such as oral, intradermal, or topical applications. Its safety profile has been thoroughly investigated [8,11,26,40,47]. However, because no controlled trial studies have been conducted in other ethnic groups, such as Africans, additional data collection and risk assessment are required for these groups [74].

4.5. Sun Protection

Sun exposure is completely prohibited when treating melasma. Daily sun exposure, which occurs with typical daily activities in sunny climates, has a detrimental effect on therapies for melasma [8,63]. In some countries, myths that darker skin types do not get sun damage still exist [15], and there is a need for education on the importance of sun protection in darker skin types.

4.5.1. Implication for Research and Practice

In this study, we found that there are a variety of treatment interventions to treat melasma. Despite the excessive availability of treatment, melasma remains a huge frustration both to the people suffering from it and the skin specialists managing it, as there is currently no cure. Melasma is not just a cosmetic concern, as it affects quality of life. Most research recorded on darker skin types has been predominantly conducted on Indian skin types. There is limited research for African or mixed-ancestry groups of people, so further inclusive research is necessary. We recommend primary studies and clinical trials investigating the use of medicinal plants to treat melasma. We also recommend that the psychological aspect should be considered when dealing with melasma.

4.5.2. Strengths and Limitations

One of the strengths of this scoping review is that there were no language limitations or time frames applied to the study, which allowed us to comprehensively cover the available peer-reviewed literature. Despite the exclusion of review articles and grey literature sources, the range of evidence was broad, as it included evidence from both qualitative and quantitative methodologies.

5. Conclusions

Melasma remains a huge medical burden. It is not only a cosmetic concern. Treating melasma is cumbersome since the therapy options typically include risks of pigmentary change, especially when dealing with darker skin types. Due to its high recurrence rate, many therapeutic techniques have been explored with minimal effectiveness but greater side effects. Chemical peels, tretinoin, tranexamic acid, lasers, and lights are all options for therapy. However, while providing brief minor relief, they have also been associated with a high rate of complications, including the worsening of melasma. Additionally, they are not appropriate for all people with darker skin. We have observed in this review that most studies have been conducted up to skin type V. We hope that this scoping review can bring further insight into the need for a suitable treatment for all skin types. There is a need for clinical trial inclusivity of all people with darker skin types, as the majority of research has been done on Indians. Exploring the effects of *Cassipourea flanaganii*, as it has demonstrated anti-tyrosinase effects in vitro, may be beneficial and may add to the melasma treatment armamentarium. *Cassipourea flanaganii* could make more targeted therapy available for all skin types in the future as there is a dire need for a novel relief that will be suitable for all skin types.

Supplementary Materials: The following supporting information can be downloaded at: [10.6084/m9.figshare.21730970](https://doi.org/10.6084/m9.figshare.21730970) (accessed on 27 January 2022): File S1: Table 3: Results from searched databases; File S2: MMAT quality appraisal reviewer 1; File S3: MMAT quality appraisal reviewer 2; and File S4: Preferred reporting items for systematic reviews and meta-analyses extensions for scoping reviews (PRISMA-ScR) checklist.

Author Contributions: Conceptualisation: N.M.; developed and conducted the search strategy: A.J.F. and N.M.; endnote software (Clarivate analytics, US): A.F; screening: N.M., T.V. and S.G.; statistical analysis: M.P., writing and preparation of the draft paper, N.M. and M.P; writing—review and editing, N.M.; B.C.; M.P.; A.J.F.; N.C.D.; N.G. and A.A.H.; supervision, N.C.D., A.A.H. and N.G. acquisition of funding; N.M. and N.G.; The manuscript has been read and approved by all authors. All authors have read and agreed to the published version of the manuscript.

Funding: This work is based on research supported in part by the National Research Foundation of South Africa (Grant Number: 138179), the HWSETA bursary, Durban University of Technology Seed Funding grant, and funding from UNICEF and with support from Future Africa, the University of Pretoria.

Institutional Review Board Statement: Not applicable.

Informed Consent Statement: Not applicable.

Data Availability Statement: Not applicable.

Acknowledgments: The authors would like to express gratitude to the DUT Somatology department for their technical and administrative assistance and to Ashona Singh, for editing this manuscript.

Conflicts of Interest: The authors declare no conflict of interest.

References

1. Vachiramon, V.; Iamsumang, W.; Chanasumon, N.; Thadanipon, K.; Triyangkulsri, K. A study of efficacy and safety of high-intensity focused ultrasound for the treatment of melasma in Asians: A single-blinded, randomized, split-face, pilot study. *J. Cosmet. Dermatol.* **2020**, *19*, 375–381. [[CrossRef](#)] [[PubMed](#)]
2. Gupta, M.; Mahajan, V.K. Clinical profile of 300 men with facial hypermelanosis. *J. Dermatol. Case Rep.* **2017**, *11*, 20–24. [[CrossRef](#)] [[PubMed](#)]
3. Wanitphakdeedecha, R.; Sy-Alvarado, F.; Patthamalai, P.; Techapichetvanich, T.; Eimpunth, S.; Manuskiatti, W. The efficacy in treatment of facial melasma with thulium 1927-nm fractional laser-assisted topical tranexamic acid delivery: A split-face, double-blind, randomized controlled pilot study. *Lasers Med. Sci.* **2020**, *35*, 2015–2021. [[CrossRef](#)] [[PubMed](#)]
4. Sarkar, R.; Ailawadi, P.; Garg, S. Melasma in men: A review of clinical, etiological, and management issues. *J. Clin. Aesthet. Dermatol.* **2018**, *11*, 53–59.
5. Minni, K.; Poojary, S. Efficacy and safety of oral tranexamic acid as an adjuvant in Indian patients with melasma: A prospective, interventional, single-centre, triple-blind, randomized, placebo-control, parallel group study. *J. Eur. Acad. Dermatol. Venereol.* **2020**, *34*, 2636–2644. [[CrossRef](#)]
6. Sarkar, R.; Garg, V.; Bansal, S.; Sethi, S.; Gupta, C. Comparative Evaluation of Efficacy and Tolerability of Glycolic Acid, Salicylic Mandelic Acid, and Phytic Acid Combination Peels in Melasma. *Dermatol. Surg.* **2016**, *42*, 384–391. [[CrossRef](#)]
7. Khunger, N.; Sarkar, R.; Jain, R.K. Tretinoin peels versus glycolic acid peels in the treatment of Melasma in dark-skinned patients. *Dermatol. Surg.* **2004**, *30*, 756–760. [[CrossRef](#)]
8. Saka, S.; Rao, G.R.R.; Komaram, R.B.; Kotha, S.; Tatavarthi, R.; Chitturi, L.P. Efficacy of 10% topical tranexamic acid in melasma—A randomized placebo-controlled split face study. *Int. J. Pharm. Sci. Res.* **2019**, *10*, 2583–2586. [[CrossRef](#)]
9. Dlova, N.C.; Akintilo, L.O.; Taylor, S.C. Prevalence of pigmentary disorders: A cross-sectional study in public hospitals in Durban, South Africa. *Int. J. Women's Dermatol.* **2019**, *5*, 345–348. [[CrossRef](#)]
10. Soliman, M.M.; Ramadan, S.A.; Bassiouny, D.A.; Abdelmalek, M. Combined trichloroacetic acid peel and topical ascorbic acid versus trichloroacetic acid peel alone in the treatment of melasma: A comparative study. *J. Cosmet. Dermatol.* **2007**, *6*, 89–94. [[CrossRef](#)]
11. Sharma, R.; Mahajan, V.K.; Mehta, K.S.; Chauhan, P.S.; Rawat, R.; Shiny, T.N. Therapeutic efficacy and safety of oral tranexamic acid and that of tranexamic acid local infiltration with microinjections in patients with melasma: A comparative study. *Clin. Exp. Dermatol.* **2017**, *42*, 728–734. [[CrossRef](#)] [[PubMed](#)]
12. Regazetti, C.; Sormani, L.; Debayle, D.; Bernerd, F.; Tulic, M.K.; De Donatis, G.M.; Chignon-Sicard, B.; Rocchi, S.; Passeron, T. Melanocytes Sense Blue Light and Regulate Pigmentation through Opsin-3. *J. Investig. Dermatol.* **2018**, *138*, 171–178. [[CrossRef](#)] [[PubMed](#)]

13. Mpfofana, N.; Chibi, B.; Gqaleni, N.; Mohammed, A.H.; Finlayson, A.J.; Kgarosi, K.; Dlova, N.C. The Prevalence and Treatment Options of Melasma as Well as its Association with Quality of Life in Darker Skin Types: A Scoping Review Protocol. *Res. Square* **2021**, preprint. [[CrossRef](#)]
14. Sarkar, R.; Kaur, C.; Bhalla, M.; Kanwar, A.J. The combination of glycolic acid peels with a topical regimen in the treatment of melasma in dark-skinned patients: A comparative study. *Dermatol. Surg.* **2002**, *28*, 828–832. [[CrossRef](#)] [[PubMed](#)]
15. Mpfofana, N.; Abrahamse, H. The Management of Melasma on Skin Types V and VI Using Light Emitting Diode Treatment. *Photomed. Laser Surg.* **2018**, *36*, 522–529. [[CrossRef](#)] [[PubMed](#)]
16. Mpfofana, N.; Abrahamse, H. Natural options for management of melasma, a review. *J. Cosmet. Laser Ther.* **2018**, *20*, 470–481. [[CrossRef](#)]
17. Kwon, S.H.; Na, J.I.; Choi, J.Y.; Park, K.C. Melasma: Updates and perspectives. *Exp. Dermatol.* **2019**, *28*, 704–708. [[CrossRef](#)] [[PubMed](#)]
18. Jiang, J.; Akinseye, O.; Tovar-Garza, A.; Pandya, A. The effect of melasma on self-esteem: A pilot study. *Int. J. Women's Dermatol.* **2018**, *4*, 38–42. [[CrossRef](#)] [[PubMed](#)]
19. Arora, P.; Meena, N.; Sharma, P.; Raihan, M. Impact of melasma on quality of life in Indian patients. *Pigment Int.* **2017**, *4*, 92. [[CrossRef](#)]
20. Uyanikoglu, H.; Aksoy, M. Quality of life in patients with melasma in Turkish women. *Dermatol. Rep.* **2017**, *9*, 7340. [[CrossRef](#)] [[PubMed](#)]
21. Pawaskar, M.D.; Parikh, P.; Markowski, T.; Mcmichael, A.J.; Feldman, S.R.; Balkrishnan, R. Melasma and its impact on health-related quality of life in Hispanic women. *J. Dermatol. Treat.* **2007**, *18*, 5–9. [[CrossRef](#)] [[PubMed](#)]
22. Zhu, Y.; Zeng, X.; Ying, J.; Cai, Y.; Qiu, Y.; Xiang, W. Evaluating the quality of life among melasma patients using the MELASQoL scale: A systematic review and meta-analysis. *PLoS ONE* **2022**, *17*, e0262833. [[CrossRef](#)] [[PubMed](#)]
23. Cestari, T.F.; Hessel, D.; Viegas, M.L.; Azulay, L. Validation of a melasma quality of life questionnaire for Brazilian Portuguese language: The MelasQoL-BP study and improvement of QoL of melasma patients after triple combination therapy. *Br. J. Dermatol.* **2006**, *156*, 13–20. [[CrossRef](#)]
24. Balkrishnan, R.; McMichael, A.; Camacho, F.; Saltzberg, F.; Housman, T.; Grummer, S.; Feldman, S.; Chren, M.M. Development and validation of a health-related quality of life instrument for women with melasma. *Br. J. Dermatol.* **2003**, *149*, 572–577. [[CrossRef](#)] [[PubMed](#)]
25. Ikino, J.K.; Nunes, D.H.; da Silva, V.P.M.; Fröde, T.S.; Sens, M.M. Melasma and assessment of the quality of life in Brazilian women. *An. Bras. Dermatol.* **2015**, *90*, 196–200. [[CrossRef](#)]
26. Rafi, S.; Iftikhar, U.; Rani, Z.; Hussain, I. Comparison of efficacy and safety of topical hydroquinone 2% and oral tranexamic acid 500 mg in patients of melasma. *J. Pak. Assoc. Dermatol.* **2017**, *27*, 204–213.
27. Elkamshoushi, A.M.; Romisy, D.; Omar, S.S. Oral tranexamic acid, hydroquinone 4% and low-fluence 1064 nm Q-switched Nd: YAG laser for mixed melasma: Clinical and dermoscopic evaluation. *J. Cosmet. Dermatol.* **2022**, *21*, 657–668. [[CrossRef](#)]
28. Ranjesh, M.; Azizifard, S.; Khosroshahi, N.G. Comparison of effects of 5% hydroquinone cream plus non-ablative fractional 1540 erbium YAG laser and 5% hydroquinone cream alone in the treatment of melasma. *Med. J. Tabriz Univ. Med. Sci.* **2021**, *43*, 29–34. [[CrossRef](#)]
29. Sarkar, R.; Arsiwala, S.; Dubey, N.; Sonthalia, S.; Das, A.; Arya, L.; Gokhale, N.; Torsekar, R.G.; Somani, V.K.; Majid, I.; et al. Chemical peels in melasma: A review with consensus recommendations by Indian pigmentary expert group. *Indian J. Dermatol.* **2017**, *62*, 578. [[CrossRef](#)]
30. Cheng, J.; Vashi, N.A. Chemical Peels in Ethnic Skin. In *Dermatoanthropology of Ethnic Skin and Hair*; Springer: Boston, MA, USA, 2017; pp. 437–448.
31. Ahsan, U.; Uzair, M.; Aamir, H. Comparison of safety and efficacy of 20% salicylic acid with Jessner's solution in chemical peeling for melasma in Asian skin. *Our Dermatol. Online* **2021**, *2*. [[CrossRef](#)]
32. Sahu, P.; Dayal, S. Most worthwhile superficial chemical peel for melasma of skin of color: Authors' experience of glycolic, trichloroacetic acid, and lactic peel. *Dermatol. Ther.* **2021**, *34*, e14693. [[CrossRef](#)] [[PubMed](#)]
33. Dunbar, S.; Posnick, D.; Bloom, B.; Elias, C.; Zito, P.; Goldberg, D.J. Energy-based device treatment of melasma: An update and review of the literature. *J. Cosmet. Laser Ther.* **2017**, *19*, 2–12. [[CrossRef](#)] [[PubMed](#)]
34. Kamal, T.; Iftikhar, U. Low-fluence Q-switched neodymium-doped yttrium aluminum garnet (1064nm) laser for the treatment of facial melasma in local population. *J. Pak. Assoc. Dermatol.* **2017**, *27*, 164–168.
35. Lee, M.-C.; Lin, Y.-F.; Hu, S.; Huang, Y.-L.; Chang, S.-L.; Cheng, C.-Y.; Chang, C.-S. A split-face study: Comparison of picosecond alexandrite laser and Q-switched Nd: YAG laser in the treatment of melasma in Asians. *Lasers Med. Sci.* **2018**, *33*, 1733–1738. [[CrossRef](#)]
36. Kaushik, S.B.; Alexis, A.F. Nonablative fractional laser resurfacing in skin of color: Evidence-based review. *J. Clin. Aesthet. Dermatol.* **2017**, *10*, 51–67. [[PubMed](#)]
37. Chalermchai, T.; Rummanethorn, P. Effects of a fractional picosecond 1,064 nm laser for the treatment of dermal and mixed type melasma. *J. Cosmet. Laser Ther.* **2018**, *20*, 134–139. [[CrossRef](#)]
38. Micek, I.; Pawlaczyk, M.; Kroma, A.; Seraszek-Jaros, A.; Urbańska, M.; Gornowicz-Porowska, J. Treatment of melasma with a low-fluence 1064 nm Q-switched Nd: YAG laser: Laser toning in Caucasian women. *Lasers Surg. Med.* **2022**, *54*, 366–373. [[CrossRef](#)]
39. Karrabi, M.; David, J.; Sahebkar, M. Clinical evaluation of efficacy, safety and tolerability of cysteamine 5% cream in comparison with modified Kligman's formula in subjects with epidermal melasma: A randomized, double-blind clinical trial study. *Skin Res. Technol.* **2021**, *27*, 24–31. [[CrossRef](#)]
40. Tahoun, A.I.; Mostafa, W.Z.; Amer, M.A. Dermoscopic evaluation of tranexamic acid versus Vitamin C, with microneedling in the treatment of melasma: A comparative, split-face, single-blinded study. *J. Dermatol. Treat.* **2021**, *33*, 1623–1629. [[CrossRef](#)]

41. Ahramiyanpour, N.; Saki, N.; Akbari, Z.; Shamsi-Meymandi, S.; Amiri, R.; Heiran, A. Efficacy of topical cysteamine hydrochloride in treating melasma: A systematic review. *J. Cosmet. Dermatol.* **2021**, *20*, 3593–3602. [[CrossRef](#)]
42. Cantelli, M.; Ferrillo, M.; Donnarumma, M.; Emanuele, E.; Fabbrocini, G. A new proprietary gel containing glabridin, andrographolide, and apolactoferrin improves the appearance of epidermal melasma in adult women: A 6-month pilot, uncontrolled open-label study. *J. Cosmet. Dermatol.* **2020**, *19*, 1395–1398. [[CrossRef](#)] [[PubMed](#)]
43. Rendon, M.I.; Barkovic, S. Clinical Evaluation of a 4% Hydroquinone + 1% Retinol Treatment Regimen for Improving Melasma and Photodamage in Fitzpatrick Skin Types III–VI. *J. Drugs Dermatol.* **2016**, *15*, 1435–1441. [[PubMed](#)]
44. Lueangarun, S.; Namboonlue, C.; Tempark, T. Postinflammatory and rebound hyperpigmentation as a complication after treatment efficacy of telangiectatic melasma with 585 nanometers Q-switched Nd: YAG laser and 4% hydroquinone cream in skin phototypes III–V. *J. Cosmet. Dermatol.* **2021**, *20*, 1700–1708. [[CrossRef](#)] [[PubMed](#)]
45. Feng, X.; Su, H.; Xie, J. Efficacy and safety of tranexamic acid in the treatment of adult melasma: An updated meta-analysis of randomized controlled trials. *J. Clin. Pharm. Ther.* **2021**, *46*, 1263–1273. [[CrossRef](#)] [[PubMed](#)]
46. Xing, M.; Wang, X.; Zhao, L.; Zhou, Z.; Liu, H.; Wang, B.; Cheng, A.; Zhang, S.; Gao, Y. Novel dissolving microneedles preparation for synergistic melasma therapy: Combined effects of tranexamic acid and licorice extract. *Int. J. Pharm.* **2021**, *600*, 120406. [[CrossRef](#)]
47. El Hadidi, H.; Mosaad, R.; Ragab, N. The efficacy of oral vs different dilutions of intradermal tranexamic acid microinjections in melasma—A randomized clinical trial. *Dermatol. Ther.* **2021**, *34*, e14924. [[CrossRef](#)]
48. Agamia, N.; Apalla, Z.; Salem, W.; Abdallah, W. A comparative study between oral tranexamic acid versus oral tranexamic acid and Q-switched Nd-YAG laser in melasma treatment: A clinical and dermoscopic evaluation. *J. Dermatol. Treat.* **2021**, *32*, 819–826. [[CrossRef](#)]
49. Thibane, V.; Ndhkala, A.; Abdelgadir, H.; Finnie, J.; van Staden, J. The cosmetic potential of plants from the Eastern Cape Province traditionally used for skincare and beauty. *S. Afr. J. Bot.* **2019**, *122*, 475–483. [[CrossRef](#)]
50. Langat, M.K.; Dlova, N.C.; Mulcahy-Ryan, L.E.; Schwikkard, S.L.; Opara, E.I.; Crouch, N.R.; Hiles, J.D.; Mulholland, D.A. The effect of isolates from *Cassipourea flanaganii* (Schinz) alston, a plant used as a skin lightning agent, on melanin production and tyrosinase inhibition. *J. Ethnopharmacol.* **2021**, *264*, 113272. [[CrossRef](#)]
51. Madikizela, L.M.; Nkwentsha, N.; Mlunguza, N.Y.; Mdluli, P.S. Physicochemical characterization and In vitro evaluation of the sun protection factor of cosmetic products made from natural clay material. *S. Afr. J. Chem.* **2017**, *70*, 113–119. [[CrossRef](#)]
52. Lima, P.; Dias, J.; Esposito, A.; Miot, L.; Miot, H. French maritime pine bark extract (pycnogenol) in association with triple combination cream for the treatment of facial melasma in women: A double-blind, randomized, placebo-controlled trial. *J. Eur. Acad. Dermatol. Venereol.* **2021**, *35*, 502–508. [[CrossRef](#)] [[PubMed](#)]
53. Arksey, H.; O'Malley, L. Scoping studies: Towards a methodological framework. *Int. J. Soc. Res. Methodol.* **2005**, *8*, 19–32. [[CrossRef](#)]
54. Peters, M.D.; Marnie, C.; Tricco, A.C.; Pollock, D.; Munn, Z.; Alexander, L.; McInerney, P.; Godfrey, C.M.; Khalil, H. Updated methodological guidance for the conduct of scoping reviews. *JBI Evid. Synth.* **2020**, *18*, 2119–2126. [[CrossRef](#)] [[PubMed](#)]
55. Tricco, A.C.; Lillie, E.; Zarin, W.; O'Brien, K.K.; Colquhoun, H.; Levac, D.; Moher, D.; Peters, M.D.J.; Horsley, T.; Weeks, L.; et al. PRISMA extension for scoping reviews (PRISMA-ScR): Checklist and explanation. *Ann. Int. Med.* **2018**, *169*, 467–473. [[CrossRef](#)] [[PubMed](#)]
56. Porta, M. *A Dictionary of Epidemiology*; Oxford University Press: Oxford, UK, 2014; ISBN 0199390045.
57. Hong, Q.; Pluye, P.; Fàbregues, S.; Bartlett, G.; Boardman, F.; Cargo, M. Mixed Methods Appraisal Tool (MMAT), Version 2018. Available online: <http://mixedmethodsappraisaltoolpublic.pbworks.com/w/page/127425845/Download%20the%20MMAT> (accessed on 21 October 2021).
58. Cohen, J. A coefficient of agreement for nominal scales. *Educ. Psychol. Meas.* **1960**, *20*, 37–46. [[CrossRef](#)]
59. Sarkar, R.; Bhalla, M.; Kanwar, A.J. A comparative study of 20% azelaic acid cream monotherapy versus a sequential therapy in the treatment of melasma in dark-skinned patients. *Dermatology* **2002**, *205*, 249–254. [[CrossRef](#)] [[PubMed](#)]
60. Kumari, R.; Thappa, D.M. Comparative study of trichloroacetic acid versus glycolic acid chemical peels in the treatment of melasma. *Indian J. Dermatol. Venereol. Leprol.* **2010**, *76*, 447. [[CrossRef](#)]
61. Dev, T.; Sreenivas, V.K.; Sharma, V.; Sahni, K.; Bhari, N.; Sethuraman, G. A split-face randomized controlled trial comparing 1064 nm Q-switched Nd-YAG laser and modified Kligman's formulation in darker skinned patients with melasma. *Br. J. Dermatol.* **2018**, *179*, 66. [[CrossRef](#)]
62. Kimbrough-Green, C.K.; Griffiths, C.E.; Finkel, L.J.; Hamilton, T.A.; Bulengo-Ransby, S.M.; Ellis, C.N.; Voorhees, J.J. Topical retinoic acid (tretinoin) for melasma in black patients. *A vehicle-controlled clinical trial. Arch. Dermatol.* **1994**, *130*, 727–733. [[CrossRef](#)]
63. Polnikorn, N.; Tanghetti, E. Treatment of refractory melasma in Asians with the picosecond alexandrite laser. *Dermatol. Surg.* **2020**, *46*, 1651–1656. [[CrossRef](#)]
64. Chun, E.Y.; Lee, J.B.; Lee, K.H. Focal trichloroacetic acid peel method for benign pigmented lesions in dark-skinned patients. *Dermatol. Surg.* **2004**, *30*, 512–516. [[CrossRef](#)] [[PubMed](#)]
65. Chen, Y.T.; Lin, E.T.; Chang, C.C.; Lin, B.S.; Chiang, H.M.; Huang, Y.H.; Lin, H.Y.; Wang, K.Y.; Chang, T.M. Efficacy and Safety Evaluation of Picosecond Alexandrite Laser with a Diffractive Lens Array for Treatment of Melasma in Asian Patients by VISIA Imaging System. *Photobiomodulation Photomed. Laser Surg.* **2019**, *37*, 559–566. [[CrossRef](#)] [[PubMed](#)]

66. KrupaShankar, D.S.R.; Somani, V.K.; Kohli, M.; Sharad, J.; Ganjoo, A.; Kandhari, S.; Mysore, V.R.; Aurangabadkar, S.; Malakar, S.; Vedamurthy, M.; et al. A Cross-Sectional, Multicentric Clinico-Epidemiological Study of Melasma in India. *Dermatol. Ther.* **2014**, *4*, 71–81. [[CrossRef](#)] [[PubMed](#)]
67. Abdel-Raouf Mohamed, H.; Ali Nasif, G.; Saad Abdel-Azim, E.; Abd El-Fatah Ahmed, M. Comparative study of fractional Erbium: YAG laser vs combined therapy with topical steroid as an adjuvant treatment in melasma. *J. Cosmet. Dermatol.* **2019**, *18*, 517–523. [[CrossRef](#)] [[PubMed](#)]
68. Mahajan, R.; Kanwar, A.J.; Parsad, D.; Kumaran, M.S.; Sharma, R. Glycolic acid peels/azelaic acid 20% cream combination and low potency triple combination lead to similar reduction in melasma severity in ethnic skin: Results of a randomized controlled study. *Indian J. Dermatol.* **2015**, *60*, 147–152. [[CrossRef](#)]
69. Nanda, S.; Grover, C.; Reddy, B.S. Efficacy of hydroquinone (2%) versus tretinoin (0.025%) as adjunct topical agents for chemical peeling in patients of melasma. *Dermatol. Surg.* **2004**, *30*, 385–388. [[CrossRef](#)]
70. Nordlund, J.; Grimes, P.; Ortonne, J.P. The safety of hydroquinone. *J. Eur. Acad. Dermatol. Venereol.* **2006**, *20*, 781–787. [[CrossRef](#)]
71. Bulengo-Ransby, S.M.; Griffiths, C.E.; Kimbrough-Green, C.K.; Finkel, L.J.; Hamilton, T.A.; Ellis, C.N.; Voorhees, J.J. Topical tretinoin (retinoic acid) therapy for hyperpigmented lesions caused by inflammation of the skin in black patients. *N. Engl. J. Med.* **1993**, *328*, 1438–1443. [[CrossRef](#)]
72. Choi, J.E.; Lee, D.W.; Seo, S.H.; Ahn, H.H.; Kye, Y.C. Low-fluence Q-switched Nd:YAG laser for the treatment of melasma in Asian patients. *J. Cosmet. Dermatol.* **2018**, *17*, 1053–1058. [[CrossRef](#)]
73. Garg, S.; Vashisht, K.R.; Makadia, S. A prospective randomized comparative study on 60 Indian patients of melasma, comparing pixel Q-switched NdYAG (1064 nm), super skin rejuvenation (540 nm) and ablative pixel erbium YAG (2940 nm) lasers, with a review of the literature. *J. Cosmet. Laser Ther.* **2019**, *21*, 297–307. [[CrossRef](#)]
74. Tse, T.W.; Hui, E. Tranexamic acid: An important adjuvant in the treatment of melasma. *J. Cosmet. Dermatol.* **2013**, *12*, 57–66. [[CrossRef](#)] [[PubMed](#)]

Disclaimer/Publisher’s Note: The statements, opinions and data contained in all publications are solely those of the individual author(s) and contributor(s) and not of MDPI and/or the editor(s). MDPI and/or the editor(s) disclaim responsibility for any injury to people or property resulting from any ideas, methods, instructions or products referred to in the content.