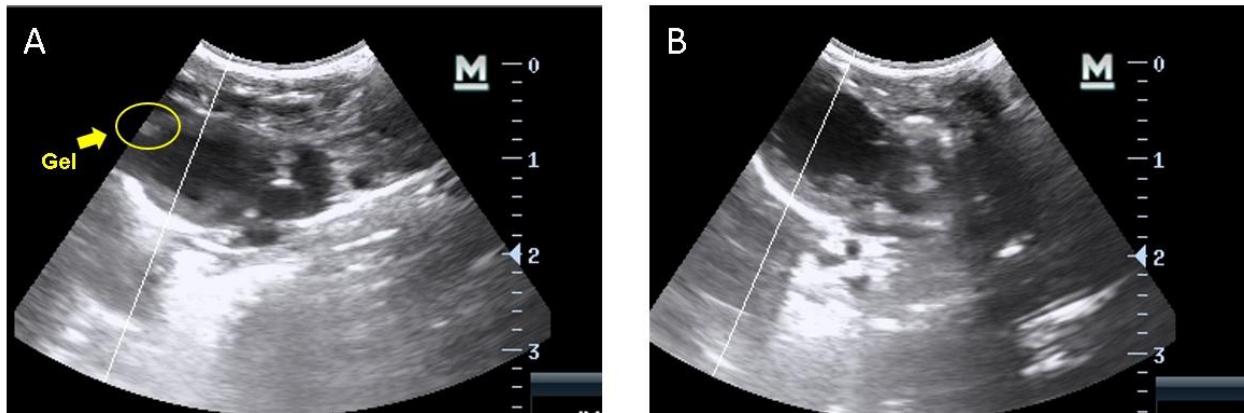


Supporting information



Supplementary Fig. 1. Based on echocardiography images, injected hydrogel was detectable at day 1 after myocardial infarction (A) while absent at day 28 (B).