






Review

# Oral Mucosal Lesions in Childhood

Lorena Horvat Aleksijević <sup>1,\*</sup> , Jelena Prpić <sup>2,3</sup>, Miranda Muhvić Urek <sup>2,3</sup>, Sonja Pezelj-Ribarić <sup>1,2,3</sup>,  
Nataša Ivančić-Jokić <sup>2,4</sup>, Romana Peršić Bukmir <sup>2,5</sup>, Marko Aleksijević <sup>1</sup>  and Irena Glazar <sup>2,3,\*</sup> 

<sup>1</sup> Faculty of Dental Medicine and Health, Josip Juraj Strossmayer University of Osijek, 31000 Osijek, Croatia

<sup>2</sup> Clinic of Dental Medicine, Clinical Hospital Center Rijeka, Krešimirova 42, 51000 Rijeka, Croatia

<sup>3</sup> Department of Oral Medicine, Faculty of Dental Medicine, University of Rijeka, Krešimirova 40, 51000 Rijeka, Croatia

<sup>4</sup> Department of Pediatric Dentistry, Faculty of Dental Medicine, University of Rijeka, Krešimirova 40, 51000 Rijeka, Croatia

<sup>5</sup> Department of Restorative Dentistry and Endodontics, Faculty of Dental Medicine, University of Rijeka, Krešimirova 40, 51000 Rijeka, Croatia

\* Correspondence: lorena.horvat@fdmz.hr (L.H.A.); irena.glazar@fdmri.uniri.hr (I.G.)

**Abstract:** Childhood diseases are a continuous source of interest in all areas of general and dental medicine. Congenital, developmental, and hereditary diseases may either be present upon birth or appear in early childhood. Developmental anomalies, although often asymptomatic, may become grounds for different infections. Furthermore, they can indicate certain systemic disorders. Childhood age frequently brings about benign tumors and different types of traumatic lesions to the oral mucosa. Traumatic lesions can be caused by chemical, mechanical, or thermal injury. Mucocele and ranula are, by definition, traumatic injuries of the salivary glands or their ducts. Recurrent aphthous lesions are the most common type of ulcerations in childhood, and their etiology is considered multifactorial. Oral mucosal lesions in children require different treatment approaches depending on etiological factors and clinical presentation. Clinicians should have adequate knowledge of oral anatomy in order to diagnose and treat pathological conditions.



**Citation:** Horvat Aleksijević, L.; Prpić, J.; Muhvić Urek, M.; Pezelj-Ribarić, S.; Ivančić-Jokić, N.; Peršić Bukmir, R.; Aleksijević, M.; Glazar, I. Oral Mucosal Lesions in Childhood. *Dent. J.* **2022**, *10*, 214. <https://doi.org/10.3390/dj10110214>

Academic Editor: Samir Nammour

Received: 25 October 2022

Accepted: 7 November 2022

Published: 9 November 2022

**Publisher's Note:** MDPI stays neutral with regard to jurisdictional claims in published maps and institutional affiliations.



**Copyright:** © 2022 by the authors. Licensee MDPI, Basel, Switzerland. This article is an open access article distributed under the terms and conditions of the Creative Commons Attribution (CC BY) license (<https://creativecommons.org/licenses/by/4.0/>).

**Keywords:** pediatric oral lesions; oral mucosa; children; hemangioma; lymphangioma; recurrent aphthous stomatitis

## 1. Introduction

A child's oral mucosa should be pink, smooth, moist, and shiny in its appearance. The dorsum of the tongue should have a velvety surface texture, and the lingual frenulum should be of adequate length to allow normal tongue movements. Oral mucosal lesions in children may appear as changes in color, size, or structure of the normal oral anatomy [1]. Changes in a child's mouth, besides causing parents' concern, can lead to pain and discomfort; however, they can also be completely asymptomatic [2]. Typical anatomical structures such as linea alba or leukoedema may also be a cause of panic for parents at the time they first see them in their child's mouth if they know nothing about their benign and asymptomatic character. This is where the knowledge and skills of the doctor of dental medicine become extremely important since they should be the ones to calm parents and explain the nature of these anatomical structures [1,3]. Congenital anomalies, such as ankyloglossia, may present a heavy challenge for the parents depending on its level since it can impede normal feeding from an early age or later on when it poses a great difficulty for the child due to the restrictions in normal speech [1,4]. Developmental anomalies should be detected as early as possible since, although asymptomatic, they may predispose the child to develop different complications such as infections or indicate the presence of certain syndromes such as Down syndrome, which is often coupled with a fissured tongue [2,5]. Many hereditary diseases show first symptoms in the oral cavity. Recognition of these oral symptoms can lead to an early diagnosis and therapy before the

disease spreads to other organ systems [1,6]. Benign tumors occur relatively often in the oral cavities of newborns and children. The most common is fibroma, a benign tumor of the connective tissue, followed by hemangioma and lymphangioma [1,2]. Traumatic lesions such as mucocele and ranula can be the underlying cause of swelling which will require surgical intervention [2,7]. Traumatic lesions can be classified according to the type of injury as thermal, mechanical, or chemical. Their treatment should be focused on enhancing the healing process in order to avoid complications such as infections, which would further aggravate the condition [1,8]. Recurrent aphthous lesions, which appear quite frequently in children, may impede the normal feeding process, swallowing, and speech [9]. The purpose of this review is to describe common soft tissue lesions of the oral cavity in children in order to help timely diagnosis and treatment; furthermore, we will also address some less frequent changes which may indicate the presence of systemic disorders which require a multidisciplinary approach.

## 2. Physiological Structures

Physiological structures are very common, benign and asymptomatic lesions of oral mucosa and do not require treatment but should not be mistakenly diagnosed as pathological lesions [10].

### 2.1. *Linea Alba*

This benign condition is typically localized on the buccal mucosa and stretches from the labial commissure towards the molar region [10]. It is clinically easily recognized as a white line of different intensity and thickness located at the level of occlusal surfaces [1,3,10]. It can be found either unilaterally or bilaterally [3]. Occasionally it may appear on the lateral borders of the tongue. It does not require treatment [1,10].

### 2.2. *Leukoedema*

Leukoedema is a common, benign, and asymptomatic lesion of the oral mucosa, which is considered a variation of the normal mucosal anatomy [3,10,11]. It appears as a whitish lesion located bilaterally or unilaterally on the buccal or labial mucosa [1,11]. It is of unknown etiology and is more frequently found in African Americans and among males [1,3,10]. Clinical presentation is of diffuse white creases or patches which disappear once the mucosa is stretched [10]. Since this lesion is benign and asymptomatic, it does not require treatment [1,10].

## 3. Congenital Anomalies

Congenital anomalies are usually benign anomalies which can affect a child's function or aesthetics. They should be monitored because of their impact on the quality of a child's life and properly diagnosed because of the possible malignant potential of nevi [1,2].

### 3.1. *Ankyloglossia*

Ankyloglossia is a congenital anomaly characterized by an abnormally short lingual frenulum which significantly limits tongue mobility [1,4,10,12–14]. A heart-shaped invagination at the tongue tip forms when tongue elevation is attempted [13,15]. In newborns, a short frenulum can follow the child's growth and cease to represent a functional difficulty when the child reaches a certain age [2]. Variability in the position and insertion level of the lingual frenulum has been observed; therefore, in order to reach the correct diagnosis, the determination of the functional disorder is of prime importance rather than anatomical variability [4,16]. If the child can lick his/her lower lip, it is considered that there are no functional disturbances and treatment is not indicated [2,12,16]. More severe types of ankyloglossia result in breastfeeding problems and impaired speech development later on [4,10,14–16]. In those cases, surgical therapy, frenectomy, is indicated, whereas, in cases of impaired phonatory function, treatment must also include the help of a logopedist [2,10,13,14].

### 3.2. Congenital Epulis

Congenital epulis is also known as the granular cell tumor [17–19]. It is a rare and benign lesion found in newborns and may often be found even before birth [17,18,20,21]. It is more common in girls [18,21], with typical localization on the alveolar ridge of the upper jaw, although it can also be found in the mandible [17,20]. Clinically it presents as a pedunculated nodule of the same color as the surrounding mucosa, elastic and smooth surfaced [19,21]. It usually measures approximately 10 mm in diameter, and it has been demonstrated that it does not follow the child's growth, but rather it remains of the same size; therefore, at follow-up, it appears smaller [21]. The treatment of choice is usually surgical, and diagnosis is confirmed through pathohistological analysis [18], which shows the proliferation of large eosinophilic polygonal cells with eccentric nuclei and granular cytoplasm [17,20,21].

### 3.3. Melanocytic Nevus

Melanocytic nevus is a pigmented mucosal lesion which is caused by the accumulation of pigment-producing cells called melanocytes [4,15,22]. It can be congenital or develop at any time during life [4,15,22,23]. Histological classification of nevi is crucial since it determines their prognosis (Table 1) [1]:

1. Junctional nevus: the proliferation of melanocytes in proximity to the network of blood vessels and nerves located superficially. It is usually limited to the epithelium [1,24].
2. Compound nevus: the proliferation of melanocytes in both epithelium and the underlying connective tissue [24].
3. Intradermal/intramucosal: melanin-producing cells that are located in lamina propria and are not in contact with the basal membrane. The lesions are typically dome-shaped, light brown, and located on the gums, lips, or buccal mucosa [1,24].
4. Blue nevus: the proliferation of elongated melanocytes deep within the lamina propria, far from the epithelium. This lesion is typically found on the hard palate [1,24,25]. They can be further classified into atypical blue nevus, locally aggressive blue nevus and congenital giant melanocytic nevus with nodular growth [1,25].
5. Other melanocytic nevi include combined nevus and Spitz nevus, with palate or tongue localization [1,26].
6. Congenital melanotic nevus: can be junctional, compound, intradermal, or intramucosal. They have their onset at birth, and they differ from common acquired nevi by their size and depth of involvement by nevus cells and adnexal and vascular involvement [1,27].

**Table 1.** Prognosis and treatment according to histological type of nevi.

Type of Nevi	Prognosis and Treatment	Reference
Junctional nevus	Good prognosis. No treatment needed. May be surgical, cryotherapy, or laser therapy.	[28]
Compound nevus	Good prognosis. Surgical excision is treatment.	[29]
Intramucosal nevus	Good prognosis. Surgical excision is treatment.	[30]
Blue nevus	Possible malignancy. Pathohistological diagnosis is necessary.	[31]
Spitz nevus	Good prognosis in children. The diagnosis of a Spitz nevus must be carefully distinguished from melanoma. Surgical excision is treatment.	[32]

The prevalence of oral nevi in children is unknown; however, solitary nevi are considered a relatively rare occurrence [1]. The most frequently observed nevi in the oral

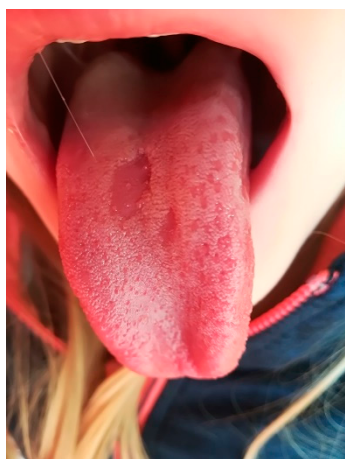
cavity are intramucosal and blue nevus, while compound nevus is the least common [33]. Melanocytic nevi present as localized brown, blue, grey, or black macules or papules of 0.1 to 3.0 cm in diameter [1,34]. They are asymptomatic and are usually found by accident upon clinical examination [33]. Nevi are commonly localized on the hard palate, buccal mucosa, and gums [1,34]. They are extremely rare in the retromolar area [33]. Diagnostic procedures include excisional biopsy with the exception of mucosal melanoma, especially if the lesion is localized on the palate [1,33,34]. At the same time, excisional biopsy also poses as the treatment [1,33].

#### 4. Developmental Anomalies

Developmental anomalies are relatively common in children [1,11]. Although their cause is unknown, they can be caused by hereditary factors or occur as a symptom in various syndromes [2,5,10].

##### 4.1. Geographic Tongue

Benign migratory glossitis, often called geographic tongue (Figure 1), appears in 1–3% of the population and is not uncommon in children [10,35,36]. The cause is unknown; however, it is assumed that a significant role is played by hereditary factors [1,10,36,37]. The disorder is also often related to various systemic and psychological conditions [36,38]. Geographic tongue is marked by erythematose, round or irregularly shaped patches on the dorsal and lateral portions of the tongue [2,11,36,38]. The sides of the tongue are slightly elevated, hyperkeratotic, and yellowish [2,10,36,37]. Lesions change their position on the tongue surface over time; therefore, they have been termed “migratory” [2,35,36]. Areas of desquamation are prone to secondary infections, so the inflamed areas may become quite painful, although this is rarely the case; typically, this condition is asymptomatic and resolves spontaneously [2,10,35]. In cases of pain or discomfort, the application of antiseptics, topical anesthetics, and/or corticosteroids can be indicated [10,35].



**Figure 1.** Geographic tongue.

##### 4.2. Fissured Tongue

Fissured tongue is a developmental anomaly which is typically presented as a solitary anteroposterior fissure (groove) right in the middle of the dorsal surface of the tongue [11]. It is not uncommon to find smaller and shallower furrows originating from the main fissure and spreading radially [2,10,11,35]. Although it represents a more frequent finding in adults, fissured tongue may appear in children in the form of an isolated developmental anomaly or coupled with other disorders such as Down syndrome and Melkersson–Rosenthal syndrome [2,5,10,11,35]. Melkersson–Rosenthal syndrome, although extremely rare in everyday clinical settings, is characterized by a triad of symptoms—oro-facial edema, hemifacial paralysis, and fissured tongue [5,39]. Fissured tongue is often related to complications in

the form of inflammation and secondary fungal infections as a consequence of food debris retention in deeper grooves [2,10,11,35,39].

#### 4.3. *Retrocuspid Papilla*

Retrocuspid papilla is one of the developmental anomalies that may be found in many children [11]. It is located on the attached gingiva on the lingual aspect of lower canines and typically occurs bilaterally [2,11]. This solid, fibro-epithelial pink to red papula [40], measuring 2 to 3 mm in diameter, is usually asymptomatic and has a tendency to decrease over time; therefore, it does not require treatment [2,40].

### 5. Hereditary Diseases

Hereditary diseases such as white sponge nevus, Peutz–Jeghers syndrome, or neurofibromatosis type 1 may present with oral symptoms that are important for establishing a final diagnosis and, accordingly, appropriate treatment [1,11,41–43].

#### 5.1. *White Sponge Nevus*

White sponge nevus is a benign asymptomatic lesion which is inherited as an autosomal dominant disorder [1,11,41,44–49]. Lesions are clinically presented as uni- or bilateral white patches of thick, sponge-like, or velvety tissue which are non-scrapable [1,11,44,46]. They are most commonly found on the buccal mucosa but may also be located on the tongue surface, labial mucosa, mouth floor, and gingiva [1,46,49,50]. Usually, they are already present at birth or in early childhood and occasionally may develop during adolescence [1,41,45,47,50,51]. Differential diagnosis includes leukoplakia, chemical burns, trauma, irritation caused by tobacco smoke, and candidosis [1,11,47,48,51]. Treatment is not required unless mastication is compromised [1,41,49].

#### 5.2. *Peutz–Jeghers Syndrome*

Peutz–Jeghers syndrome is an autosomal dominant disorder characterized by gastrointestinal polyposis and dark-colored spots on the skin and mucosa [1,11,42,52–55]. Hamartomatous polyps in the gastrointestinal tract can cause abdominal pain, chronic bleeding, anemia, and obstruction of the intestines [6,42,52–55], whereas 2 to 3% of the polyps show a tendency towards malignant transformation [1,6]. Polyps in the gastrointestinal tract may develop at any age, but pigmentations usually occur in early childhood [6,54,56]. Skin lesions are most commonly found around the eyes, on the fingers, and around the mouth, while intraorally, they are typically localized on the buccal mucosa and inner side of the lips [1,6,52,54–56]. Lesions are round or oval, 2–5 mm in diameter [1,6,25]. Their color varies from dark brown to black [6,25,56]. Lesions are asymptomatic, and the majority of intraoral ones fade before the first decade of life [52,54]. However, it is of major importance to diagnose the described changes in a timely manner and refer the patient to a gastroenterologist due to the possible progression of hamartomas towards malignancy [1,11,25,42,54,55].

#### 5.3. *Neurofibromatosis Type 1*

Neurofibromatosis type 1, also referred to as von Recklinghausen's disease, is an inherited autosomal dominant disorder characterized by the growth of multiple benign tumors along the nerves and on the skin, neurofibromas [11,43,57–59]. In cases when it is localized on the head and neck, it usually affects the skin; however, neurofibromas in the mouth are not uncommon [43,57,59–62]. There, it is typically present in the form of a submucosal, soft, discreet mass of smaller diameter, mostly on the alveolar process and palate [11,43,57,59–64]. Neurofibromatosis type 1 should be suspected in cases when the described changes are associated with multiple café-au-lait spots on the skin [11,43,57–59,62,64].



## 6. Benign Tumors

Benign tumors are relatively often in oral cavities of newborns and children. The most frequent is fibroma, a benign connective tissue tumor, followed by hemangioma and lymphangioma [1,2].

### 6.1. Fibroma

One of the most common benign lesions of the oral cavity, fibroma, results from connective tissue proliferation, which is brought about by chronic irritation [1,2]. Fibromas can appear anywhere on the oral mucosa; however, they are typically located on the palate, tongue, buccal mucosa, or lips [2,65–67]. Most fibromas are less than 1 cm in diameter, their color does not differ much from the surrounding mucosa, and the tissue feels smooth and hard [1,2,65]. They can be pedunculated or dome-shaped and firmly attached to the base [2,65]. Treatment includes surgical removal and elimination of the source of irritation. Relapses are rare [2].

### 6.2. Hemangioma

Hemangiomas are benign, fast-growing, vascular hamartomas which may appear anywhere on the soft tissues but most frequently develop on the buccal mucosa, dorsum of the tongue, gums, and lips [2,66,68–73]. They are relatively frequent in children [1,2,66,71,72,74]. As for their clinical presentation, they have typical red color if they are localized closer to the surface; however, those located more deeply appear blue [1,2,73,75]. They protrude upward from the surface and feel moderately hard upon palpation. Hemangiomas appear very early in life and are more common in girls [2,70,72,74]. As for growth, they develop fast and progressively follow the child's growth dynamic [71]. They are usually painless but can ulcerate or bleed due to trauma. Treatment is by laser or surgical resection [2,68,71–74]. Due to the vascular nature of the tumor, the danger of excessive bleeding must be taken into consideration [2,68,75].

### 6.3. Lymphangioma

Lymphangiomas are benign tumors of the lymphatic system, usually present at birth, although they may also develop during infancy [2,72,76,77]. Intraorally they are most commonly found on the tongue but may also be located on the lips and buccal mucosa [2,72,77]. Superficially located tumors are soft upon palpation, pink, or red/bluish, while more deeply localized lesions may remain invisible from the surface [2,72]. Cystic hygroma is a sac-like large lymphangioma which may involve the tissues of the mouth floor and neck [2]. Every lymphangioma that presents a functional or esthetic defect should be removed surgically [2,72,77]. Relapses are quite frequent and are usually caused by the lack of a cyst wall [2].

## 7. Traumatic Lesions

Mucocele and ranulas are one of the most common salivary gland disorders, and they are classified as extravasation pseudocysts [78].

### 7.1. Mucocele

Mucocele develops as a consequence of mechanical trauma to a minor salivary gland [2,7,65,78–83], which is followed by saliva retention and accumulation inside the blocked and dilated excretory ducts of the gland [2,7,65,78–81,83–85]. Lesions are usually painless, with smooth surfaces, bluish or transparent [2,7,65,72,78–80,82,83,85]. Most are not larger than 1 cm in diameter. They are treated by surgical removal; at that time, the surgeon often decides to perform the ablation of the neighboring minor salivary glands in order to prevent relapses [2,7,72,80,81,83].

### 7.2. *Ranula*

Ranula shows many clinical similarities with mucocele. It is caused by trauma to the excretory duct of the salivary glands located in the floor of the mouth and is manifested as swelling [7,72,78,84,86]. It is very uncommon in newborns [7].

### 8. Injury to the Oral Mucosa

An injury to the oral mucosa can result from physical, chemical, or thermal trauma. Thermal injuries are typically located on the anterior edge of the palate due to the consumption of hot foods [2]. Mechanic damage is caused by conscious or unconscious self-induced trauma. The most common example of self-induced physical trauma is morsicatio [10]. Morsicatio is a condition caused by chewing or rubbing of the mucosa brought about by stress or psychological disorders. Lesions are most frequently found on the lips, buccal mucosa, and tongue [8,10]. Clinically they present as white to grayish patches with a smooth or rough surface and irregular borders [1,8]. Treatment is not required, save for the elimination of the compulsive habit [1,10].

### 9. Recurrent Aphthous Lesions

Recurrent aphthous lesions (or ulcerations) are the most frequent kind of ulcerations observed in children [15,87,88]. They appear on the oral mucosa in the form of smaller or larger, single or multiple painful ulcerations that recur in intervals [9,89]. Many factors are involved in the etiology, including immune system disorders, genetic factors, hormonal disbalance, chemical, microbial or physical irritation, allergic factors, and stress [9,87–94]. Clinical presentation includes the formation of round or ovoid lesions with well-defined margins, a necrotic center covered by a yellow–gray pseudomembrane, and an erythematous halo which is the sign of peripheral inflammation [9,87–89,92,95]. Considering the size, number, and duration of the lesion(s), three types of aphthous ulcerations may be differentiated:

1. Minor aphthae: lesions are typically less than 1 cm in diameter; they heal without scarring within 10 days (Figure 2).
2. Major aphthous ulcerations: more than 1 cm in diameter, they can last for up to 30 days and may leave scars.
3. Herpetiform aphthous ulcerations: multiple lesions, up to 3 mm in diameter; ulcerations may merge. Healing takes approximately 15 days [15,87,88,90–93,96,97].

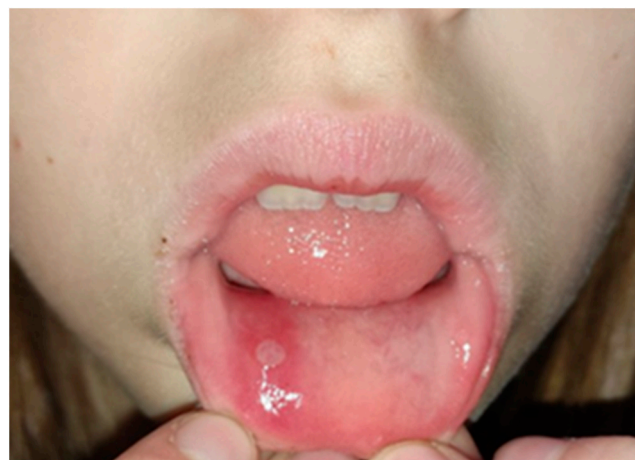

Figure 2. Aphtae minor.

Differential diagnosis is aimed at differentiation between aphtae and herpetic gingivostomatitis, herpangina, and ulcerations caused by injury [9]. Treatment is usually symptomatic and implies the use of topical anesthetics for pain control, antiseptic mouthwashes

to prevent secondary infections, and products that promote re-epithelialization [9,92,96]. Topical corticosteroids may also be applied; however, only in older children [9,88,89,91–93].

## 10. COVID-19 Infection

Given that COVID-19 is a relatively new infection, the prevalence of oral lesions in COVID-19 infection, especially in children, is not known. The most frequently recorded oral lesions are blisters, ulcerations, and desquamating gingivitis. Ulcerations usually affect the dorsum of the tongue [98]. The presence of white plaques on the tongue that did not respond to local therapy and geographic tongue was also noted. Fungal infections, *Herpes simplex*, and *Herpes zoster* virus infections occurred as a result of stress and decreased immunity during the COVID-19 infection [98,99]. The Kawasaki-like symptoms, which include erythema, dryness, cracking, and bleeding of the oral mucosa, have been described as the most severe oral symptom [98].

## 11. Conclusions

Searching through the literature provides insight into the need for the thorough knowledge that doctors of dental medicine should have on the anatomy and pathology of the oral tissues. They should be able to recognize benign, asymptomatic, and typical anatomical structures and differentiate them from pathological conditions. Congenital and developmental anomalies, although often benign and asymptomatic, may cause difficulties in normal function, may be combined with different complications, or point to certain systemic disorders. Hereditary diseases often show intraoral symptoms before manifesting in other organ systems, which makes early diagnosis even more important and rather crucial. Benign tumors of the oral cavity usually require simple surgical intervention, just like complications of traumatic lesions, while other lesions caused by injury disappear spontaneously upon removal of the cause.

**Author Contributions:** Conceptualization, I.G., L.H.A. and S.P.-R.; methodology, L.H.A. and N.I.-J.; software, M.A.; validation, M.M.U. and R.P.B.; formal analysis, I.G.; investigation, L.H.A.; resources, R.P.B.; data curation, L.H.A. and I.G.; writing—original draft preparation, L.H.A., M.A. and M.M.U.; writing—review and editing, I.G. and J.P.; visualization, S.P.-R.; supervision, I.G. All authors have read and agreed to the published version of the manuscript.

**Funding:** This research received no external funding.

**Institutional Review Board Statement:** The study was conducted according to the guidelines of the Declaration of Helsinki, and approved by the Ethics Committee of the Clinical Hospital Center Rijeka, Croatia and Faculty of Dental Medicine in Rijeka, Croatia.

**Informed Consent Statement:** Pictures were taken at the Clinic of Dental Medicine, Clinical Hospital Center Rijeka. Written informed consent was obtained from the patient's legal guardians to publish this paper.

**Data Availability Statement:** Not applicable.

**Conflicts of Interest:** The authors declare no conflict of interest.

## References

1. Pinto, A.; Haberland, C.M.; Baker, S. Pediatric Soft Tissue Oral Lesions. *Dent. Clin. N. Am.* **2014**, *58*, 437–453. [[CrossRef](#)] [[PubMed](#)]
2. Delaney, J.E.; Keels, M.A. Pediatric Oral Pathology: Soft Tissue and Periodontal Conditions. *Pediatr. Clin. N. Am.* **2000**, *47*, 1125–1147. [[CrossRef](#)]
3. Müller, S. Frictional Keratosis, Contact Keratosis and Smokeless Tobacco Keratosis: Features of Reactive White Lesions of the Oral Mucosa. *Head Neck Pathol.* **2019**, *13*, 16–24. [[CrossRef](#)] [[PubMed](#)]
4. Mills, N.; Pransky, S.M.; Geddes, D.T.; Mirjalili, S.A. What Is a Tongue Tie? Defining the Anatomy of the in-Situ Lingual Frenulum. *Clin. Anat.* **2019**, *32*, 749–761. [[CrossRef](#)] [[PubMed](#)]
5. Savasta, S.; Rossi, A.; Foadelli, T.; Licari, A.; Perini, A.M.E.; Farello, G.; Verrotti, A.; Marseglia, G.L. Melkersson–Rosenthal Syndrome in Childhood: Report of Three Paediatric Cases and a Review of the Literature. *Int. J. Environ. Res. Public Health* **2019**, *16*, 1289. [[CrossRef](#)] [[PubMed](#)]



6. Nevozinskaya, Z.; Korsunskaya, I.; Sakaniya, L.; Perlamutrov, Y.; Sobolev, V. Peutz–Jeghers Syndrome in Dermatology. *Acta Dermatovenerol. Alp. Pannonica Adriat* **2019**, *28*, 135–137. [[CrossRef](#)]
7. Patil, S.; Rao, R.S.; Majumdar, B.; Jafer, M.; Maralingannavar, M.; Sukumaran, A. Oral Lesions in Neonates. *Int. J. Clin. Pediatr. Dent.* **2016**, *9*, 131–138. [[CrossRef](#)]
8. Kang, H.S.; Lee, H.E.; Ro, Y.S.; Lee, C.W. Three Cases of Morsicatio Labiorum. *Ann. Dermatol.* **2012**, *24*, 455–458. [[CrossRef](#)]
9. Bardellini, E.; Veneri, F.; Amadori, F.; Conti, G.; Majorana, A. Photobiomodulation Therapy for the Management of Recurrent Aphthous Stomatitis in Children: Clinical Effectiveness and Parental Satisfaction. *Med. Oral Patol. Oral y Cir. Bucal* **2020**, *25*, e549–e553. [[CrossRef](#)]
10. Madani, F.M.; Kuperstein, A.S. Normal Variations of Oral Anatomy and Common Oral Soft Tissue Lesions: Evaluation and Management. *Med. Clin. N. Am.* **2014**, *98*, 1281–1298. [[CrossRef](#)]
11. Pinna, R.; Cocco, F.; Campus, G.; Conti, G.; Milia, E.; Sardella, A.; Cagetti, M.G. Genetic and Developmental Disorders of the Oral Mucosa: Epidemiology; Molecular Mechanisms; Diagnostic Criteria; Management. *Periodontology 2000* **2019**, *80*, 12–27. [[CrossRef](#)] [[PubMed](#)]
12. Pompéia, L.E.; Ilinsky, R.S.; Ortolani, C.L.F.; Faltin, J.K. Ankyloglossia and Its Influence on Growth and Development of the Stomatognathic System. *Rev. Paul Pediatr.* **2017**, *35*, 216–221. [[CrossRef](#)]
13. Walsh, J.; Tunkel, D. Diagnosis and Treatment of Ankyloglossia in Newborns and Infants: A Review. *JAMA Otolaryngol. Head Neck Surg.* **2017**, *143*, 1032–1039. [[CrossRef](#)] [[PubMed](#)]
14. Solis-Pazmino, P.; Kim, G.S.; Lincango-Naranjo, E.; Prokop, L.; Ponce, O.J.; Truong, M.T. Major Complications after Tongue-Tie Release: A Case Report and Systematic Review. *Int. J. Pediatr. Otorhinolaryngol.* **2020**, *138*, 110356. [[CrossRef](#)]
15. Ingram, J.; Copeland, M.; Johnson, D.; Emond, A. The Development and Evaluation of a Picture Tongue Assessment Tool for Tongue-Tie in Breastfed Babies (TABBY). *Int. Breastfeed. J.* **2019**, *14*, 31. [[CrossRef](#)] [[PubMed](#)]
16. Messner, A.H.; Walsh, J.; Rosenfeld, R.M.; Schwartz, S.R.; Ishman, S.L.; Baldassari, C.; Brietzke, S.E.; Darrow, D.H.; Goldstein, N.; Levi, J.; et al. Clinical Consensus Statement: Ankyloglossia in Children. *Otolaryngol. Head Neck Surg. USA* **2020**, *162*, 597–611. [[CrossRef](#)]
17. Gessesse, M. Congenital Epulis. *Ethiop. Med. J.* **2007**, *45*, 395–397.
18. Conrad, R.; Perez, M.C.N. Congenital Granular Cell Epulis. *Arch. Pathol. Lab. Med.* **2014**, *138*, 128–131. [[CrossRef](#)]
19. Aparna, H.G.; Jayanth, B.S.; Shashidara, R.; Jaishankar, P. Congenital Epulis in a Newborn: A Case Report, Immunoprofiling and Review of Literature. *Ethiop. J. Health Sci.* **2014**, *24*, 359–362. [[CrossRef](#)]
20. Mizutani, K.; Mukai, M.; Nagatsuka, H.; Yamada, S. Whitish-Yellow Tumor on Its Characteristic Cut Surface: A Case Report of Congenital Granular Cell Epulis. *Clin. Pathol.* **2019**, *12*, 1–2. [[CrossRef](#)]
21. Kokubun, K.; Matsuzaka, K.; Akashi, Y.; Sumi, M.; Nakajima, K.; Murakami, S.; Narita, M.; Shibahara, T.; Inoue, T. Congenital Epulis: A Case and Review of the Literature. *Bull. Tokyo Dent. Coll.* **2018**, *59*, 127–132. [[CrossRef](#)]
22. Kinsler, V.A.; O'Hare, P.; Bulstrode, N.; Calonje, J.E.; Chong, W.K.; Hargrave, D.; Jacques, T.; Lomas, D.; Sebire, N.J.; Slater, O. Melanoma in Congenital Melanocytic Naevi. *Br. J. Dermatol.* **2017**, *176*, 1131–1143. [[CrossRef](#)]
23. Levy, R.; Lara-Corrales, I. Melanocytic Nevi in Children: A Review. *Pediatr. Ann.* **2016**, *45*, e293–e298. [[CrossRef](#)]
24. Müller, S. Melanin-Associated Pigmented Lesions of the Oral Mucosa: Presentation, Differential Diagnosis, and Treatment. *Dermatol. Ther.* **2010**, *23*, 220–229. [[CrossRef](#)]
25. Gondak, R.O.; da Silva-Jorge, R.; Jorge, J.; Lopes, M.A.; Vargas, P.A. Oral Pigmented Lesions: Clinicopathologic Features and Review of the Literature. *Med. Oral Patol. Oral Cir. Bucal* **2012**, *17*, e919–e924. [[CrossRef](#)]
26. Li, C.C.; Harrist, T.J.; Noonan, V.L.; Woo, S. Bin Intraoral Spitz Nevus: Case Report and Literature Review. *Oral Surg. Oral Med. Oral Pathol. Oral Radiol.* **2014**, *117*, 320–324. [[CrossRef](#)]
27. Zayour, M.; Lazova, R. Congenital Melanocytic Nevi. *Clin. Lab. Med.* **2011**, *31*, 267–280. [[CrossRef](#)]
28. Köse, O. Carbon Dioxide Ablative Laser Treatment of Acquired Junctional Melanocytic Nevi. *J. Cosmet. Dermatol.* **2021**, *20*, 491–496. [[CrossRef](#)]
29. García de Oteyza, G.; Betancourt, J.; Benedetti Sandner, M.; Vázquez-Romo, K.A.; Hernández-Ayuso, I.; Ramos-Betancourt, N. Inflammatory Juvenile Compound Nevi: A Melanoma Is Not All That It Appears to Be. *Arch. Soc. Esp. Ophthalmol.* **2019**, *94*, 90–94. [[CrossRef](#)]
30. Devildos, L.R.; Langlois, C.C. Intramucosal Cellular Nevi. *Oral Surg. Oral Med. Oral Pathol.* **1981**, *52*, 162–166. [[CrossRef](#)]
31. Borgenvik, T.L.; Karlsvik, T.M.; Ray, S.; Fawzy, M.; James, N. Blue Nevus-like and Blue Nevus-Associated Melanoma: A Comprehensive Review of the Literature. *ANZ J. Surg.* **2017**, *87*, 345–349. [[CrossRef](#)] [[PubMed](#)]
32. Brown, A.; Sawyer, J.D.; Neumeister, M.W. Spitz Nevus: Review and Update. *Clin. Plast. Surg.* **2021**, *48*, 677–686. [[CrossRef](#)] [[PubMed](#)]
33. Gombra, V.; Kaur, M.; Sircar, K.; Popli, D.B. Pigmented Oral Compound Nevus of Retromolar Area—A Rare Case Report. *Singapore Dent. J.* **2016**, *37*, 33–35. [[CrossRef](#)] [[PubMed](#)]
34. Lambertini, M.; Patrizi, A.; Fanti, P.A.; Melotti, B.; Caliceti, U.; Magnoni, C.; Misciali, C.; Baraldi, C.; Ravaioli, G.M.; Dika, E. Oral Melanoma and Other Pigmentations: When to Biopsy? *J. Eur. Acad. Dermatology Venereol.* **2018**, *32*, 209–214. [[CrossRef](#)] [[PubMed](#)]
35. Mangold, A.R.; Torgerson, R.R.; Rogers, R.S. Diseases of the Tongue. *Clin. Dermatol.* **2016**, *34*, 458–469. [[CrossRef](#)]
36. Nandini, D.B.; Bhavana, S.B.; Deepak, B.S.; Ashwini, R. Paediatric Geographic Tongue: A Case Report, Review and Recent Updates. *J. Clin. Diagnostic Res.* **2016**, *10*, ZE05–ZE09. [[CrossRef](#)]

37. Picciani, B.; Teixeira-Souza, T.; Santos, V.C.; Gonzaga, H.; Cardoso-Oliveira, J.; Gripp, A.; Dias, E.; Carneiro, S. Geographic Tongue and Psoriasis: Clinical, Histopathological, Immunohistochemical and Genetic Correlation. *Contin. Med. Educ.* **2016**, *91*, 410–421.
38. González-Álvarez, L.; García-Pola, M.J.; Garcia-Martin, J.M. Geographic Tongue: Predisposing Factors, Diagnosis and Treatment. A Systematic Review. *Rev. Clin. Esp.* **2018**, *218*, 481–488. [[CrossRef](#)]
39. Dhawan, S.R.; Saini, A.G.; Singhi, P.D. Management Strategies of Melkersson-Rosenthal Syndrome: A Review. *Int. J. Gen. Med.* **2020**, *13*, 61–65. [[CrossRef](#)]
40. Mainville, G.N. Non-HPV Papillary Lesions of the Oral Mucosa: Clinical and Histopathologic Features of Reactive and Neoplastic Conditions. *Head Neck Pathol.* **2019**, *13*, 71–79. [[CrossRef](#)]
41. Benoit, S.; Schlipf, N.; Hausser, I.; Fischer, J.; Hamm, H. White Sponge Nevus—A Rare Autosomal Dominant Keratinopathy. *Klin. Padiatr.* **2014**, *226*, 375–376. [[CrossRef](#)]
42. Burgmeier, C.; Schier, F.; Staatz, G. Gastric Outlet Obstruction in a Neonate Because of Peutz-Jeghers Syndrome. *J. Pediatr. Surg.* **2012**, *47*, e1. [[CrossRef](#)]
43. Cunha, K.S.; Rozza-de-Menezes, R.E.; Andrade, R.M.; Almeida, L.; Janini, M.; Geller, M. Oral Manifestations of Neurofibromatosis Type 1 in Children with Facial Plexiform Neurofibroma: Report of Three Cases. *J. Clin. Pediatr. Dent.* **2015**, *39*, 168–171. [[CrossRef](#)]
44. Bezerra, K.T.; Leite, T.C.; Roza, A.L.O.C.; Araújo, R.; Israel, M.S.; Canedo, N.H.S.; Agostini, M.; Benevenuto de Andrade, B.A.; Romañach, M.J. White Sponge Nevus: A Condition Not Always Clinically Suspected. *J. Cutan. Pathol.* **2020**, *47*, 22–26. [[CrossRef](#)]
45. Sobhan, M.; Alirezaei, P.; Farshchian, M.; Eshghi, G.; Basir, H.R.G.; Khezrian, L. White Sponge Nevus: Report of a Case and Review of the Literature. *Acta Med. Iran.* **2017**, *55*, 533–535.
46. Cai, W.; Jiang, B.; Yu, F.; Yang, J.; Chen, Z.; Liu, J.; Wei, R.; Zhao, S.; Wang, X.; Liu, S. Current Approaches to the Diagnosis and Treatment of White Sponge Nevus. *Expert Rev. Mol. Med.* **2015**, *17*, e9. [[CrossRef](#)]
47. Songu, M.; Adibelli, H.; Diniz, G. White Sponge Nevus: Clinical Suspicion and Diagnosis. *Pediatr. Dermatol.* **2012**, *29*, 495–497. [[CrossRef](#)]
48. Schwartz, Z.; Magro, C.; Nuovo, G. The Molecular-Based Differentiation of Heck’s Disease from Its Mimics Including Oral Condyloma and White Sponge Nevus. *Ann. Diagn. Pathol.* **2019**, *43*, 151402. [[CrossRef](#)]
49. Bukhari, A.F.; Farag, A.M.; Treister, N.S. Chronic Oral Lesions. *Dermatol. Clin.* **2020**, *38*, 451–466. [[CrossRef](#)]
50. Elfatoiki, F.Z.; Capatas, S.; Skali, H.D.; Hali, F.; Attar, H.; Chiheb, S. Oral White Sponge Nevus: An Exceptional Differential Diagnosis in Childhood. *Case Rep. Dermatol. Med.* **2020**, *2020*, 4–6. [[CrossRef](#)]
51. Yamashita, K.; Samejima, M.; Oikawa, K.; Mizuno, K.; Ando, Y. White Sponge Nevus in a Three-Year-Old Boy: A Case Report. *Pediatr. Int.* **2020**, *62*, 882–883. [[CrossRef](#)] [[PubMed](#)]
52. Zhang, L.J.; Su, Z.; Liu, X.; Wang, L.; Zhang, Q. Peutz-Jeghers Syndrome with Early Onset of Pre-Adolescent Gynecomastia: A Predigree Case Report and Clinical and Molecular Genetic Analysis. *Am. J. Transl. Res.* **2017**, *9*, 2639–2644. [[PubMed](#)]
53. Duan, S.X.; Wang, G.H.; Zhong, J.; Ou, W.H.; Fu, M.X.; Wang, F.S.; Ma, S.H.; Li, J.H. Peutz-Jeghers Syndrome with Intermittent Upper Intestinal Obstruction. *Medicine* **2017**, *96*, e6538. [[CrossRef](#)] [[PubMed](#)]
54. Ma, C.O.; Melit, L.E. Early Onset Peutz—Jeghers Syndrome, the Importance of Appropriate Diagnosis and Follow-Up. *Medicine USA* **2019**, *98*, e16381.
55. Zhao, Z.Y.; Jiang, Y.L.; Li, B.R.; Li, J.; Jin, X.W.; Yu, E.D.; Ning, S. Bin Close and Regular Surveillance Is Key to Prevent Severe Complications for Peutz-Jeghers Syndrome Patients without Gastrointestinal Polyyps: Case Report of a Novel STK11 Mutation (c.471–472delCT) in a Chinese Girl. *BMC Surg.* **2018**, *18*, 24. [[CrossRef](#)]
56. Ferreira, L.d.S.; Calderipe, C.B.; Maass, J.B.; Carrard, V.C.; Abreu, L.G.; Schuch, L.F.; Uchoa Vasconcelos, A.C. Oral Pigmented Lesions in Syndromic Individuals: A Systematic Review. *Oral Dis.* **2021**, *28*, 531–540. [[CrossRef](#)]
57. Tolentino, E.d.S.; Souza Pinto, G.N.d.; Maciel, L.; Soares, C.T.; Lara, V.S.; Moreschi, A.R.C. Exuberant Manifestation of Neurofibromatosis Type 1 Affecting 3 Generations: Delayed Diagnosis and the Importance of the Multidisciplinary Approach. *Oral Surg. Oral Med. Oral Pathol. Oral Radiol.* **2019**, *128*, e108–e112. [[CrossRef](#)]
58. Javed, F.; Ramalingam, S.; Ahmed, H.B.; Gupta, B.; Sundar, C.; Qadri, T.; Al-Hezaimi, K.; Romanos, G.E. Oral Manifestations in Patients with Neurofibromatosis Type-1: A Comprehensive Literature Review. *Crit. Rev. Oncol. Hematol.* **2014**, *91*, 123–129. [[CrossRef](#)]
59. Fahy, E.; Mulvihill, C.; O’Donoghue, G.; O’Regan, E.; Collins, M. Neurofibromatosis -1 Diagnosed from an Intraoral Swelling—A Case Series. *Aust. Dent. J.* **2021**, *66*, 205–211. [[CrossRef](#)]
60. Thompson, L.D.R.; Koh, S.S.; Lau, S.K. Sporadic Neurofibroma of the Tongue Unassociated with Neurofibromatosis Type I: A Clinicopathologic Study of Ten Cases. *Head Neck Pathol.* **2020**, *14*, 374–380. [[CrossRef](#)]
61. Luna, E.B.; Janini, M.E.R.; Lima, F.; Pontes, R.R.D.A.; Guedes, F.R.; Geller, M.; Da Silva, L.E.; Motta, A.T.; Cunha, K.S. Craniomaxillofacial Morphology Alterations in Children, Adolescents and Adults with Neurofibromatosis 1: A Cone Beam Computed Tomography Analysis of a Brazilian Sample. *Med. Oral Patol. Oral y Cir. Bucal* **2018**, *23*, e168–e179. [[CrossRef](#)]
62. Sheejith, M.; Joseph, B.; Nath, S.G.; Sheejith, B. An Unusual Case of Multiple Intraoral Manifestations of Neurofibromatosis Type 1: Case Report with Literature Review. *J. Clin. Diagn. Res.* **2014**, *8*, ZD20–ZD22. [[CrossRef](#)]
63. Kubota, S.; Imai, T.; Iwai, S.; Nakazawa, M.; Uzawa, N. Gingival Neurofibroma with Teardrop-Shaped Defects of the Interdental Alveolar Bone: An Unusual Oral Manifestation of Neurofibromatosis Type 1. *J. Craniofac. Surg.* **2019**, *30*, E205–E207. [[CrossRef](#)]
64. Warhekar, A.M.; Wanjari, P.V.; Chaudhary, A.; Hada, D.S.; Gupta, R. A Rare Case Report of Neurofibromatosis I in HIV Positive Individual. *J. Clin. Diagn. Res.* **2015**, *9*, 20–22. [[CrossRef](#)]

65. Valério, R.A.; de Queiroz, A.M.; Romualdo, P.C.; Brentegani, L.G.; de Paula-Silva, F.W.G. Mucocele and Fibroma: Treatment and Clinical Features for Differential Diagnosis. *Braz. Dent. J.* **2013**, *24*, 537–541. [[CrossRef](#)]
66. Kilinc, A.; Saruhan, N.; Gundogdu, B.; Yalcin, E.; Ertas, U.; Urvasizoglu, G. Benign Tumors and Tumor-like Lesions of the Oral Cavity and Jaws: An Analysis of 709 Cases. *Niger. J. Clin. Pract.* **2017**, *20*, 1448–1454. [[CrossRef](#)]
67. Dhanuthai, K.; Kintarak, S.; Subarnbhesaj, A.; Chamusri, N. A Multicenter Study of Tongue Lesions from Thailand. *Eur. J. Dent.* **2020**, *14*, 435–439. [[CrossRef](#)]
68. Ogle, O.E.; Santosh, A.B.R. Medication Management of Jaw Lesions for Dental Patients. *Dent. Clin. North Am.* **2016**, *60*, 483–495. [[CrossRef](#)]
69. Matsumoto, N.; Tsuchiya, M.; Nomoto, S.; Matsue, Y.; Nishikawa, Y.; Takamura, T.; Oki, H.; Komiyama, K. CD105 Expression in Oral Capillary Hemangiomas and Cavernous Hemangiomas. *J. Oral Sci.* **2015**, *57*, 45–53. [[CrossRef](#)]
70. Barrón-Peña, A.; Martínez-Borras, M.A.; Benítez-Cárdenas, O.; Pozos-Guillén, A.; Garrocho-Rangel, A. Management of the Oral Hemangiomas in Infants and Children: Scoping Review. *Med. Oral Patol. Oral y Cir. Bucal* **2020**, *25*, e252–e261. [[CrossRef](#)]
71. Dehart, A.; Richter, G. Hemangioma: Recent Advances. *F1000Research* **2019**, *8*, 6–11. [[CrossRef](#)] [[PubMed](#)]
72. Yuhan, B.T.; Svider, P.F.; Mutchnick, S.; Sheyn, A. Benign and Malignant Oral Lesions in Children and Adolescents: An Organized Approach to Diagnosis and Management. *Pediatr. Clin. N. Am.* **2018**, *65*, 1033–1050. [[CrossRef](#)]
73. Ademi Abdyl, R.; Abdyl, Y.; Perjuci, F.; Gashi, A.; Agani, Z.; Ahmedi, J. Sclerotherapy of Intraoral Superficial Hemangioma. *Case Rep. Dent.* **2016**, *2016*, 12–14. [[CrossRef](#)] [[PubMed](#)]
74. Maymone, M.B.C.; Greer, R.O.; Burdine, L.K.; Dao-Cheng, A.; Venkatesh, S.; Sahitya, P.C.; Maymone, A.C.; Kesecker, J.; Vashi, N.A. Benign Oral Mucosal Lesions: Clinical and Pathological Findings. *J. Am. Acad. Dermatol.* **2019**, *81*, 43–56. [[CrossRef](#)] [[PubMed](#)]
75. Bharti, V.; Singh, J. Capillary Hemangioma of Palatal Mucosa. *J. Indian Soc. Periodontol.* **2012**, *16*, 475–478. [[CrossRef](#)]
76. De Mesquita Netto, A.C.; De Oliveira, M.B.; Bernardes, V.F.; Gomes, C.C.; Gomez, R.S. Wilms Tumor 1 Protein Is Not Expressed in Oral Lymphangiomas. *Braz. Dent. J.* **2012**, *23*, 707–710. [[CrossRef](#)]
77. Usha, V.; Sivasankari, T.; Jeelani, S.; Asokan, G.S.; Parthiban, J. Lymphangioma of the Tongue—A Case Report and Review of Literature. *J. Clin. Diagn. Res.* **2014**, *8*, ZD12–ZD14. [[CrossRef](#)]
78. Bowers, E.M.R.; Schaitkin, B. Management of Mucoceles, Sialoceles, and Ranulas. *Otolaryngol. Clin. N. Am.* **2021**, *54*, 543–551. [[CrossRef](#)]
79. Ayhan, E.; Toprak, S.F.; Kaya, Ş.; Akkaynak, Ş. Dermoscopy of Oral Mucocele: Three Types of Extravasation Mucoceles. *Turkish J. Med. Sci.* **2020**, *50*, 96–102. [[CrossRef](#)]
80. Bhargava, N.; Agarwal, P.; Sharma, N.; Agrawal, M.; Sidiq, M.; Narain, P. An Unusual Presentation of Oral Mucocele in Infant and Its Review. *Case Rep. Dent.* **2014**, *2014*, 723130. [[CrossRef](#)]
81. Joshi, S.R.; Pendyala, G.S.; Choudhari, S.; Kalburge, J. Mucocele of the Glands of Blandin-Nuhn in Children: A Clinical, Histopathologic, and Retrospective Study. *N. Am. J. Med. Sci.* **2012**, *4*, 379–383. [[CrossRef](#)]
82. Choi, Y.J.; Byun, J.S.; Choi, J.K.; Jung, J.K. Identification of Predictive Variables for the Recurrence of Oral Mucocele. *Med. Oral Patol. Oral y Cir. Bucal* **2019**, *24*, e231–e235. [[CrossRef](#)]
83. Abdel-Aziz, M.; Khalifa, B.; Nassar, A.; Kamel, A.; Naguib, N.; El-Tahan, A.R. Mucocele of the Hard Palate in Children. *Int. J. Pediatr. Otorhinolaryngol.* **2016**, *85*, 46–49. [[CrossRef](#)]
84. Carlson, E.R.; Ord, R.A. Benign Pediatric Salivary Gland Lesions. *Oral Maxillofac. Surg. Clin. N. Am.* **2016**, *28*, 67–81. [[CrossRef](#)]
85. Piazzetta, C.M.; Torres-Pereira, C.; Amenábar, J.M. Micro-Marsupialization as an Alternative Treatment for Mucocele in Pediatric Dentistry. *Int. J. Paediatr. Dent.* **2012**, *22*, 318–323. [[CrossRef](#)]
86. Silva, D.F.B.; Neves, G.d.V.; Moura, R.Q.d.; Carvalho, S.H.G.d.; Pereira, J.V.; Gomes, D.Q.d.C. Modified Micromarsupialization as Treatment of Ranula in a Pediatric Patient. *J. Craniofac. Surg.* **2020**, *31*, e230–e232. [[CrossRef](#)]
87. Saikaly, S.K.; Saikaly, T.S.; Saikaly, L.E. Recurrent Aphthous Ulceration: A Review of Potential Causes and Novel Treatments. *J. Dermatolog. Treat.* **2018**, *29*, 542–552. [[CrossRef](#)]
88. Fitzpatrick, S.G.; Cohen, D.M.; Clark, A.N. Ulcerated Lesions of the Oral Mucosa: Clinical and Histologic Review. *Head Neck Pathol.* **2019**, *13*, 91–102. [[CrossRef](#)]
89. Bakshi, S.S.; Bakshi, S. Recurrent Aphthous Stomatitis. *Arch. Med. Health Sci.* **2019**, *7*, 317–318. [[CrossRef](#)]
90. Ślebioda, Z.; Szponar, E.; Kowalska, A. Etiopathogenesis of Recurrent Aphthous Stomatitis and the Role of Immunologic Aspects: Literature Review. *Arch. Immunol. Ther. Exp. (Warsz.)* **2014**, *62*, 205–215. [[CrossRef](#)]
91. Giannetti, L.; Murri Dello Diago, A.; Lo Muzio, L. Recurrent Aphthous Stomatitis. *Minerva Stomatol.* **2018**, *67*, 125–128. [[CrossRef](#)] [[PubMed](#)]
92. Shah, K.; Guarderas, J.; Krishnaswamy, G. Aphthous Stomatitis. *Ann. Allergy Asthma Immunol.* **2016**, *117*, 341–343. [[CrossRef](#)] [[PubMed](#)]
93. Chiang, C.P.; Yu-Fong Chang, J.; Wang, Y.P.; Wu, Y.H.; Wu, Y.C.; Sun, A. Recurrent Aphthous Stomatitis—Etiology, Serum Autoantibodies, Anemia, Hematinic Deficiencies, and Management. *J. Formos. Med. Assoc.* **2019**, *118*, 1279–1289. [[CrossRef](#)] [[PubMed](#)]
94. Alrashdan, M.S.; Alkhader, M. Psychological Factors in Oral Mucosal and Orofacial Pain Conditions. *Eur. J. Dent.* **2017**, *11*, 548–552. [[CrossRef](#)] [[PubMed](#)]

- 
95. Mujayanto, R. Aphthous Stomatitis Following Ageusia in SARS-CoV-2 Reinfection: A Case Report. *Eur. J. Dent.* **2021**, *15*, 817–819. [[CrossRef](#)]
  96. Altenburg, A.; El-Haj, N.; Micheli, C.; Puttkammer, M.; Abdel-Naser, M.B.; Zouboulis, C.C. The Treatment of Chronic Recurrent Oral Aphthous Ulcers. *Dtsch. Arztebl. Int.* **2014**, *111*, 665–673. [[CrossRef](#)]
  97. Cui, R.Z.; Bruce, A.J.; Rogers, R.S. Recurrent Aphthous Stomatitis. *Clin. Dermatol.* **2016**, *34*, 475–481. [[CrossRef](#)]
  98. Paradowska-Stolarz, A.M. Oral Manifestations of COVID-19: Brief Review. *Dent. Med. Probl.* **2021**, *58*, 123–126. [[CrossRef](#)]
  99. Amorim dos Santos, J.; Normando, A.G.C.; Carvalho da Silva, R.L.; De Paula, R.M.; Cembranel, A.C.; Santos-Silva, A.R.; Guerra, E.N.S. Oral Mucosal Lesions in a COVID-19 Patient: New Signs or Secondary Manifestations? *Int. J. Infect. Dis.* **2020**, *97*, 326–328. [[CrossRef](#)]