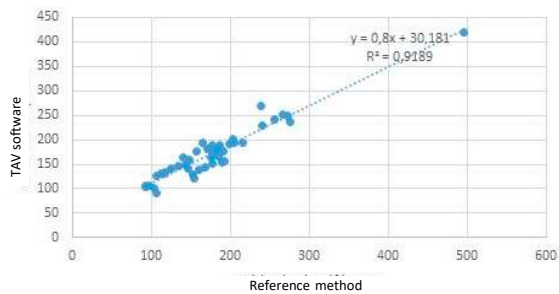
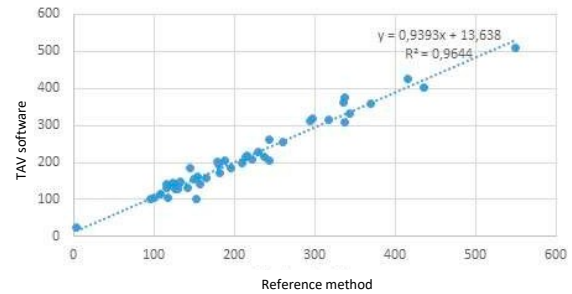


Supplemental figure legends

True lumen

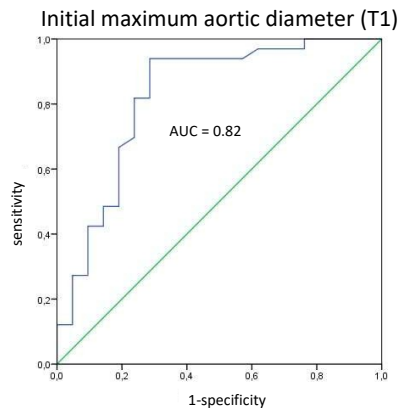


False lumen

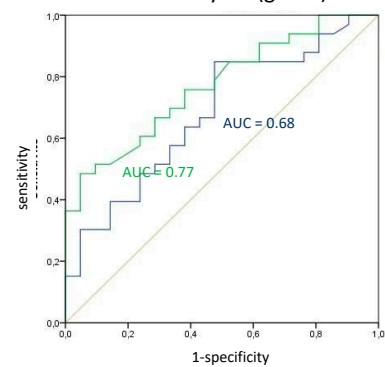


Scheme S1. Validation of the custom application TAV results.

Comparison of the results obtained using a reference method by another observer [23–25].



aortic diameter evolution at 3 months (blue) and 1 year (green)



Scheme S2. ROC curve showing the sensitivity and specificity of the total aortic diameter measurement at T1.

ROC curve showing the sensitivity and specificity of the aortic diameter evolution at 3 months (blue) and 1 year (green).

References

23. England, A.; Fisher, R.; McWilliams, R.; Torella, F. Estimating the error of CT-based measurements of aortic lumen volume used in endovascular planning. *Radiography* 2017, 23, 287–291.
24. Concistrè, G.; Casali, G.; Santaniello, E.; Montalto, A.; Fiorani, B.; Dell'Aquila, A.; Musumeci, F. Reoperation after surgical correction of acute type A aortic dissection: Risk factor analysis. *Ann. Thorac. Surg.* 2012, 93, 450–455.
25. Kimura, N.; Tanaka, M.; Kawahito, K.; Yamaguchi, A.; Ino, T.; Adachi, H. Influence of patent false lumen on long-term outcome after surgery for acute type A aortic dissection. *J. Thorac. Cardiovasc. Surg.* 2008, 136, 1160–1166, 1166 e1–e3.