

The Brain Imaging Collaboration Suite (BrICS): A Cloud Platform for Integrating Whole-Brain Spectroscopic MRI into the Radiation Therapy Planning Workflow

Saumya Gurbani^{1,2}, Brent Weinberg³, Lee Cooper^{2,4}, Eric Mellon⁵, Eduard Schreibmann¹, Sulaiman Sheriff⁶, Andrew Maudsley⁶, Mohammed Goryawala⁶, Hui-Kuo Shu¹, and Hyunsuk Shim^{1,2,3}

Departments of ¹Radiation Oncology, ²Biomedical Engineering, ³Radiology and Imaging Sciences, and ⁴Biomedical Informatics, Emory University, Atlanta, GA; Departments of ⁵Radiation Oncology and ⁶Radiology, University of Miami Miller School of Medicine, Miami, FL

Corresponding Author:

Hyunsuk Shim, PhD

Department of Radiology and Imaging Sciences, Emory University, Atlanta, GA, USA;

E-mail: hshim@emory.edu

Key Words: spectroscopic MRI, radiation therapy, cloud platform

Abbreviations: Radiation therapy (RT), magnetic resonance imaging (MRI), spectroscopic MRI (sMRI), fluid-attenuation inversion recovery (FLAIR), magnetic resonance spectroscopy (MRS), 3-dimensional (3D), N-acetylaspartate (NAA), normal-appearing white matter (NAWM), Digital Imaging and Communication in Medicine (DICOM), echo planar spectroscopic imaging (EPSI)

ABSTRACT

Glioblastoma has poor prognosis with inevitable local recurrence despite aggressive treatment with surgery and chemoradiation. Radiation therapy (RT) is typically guided by contrast-enhanced T1-weighted magnetic resonance imaging (MRI) for defining the high-dose target and T2-weighted fluid-attenuation inversion recovery MRI for defining the moderate-dose target. There is an urgent need for improved imaging methods to better delineate tumors for focal RT. Spectroscopic MRI (sMRI) is a quantitative imaging technique that enables whole-brain analysis of endogenous metabolite levels, such as the ratio of choline-to-N-acetylaspartate. Previous work has shown that choline-to-N-acetylaspartate ratio accurately identifies tissue with high tumor burden beyond what is seen on standard imaging and can predict regions of metabolic abnormality that are at high risk for recurrence. To facilitate efficient clinical implementation of sMRI for RT planning, we developed the Brain Imaging Collaboration Suite (BrICS; <https://brainimaging.emory.edu/brics-demo>), a cloud platform that integrates sMRI with standard imaging and enables team members from multiple departments and institutions to work together in delineating RT targets. BrICS is being used in a multisite pilot study to assess feasibility and safety of dose-escalated RT based on metabolic abnormalities in patients with glioblastoma (Clinicaltrials.gov NCT03137888). The workflow of analyzing sMRI volumes and preparing RT plans is described. The pipeline achieved rapid turnaround time by enabling team members to perform their delegated tasks independently in BrICS when their clinical schedules allowed. To date, 18 patients have been treated using targets created in BrICS and no severe toxicities have been observed.

INTRODUCTION

The standard-of-care treatment for glioblastoma, the most common adult primary malignant brain tumor, consists of maximal safe surgical resection of tumor followed by high-dose radiation therapy (RT) with concomitant temozolomide chemotherapy (1-4). The standard high-dose prescription of 60 Gy is delivered over 30 fractions to regions of enhancement on T1-weighted contrast-enhanced (CE-T1w) MRI, in which enhancement represents areas of tumor with leaky neovasculature. A lower dose of RT (typically 46–54 Gy) is delivered to areas of hyperintensity on T2-weighted fluid-attenuation inversion recovery (FLAIR) MRI (5). FLAIR hyperintensity corresponds to a nonspecific combination of tumor and nontumor pathologies, including

inflammation and vasogenic edema (6). Despite improvements in maximal resection, concurrent and adjuvant chemotherapy, and RT, the median overall survival still remains poor at 15 months (7, 8), with median progression-free survival at only 4–6 months (9). Recurrent glioblastoma is very difficult to treat, often being resistant to further radiation and inaccessible for secondary surgical resection (10). The location of recurrent disease can also vary: within the original 60-Gy RT target, within the intermediate dose area, or to regions several centimeters away, including crossing the midline (11). Both local and distant recurrences need to be addressed to improve progression-free survival. In a phase II study where glioblastomas were treated with high-dose proton therapy up to 90 cobalt-gray equivalent,

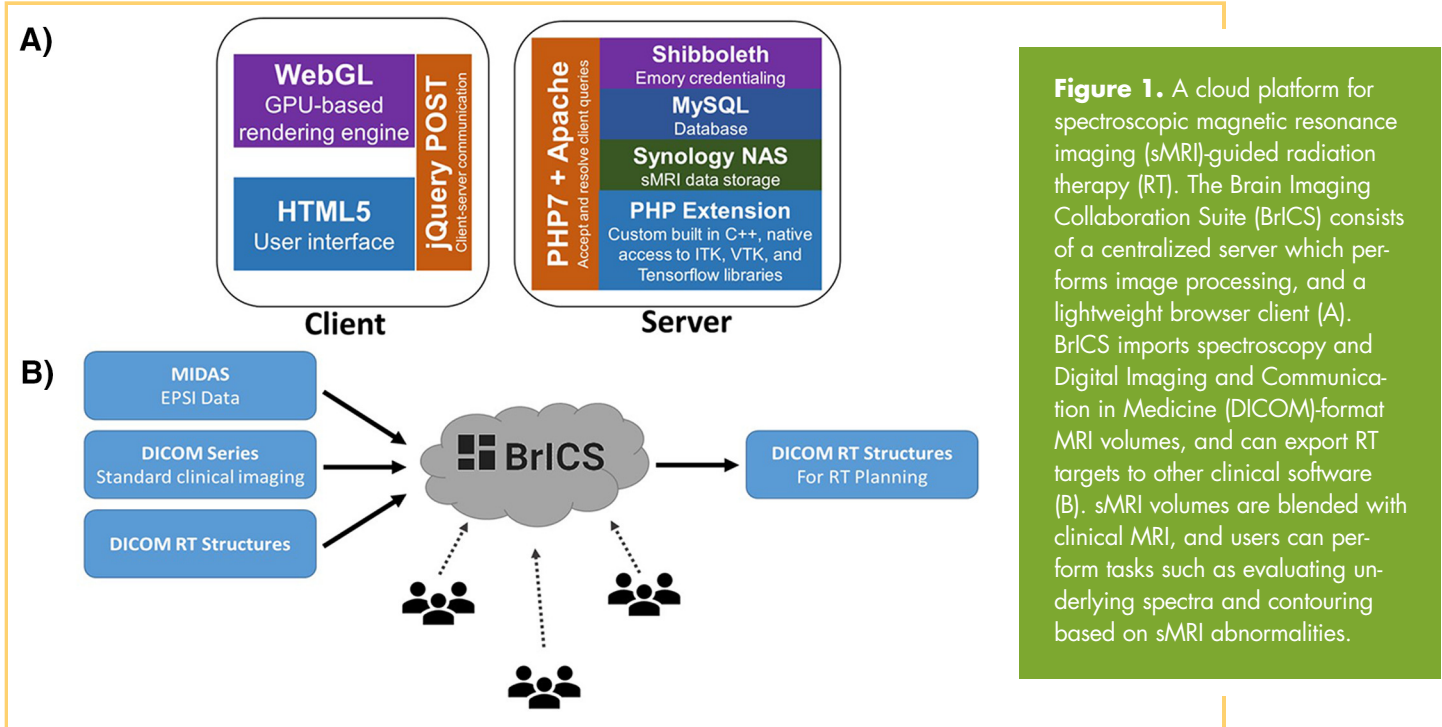


Figure 1. A cloud platform for spectroscopic magnetic resonance imaging (sMRI)-guided radiation therapy (RT). The Brain Imaging Collaboration Suite (BrICS) consists of a centralized server which performs image processing, and a lightweight browser client (A). BrICS imports spectroscopy and Digital Imaging and Communication in Medicine (DICOM)-format MRI volumes, and can export RT targets to other clinical software (B). sMRI volumes are blended with clinical MRI, and users can perform tasks such as evaluating underlying spectra and contouring based on sMRI abnormalities.

it was observed that almost all disease recurred in regions receiving <70 cobalt-gray equivalent (12). Thus, it appears that dose escalation may provide sufficient tumoricidal doses to achieve local control. However, doses >70 Gy need to be applied selectively to prevent toxicity that could result from excess volumes of normal brain receiving doses of that magnitude.

Spectroscopic magnetic resonance imaging (sMRI) is an evolution of magnetic resonance (MR) spectroscopy (MRS) that enables 3-dimensional (3D) whole-brain volumes of metabolite levels to be obtained in vivo without contrast agents or radioactive tracers (13, 14). Two metabolites of particular interest in patients with glioblastoma include choline-containing compounds (Cho), the building blocks of the cell membrane that increase in proliferating tumor cells, and N-acetylaspartate (NAA), a biomarker found in healthy neurons, which diminishes owing to neuronal displacement and death from glial infiltration (13, 15). It has been previously shown via histological correlation that the ratio of Cho to NAA is significantly elevated in glioblastoma owing to the opposing changes in these metabolites; in particular, a two-fold increase in Cho/NAA compared to healthy tissue in contralateral normal-appearing white matter (NAWM) was able to correctly identify tumor in 100% of cases, even when tissue samples were biopsied from regions outside of contrast-enhancement per CE-T1w or FLAIR hyperintensity (16).

A combination of dose escalation guided by sMRI, including regions of occult tumor normally left untreated by high-dose RT, could potentially delay recurrence of disease by delivering a cytotoxic dose of radiation to regions of metabolically abnormal tumor even if these areas are not detected using standard imaging techniques. However, the use of sMRI in clinical practice has been hampered by data processing requirements and limited integration into the RT planning workflow. In previous studies,

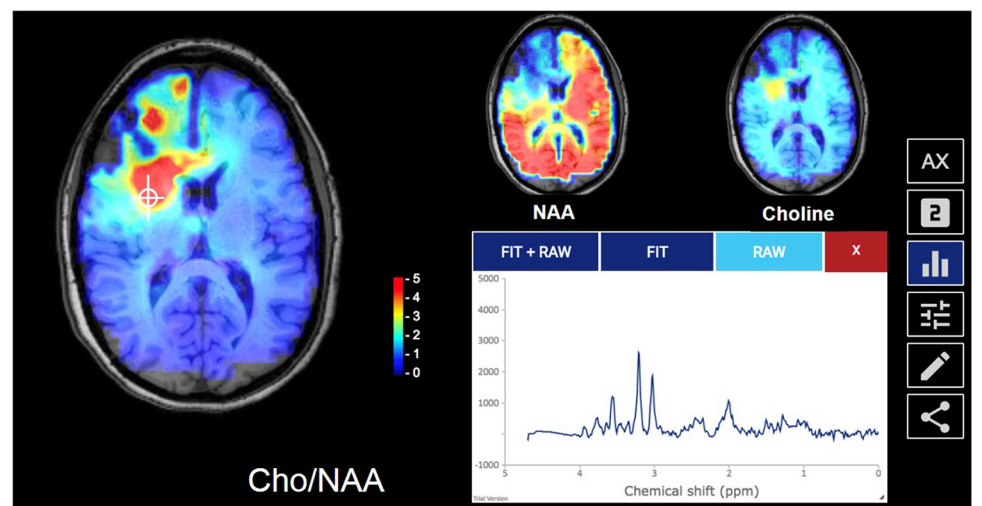
several time-intensive manual processing steps were required to import metabolite volumes into clinical imaging software so that they could be used in the operating room or for RT planning (17, 18). To enable integration of sMRI into clinical practice, we have developed a software platform designed specifically for the integration of sMRI into the RT planning workflow. In this paper, we describe its architecture and show its features on several sample cases. We show feasibility of this software for collaborative use in a prospective multi-institutional clinical study to target dose-escalated RT based on sMRI. Several challenges in integrating this imaging modality into the clinical workflow are addressed, and a sample case from the ongoing study is presented to show that RT to high-risk regions can be targeted by quantitative imaging techniques such as sMRI.

MATERIALS AND METHODS

Software Architecture

To assist with a collaborative clinical study across institutions, we developed the Brain Imaging Collaboration Suite (BrICS), a web-based software designed specifically to integrate sMRI with clinical MRI volumes, enabling physicians to evaluate relevant metabolite levels and the underlying spectra used for this quantitation, and to delineate target volumes for RT planning based on this information (19). BrICS consists of 2 components: a centralized server and a lightweight browser client (Figure 1A). The server performs computations necessary to analyze and display whole-brain spectroscopy; it consists of modules written in C++ and the PHP server-side scripting language to take advantage of well-established image processing and linear algebra libraries (20, 21). The lightweight browser client written in JavaScript can run on all modern hardware, including thin clients such as laptops and tablets. This browser-based approach offers the following benefits over standalone software clients: (1) improves repeatability and standardization by ensuring data

Figure 2. The main user interface for BrICS. sMRI metabolite and metabolite ratio maps are overlaid on top of anatomic magnetic resonance (MR) volumes. Selection of a given voxel brings up the underlying spectrum.



are processed on the same hardware; (2) reduces user variability and bias; (3) enables real-time deployment of software updates across all clients; (4) prevents the need for every end-user to download massive sMRI data sets onto a local computer; (5) runs without the need for the user to download any software beyond a web browser, which is of key importance, as physicians often use restricted hospital workstations; and (6) allows information and images to be easily shared with patients who wish to be better informed of their clinical management.

BrICS imports data from spectroscopy processing software, such as the Metabolite Imaging and Data Analysis Software (MIDAS, University of Miami, Miami, FL), and from other imaging systems/software using the Digital Imaging and Communication in Medicine (DICOM) file format. All volumes are coregistered using a rigid transformation and resampled using trilinear interpolation into a high-resolution T1w image space, enabling overlays of metabolic information onto anatomic MRI. Users can then delineate target volumes based on both anatomic and spectroscopic information. These targets can be exported as DICOM RT structure sets (DICOM RT) or binary DICOM masks and imported into RT planning systems to deliver therapy to patients (Figure 1B). A video showing the features of BrICS is available in online Supplemental Video 1 [PLAY VIDEO](#), which are described in detail in the following subsections.

Visualization and Contouring

The main interface of BrICS is shown in Figure 2. sMRI volumes—either individual metabolites or metabolite ratios—are overlaid on anatomic volumes (eg, T1w MRI), enabling visual assessment of metabolic changes in spatially dependent manner. For MR spectroscopists and radiologists familiar with MRS techniques, selection of a voxel will bring up the corresponding spectrum. Because sMRI is a quantitative imaging technique, voxel intensities can be reliably interpreted across subjects, and decision-making can be based on specified thresholds. This ability is built-in to the contouring module; physicians can make contours based on the values in sMRI maps (Figure 3 and online Supplemental Video 1 [PLAY VIDEO](#)). For example, the Cho/NAA volume abnormality index (16) can be used, as shown, to generate a contour around all voxels which have a Cho/NAA

abnormality index above a given threshold. Users can select this threshold and automatically generate contours of increasing or decreasing sensitivity of disease detection. Radiologists can then review these contours and make changes to them using built-in editing tools (painting, erasing, or selection of connected-components). Once contours are generated, they can be visualized as 3D volumes, enabling visual quality assessment and correspondence with anatomy. Statistics such as contour volume and number of connected components are also reported.

Normalization of Metabolite Values

Cerebral concentrations of several macromolecules, including Cho and NAA, are known to vary based on a subject's age, gender, and anatomic location of brain being sampled (22). To account for these variations in baseline metabolism, metrics such as the Cho/NAA abnormality index (16) and the Cho-NAA index (23) take into account relative changes in these metabolites compared to normal tissue, typically contralateral NAWM (24). For this trial, we use the Cho/NAA abnormality index, defined as the Cho/NAA of a given voxel divided by the mean Cho/NAA value in contralateral NAWM. In previous works (16–18), NAWM was manually contoured on a clinical T1w volume by a neuroradiologist using commercial software, then the mask exported and applied to sMRI data to determine the mean Cho/NAA value. To expedite this process, remove reliance on commercial software, and mitigate user bias, we have implemented an algorithm in BrICS to automatically contour the NAWM based on a Gaussian mixture model (25) (Figure 4). First, all voxels from the cerebrum are masked using an anatomic atlas. Next, all cerebral Cho/NAA voxels are modeled as a bimodal Gaussian distribution, with voxels arising from the second, higher-mean Gaussian population representative of tumor pathology. These voxels are then masked, and the side with largest contiguous abnormal segment is selected as the side of tumor; voxels in the contralateral hemisphere are segmented into gray and white matter based on fractional water content (26) calculated by MIDAS, and then the mean is reported as the normalizing factor for the subject's abnormality index calculations.

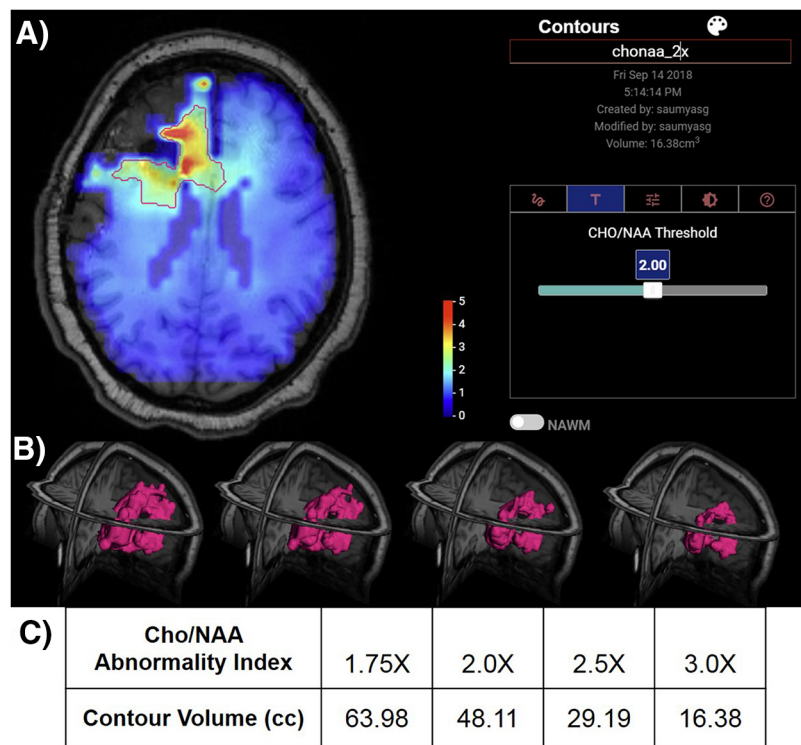


Figure 3. Contouring of target volumes. The contouring module enables identification of target volumes based on either anatomic or metabolite images (A). For quantitative imaging techniques like sMRI, users can automatically delineate contours using threshold values. A series of targets based on thresholding of the Cho/NAA abnormality index; target volumes can be rendered in 3D for visual inspection prior to being exported to other clinical software (B). A summary of the volumes generated for varying Cho/NAA abnormality indices (C).

Automated Segmentation of Residual Contrast Enhancement

Additional algorithmic modules can be built into BrICS to assist with other routines that are regularly performed by clinicians. One such module automatically contours residual contrast enhancing tissue (Figure 5), so as to differentiate true unresected tumor with leaky neovasculature from blood products owing to surgical resection (27). The module requires a precontrast T1w

MRI, a CE-T1w MRI, and a T2w or FLAIR MRI, all of which are coregistered into the same imaging space and resampled to an axial view. The pre- and postcontrast MR images are histogram normalized and subtracted to generate a difference map; Otsu thresholding with four classes is used to identify residual enhancement (28, 29). Otsu thresholding is applied to the FLAIR map to automatically identify hyperintensity; the single largest connected component is used as a bounding mask for the T1w

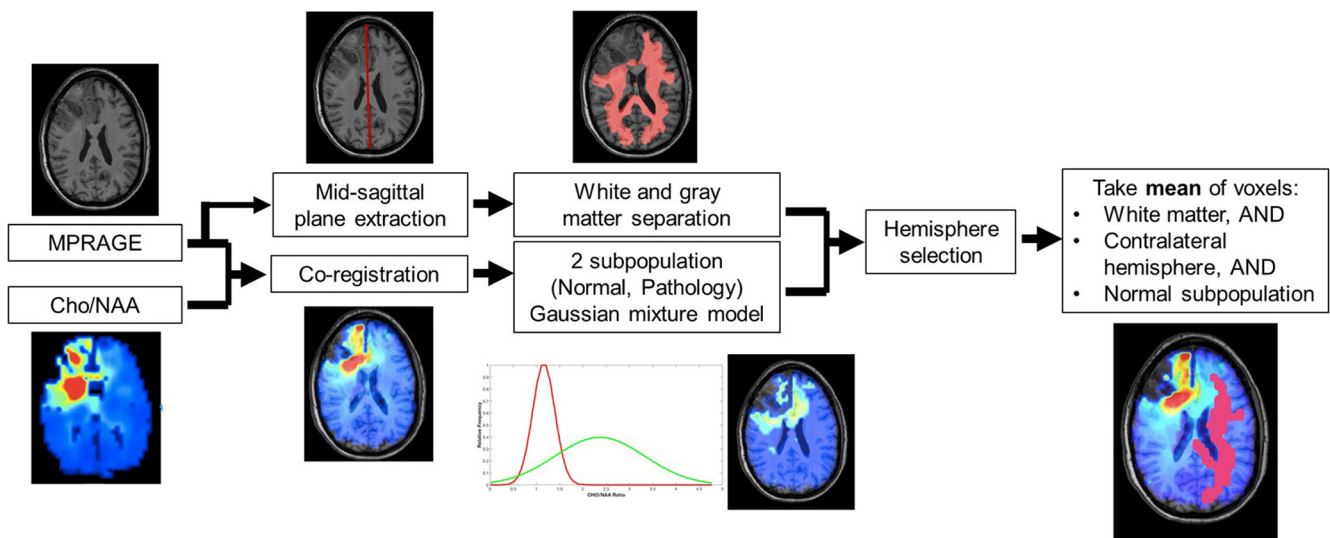


Figure 4. Normalization of metabolite maps by baseline metabolism. High-level schematic of a Gaussian mixture model used to identify regions of normal-appearing white matter (NAWM), which is used as a personal metabolic baseline for the patient. NAWM is typically contoured manually by radiologists; this algorithm can perform the same contouring automatically in just a few seconds.

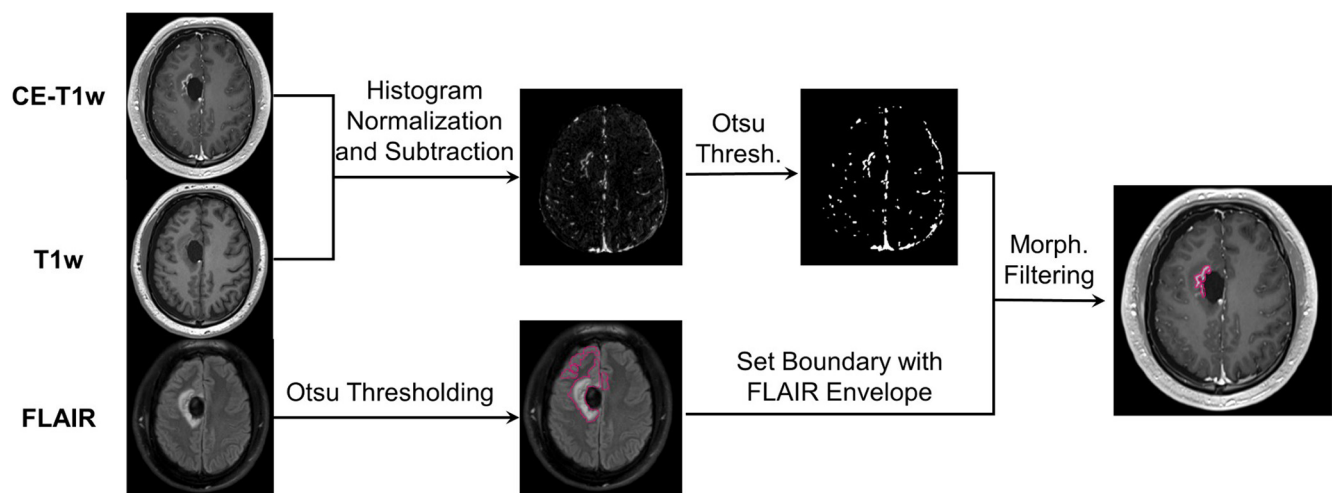


Figure 5. Automated residual contrast enhancement contouring. BrICS takes a postcontrast T1-weighted (T1w) MRI (top), precontrast T1w MRI (middle), and a FLAIR MRI (bottom) volume, and follows the shown algorithm to rapidly contour residual contrast enhancement postsurgical resection. This volume can then be edited manually by the neuroradiologist or radiation oncologist as desired to define a dose-escalated volume.

residual volume. Finally, morphological opening and closing filters are applied to the bounded T1w residual volume to remove islets and thin anisotropic components, e.g. blood vessels. The entire algorithm can be run in <10 seconds on the BrICS server and yields a final contour, which can be evaluated and manually edited, if necessary, by a neuroradiologist—saving valuable clinician time and providing a reproducible starting point for all users.

Patient Enrollment and Imaging

To assess the feasibility and safety of sMRI-guided RT, a multi-site clinical study funded by NCI was initiated (Clinicaltrials.gov NCT03137888). Three institutions are participating in this pilot study—Emory University, the Johns Hopkins University, and the University of Miami—and a total of 30 patients with newly diagnosed glioblastoma will be enrolled. Patients are enrolled after undergoing maximal safe surgical resection or biopsy at the discretion of the neurosurgeon. Enrolled patients were ≥ 18 years of age, had a Karnofsky Performance Score ≥ 60 , and were willing to undergo dose-escalated RT to 75 Gy.

An sMRI scan was obtained within 2 weeks prior to starting RT + temozolomide. A 15-minute echo planar spectroscopic imaging (EPSI) pulse sequence combined with GRAPPA [parallel imaging (30)], was performed on a 3 T scanner (Siemens Medical Solutions, Erlangen, Germany) with a 32-channel or a 20-channel head coil array (echo time = 50 milliseconds, repetition time = 1551 milliseconds, flip angle = 71°). During the same session, a high-resolution T1w magnetization prepared rapid acquisition gradient echo (MP-RAGE) sequence was obtained at the same orientation and position as the EPSI. Raw EPSI data were transformed into spatial-spectral data, coregistered with the MP-RAGE volume, and the relative metabolite concentration values were obtained by spectral fitting using MIDAS (22, 30).

RT Planning

An outline of the workflow for patients in this study is shown in Figure 6. The EPSI/GRAPPA and MP-RAGE volumes, in addition to the most recent clinical CE-T1w and FLAIR MRI, were imported into BrICS. Automated contours for Cho/NAA abnormality index of 2.0 and residual contrast-enhancing tissue were generated using the algorithms described above. Using BrICS, 2 MR spectroscopists from different institutions collaboratively reviewed the underlying raw and fitted spectra within the Cho/NAA abnormal contour and removed voxels with poor spectral quality. Meanwhile, a neuroradiologist reviewed and edited the residual contrast-enhancing volume to ensure accurate delineation of the target volume. The 2 contours were then merged to form a single target volume for high-dose RT. Next, an external radiation oncologist (from a nontreating site) edited and approved the volume based on anatomy and dose safety concerns. Finally, the treating-site radiation oncologist made final edits based on his/her discretion and validated the volume for RT treatment. To ensure patient safety and to enable retrospective review of this study, all user edits were tracked in BrICS in a digital audit trail.

The final contour generated in BrICS was defined as gross tumor volume 3 (GTV3). The clinical target volume 3 (CTV3) was defined as equal to GTV3 with no margin. In this pilot feasibility study, a maximum volume of 65 cm^3 was allowed for CTV3, approximately adhering to the 5-cm-diameter boost volume limit used in the NRG Oncology BN001 phase II trial on RT dose escalation for glioblastomas (31). The CTV3 contour was exported from BrICS as a DICOM RT structure set on the high resolution T1w MP-RAGE volume into additional contouring or treatment planning software such as VelocityAI (Varian Medical Systems, Palo Alto, CA), MIM Maestro (MIM Software Inc, Cleveland, OH), Eclipse (Varian Medical Systems, Palo Alto, CA),

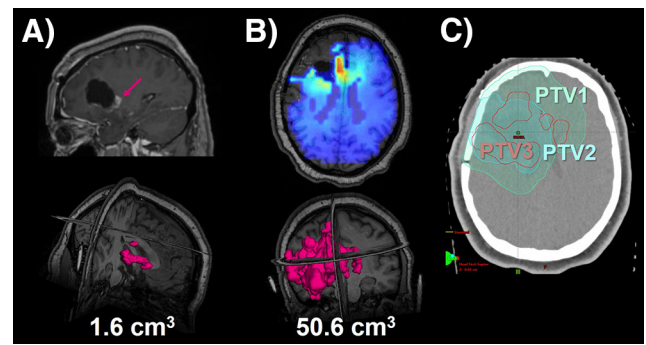
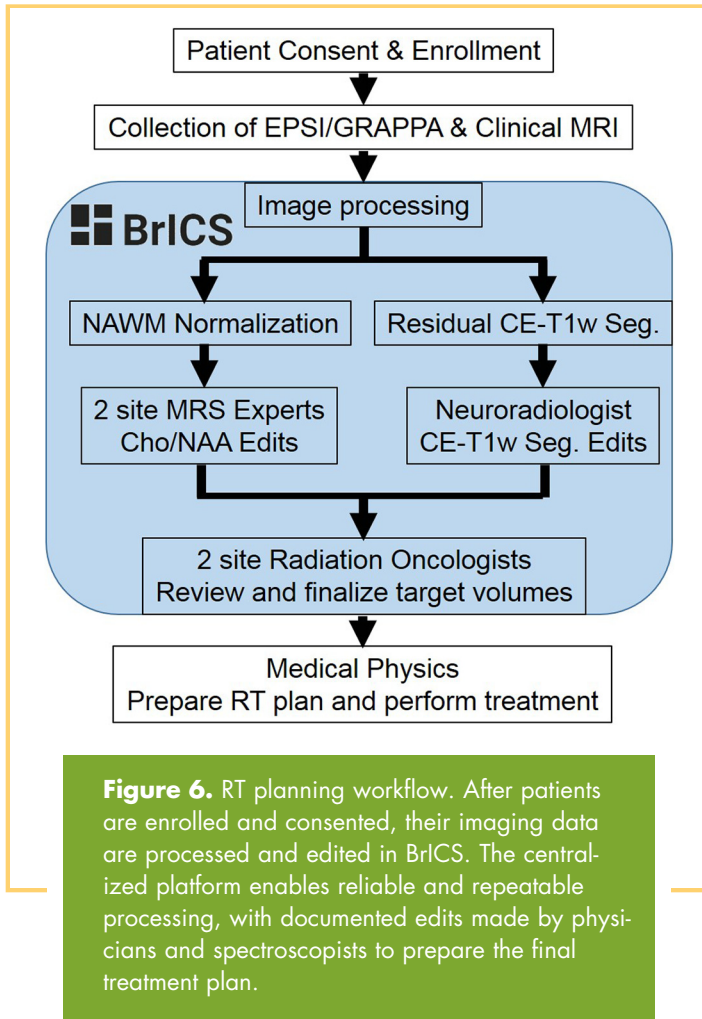


Figure 7. Example treatment plan for study patient. The patient is a 21-year-old woman with newly diagnosed glioblastoma with a near-total resection of the tumor (A). However, the Cho/NAA map indicates metabolically active tumor expanding outward from the resection cavity (B). A boosted dose of 75 Gy (PTV3) was successfully planned and delivered to this patient (C).

Pinnacle (Philips Healthcare, Best, Netherlands), etc., per the routine of the treating site. Additional standard treatment volumes were generated including GTV2, defined as the surgical cavity with residual contrast enhancement, and GTV1, defined as hyperintensity on FLAIR MRI. Five millimeter of anatomically constrained margins were added to GTV2 and GTV1 to produce CTV2 and CTV1, respectively. A 3-mm margin was added to all 3 CTVs to produce the planning target volumes (PTV3, PTV2, and PTV1). A simultaneous in-field boost IMRT plan was generated to treat PTV3, PTV2, and PTV1 to 75 Gy, 60 Gy, and 50.1 Gy, respectively, respecting standard organs-at-risk constraints (Table 1).

RESULTS

A demo of BrICS is available at <https://brainimaging.emory.edu/brics-demo> with a few curated and deidentified data sets. A video describing the platform and its features is presented in the online Supplemental Video 1 [PLAY VIDEO](#). In addition to the dose-escalated RT study described above, BrICS is currently being used for the following clinical projects internally at Emory University: targeting of biopsies in patients with nonenhancing low-grade gliomas, monitoring therapeutic response of patients with glioblastoma receiving a histone-deacetylase inhibitor in addition to standard chemoradiation, identification of metabolite abnormalities associated with melanoma brain metastasis, and a pilot study evaluating the benefit of sMRI for patients with mild traumatic brain injury. In addition, BrICS served as the platform for testing new imaging processing algorithms such as a neural network for identifying spectral artifacts (32) and autoencoder-based spectral fitting (unpublished data).

RT plans from 1 patient who underwent dose escalation as per this study’s protocol are presented in Figure 7. The patient is a 21-year-old woman diagnosed with a frontal glioblastoma and enrolled in the trial 1 month after undergoing surgical

Table 1. Summary of Target Volume Definitions and Dose Prescription for This Clinical Study

| Target Name | Definition | CTV Margin (mm) | PTV Margin (mm) | Dose (Gy) |
|-------------|--|-----------------|-----------------|-----------|
| GTV3 | Cho/NAA abnormality index ≥ 2 + residual contrast enhancement | 0 | 3 | 75 |
| GTV2 | Contrast enhancing tissue + resection cavity, per standard of care | 5 | 3 | 60 |
| GTV1 | FLAIR hyperintensity, per standard of care | 5 | 3 | 50.1 |

In addition to standard chemoradiation (GTV1 and GTV2), a boost is given to areas of sMRI abnormality and residual contrast enhancement (GTV3). All doses are delivered over 30 fractions.

resection of her tumor. sMRI volumes were obtained and processed in MIDAS and in BrICS per the protocol. The neuroradiologists, MR spectroscopists, and radiation oncologists accessed BrICS remotely for several minutes each, when time was available during their busy schedules. Segmentation of residual contrast enhancement by the automated algorithm, followed by neuroradiologist review, identified a 1.6-cm³ nodular residual contrast-enhancing lesion on the posterior border of the surgical cavity remaining after surgery, typical of patients who underwent near total resections (Figure 7A). However, the Cho/NAA abnormality was much greater with a volume of 50.6 cm³, expanding laterally, anteriorly, and posteriorly from the surgical cavity (Figure 7B). GTV3 was planned on the union of these 2 contours, and targeted for a 75-Gy boost. The contour for GTV3 was exported as a DICOM RT structure and imported into Eclipse for dose planning (Figure 7C). Dose constraints based on RTOG guidelines to all organs at risk were met, with >95% of the prescribed dose delivered to each PTV.

DISCUSSION

Current treatments for glioblastoma are insufficient in achieving local control. This is felt to be due in part to limitations of standard imaging methods in identification of infiltrating tumor margins, which show no contrast enhancement, potentially leaving these high-risk regions undertreated. Improvements in treatment options, such as with higher radiation doses, can only be beneficial if all high-risk tumor regions (both enhancing and nonenhancing) are properly targeted. In this work, we develop a software platform that successfully enables sMRI integration into the RT planning workflow. The EPSI/GRAPPA sequence can be used on standard 3 T instrumentation, and the current version of the sequence is available for several different

Siemens models (eg, PRISMA, Trio, and Skyra); expansion to other vendors is an ongoing project. The data can then be sent to a centralized server for processing. Because it is web-based, BrICS can be used by multiple users and institutions without the need for additional software, data, or processing. BrICS was successfully used as the infrastructure for an ongoing multi-institutional clinical study assessing the feasibility of dose-escalated radiation guided by sMRI in patients with glioblastoma; to date, 18 patients have been treated on this protocol, and no toxicities have been observed. Thus, there is an urgent need for improved quantitative imaging biomarkers that can not only identify these regions but also be readily incorporated into clinical practice.

sMRI has been shown to delineate infiltrating tumor beyond standard MRI but has thus far been used in only retrospective analyses owing to the complexity of integrating it with clinical volumes, the requirement for an on-site MR spectroscopist to manually review spectra in individual voxel, and variability in acquisition and processing across institutions. A web platform such as BrICS provides solutions for these challenges by enabling centralized data storage and analysis, allowing clinicians from multiple institutions to use sMRI without the need for local experts or software. Users will always have the latest version of BrICS without needing to download additional software or data sets and can access BrICS from any computer browser. BrICS is currently being used in a multisite clinical study assessing the feasibility of sMRI guidance for RT and will continue to be developed as infrastructure for future consortium-level trials.

Supplemental Materials

Supplemental Video 1: <http://dx.doi.org/10.18383/j.tom.2018.00028.vid.01>

ACKNOWLEDGMENTS

We would like to thank the following people for their assistance in collecting and analyzing data: Dr. Peter Barker, Dr. Michal Povazan, Dr. Sarah Dupont, Mr. Michael Larche, Mr. Robert Smith, Ms. Samira Yeboah, and Ms. Sarah Basadre. This work is funded by NIH grants U01CA172027, R01CA214557, U01EB028145, and F30CA206291.

REFERENCES

1. Wen PY, Macdonald DR, Reardon DA, Cloughesy TF, Sorensen AG, Galanis E, De-groot J, Wick W, Gilbert MR, Lassman AB, Tsien C, Mikkelsen T, Wong ET, Chamberlain MC, Stupp R, Lamborn KR, Vogelbaum MA, van den Bent MJ, Chang SM. Updated response assessment criteria for high-grade gliomas: response assessment in neuro-oncology working group. *J Clin Oncol*. 2010;28:1963–1972.
2. Stupp R, Hegi ME, Gilbert MR. Chemoradiotherapy in malignant glioma: standard of care and future directions. *J Clin Oncol*. 2007;25:4127–4136.
3. Stupp R, Hegi ME, Mason WP, van den Bent MJ, Taphoorn MJ, Janzer RC, Ludwin SK, Allgeier A, Fisher B, Belanger K, Hau P, Brandes AA, Gijtenbeek J, Marosi C, Vecht CJ, Mokhtari K, Wesseling P, Villa S, Eisenhauer E, Gorlia T, Weller M, Lacombe D, Cairncross JG, Mirimanoff RO; European Organisation for Research and Treatment of Cancer Brain Tumour and Radiation Oncology Groups; National Cancer Institute of Canada Clinical Trials Group. Effects of radiotherapy with concomitant and adjuvant temozolomide versus radiotherapy alone on survival in glioblastoma in a randomised phase III study: 5-year analysis of the EORTC-NCIC trial. *Lancet Oncol*. 2009;10:459–466.
4. Stupp R, Mason WP, van den Bent MJ, Weller M, Fisher B, Taphoorn MJ, Belanger K, Brandes AA, Marosi C, Bogdahn U, Curschmann J, Janzer RC, Ludwin SK, Gorlia T, Allgeier A, Lacombe D, Cairncross JG, Eisenhauer E, Mirimanoff RO; European Organisation for Research and Treatment of Cancer Brain Tumor and Radiotherapy Groups; National Cancer Institute of Canada Clinical Trials Group. Radiotherapy plus concomitant and adjuvant temozolomide for glioblastoma. *N Engl J Med*. 2005;352:987–996.
5. Wernicke AG, Smith AW, Taube S, Mehta MP. Glioblastoma: radiation treatment margins, how small is large enough? *Pract Radiat Oncol*. 2016;6:298–305.
6. Tsuchiya K, Mizutani Y. Preliminary evaluation of fluid-attenuated inversion-recovery MR in the diagnosis of intracranial tumors. *Am J Neuroradiol*. 1996;17:1081–1086.
7. Stupp R, Hegi ME, Gilbert MR, Chakravarti A. Chemoradiotherapy in malignant glioma: standard of care and future directions. *J Clin Oncol*. 2007;25:4127–4136.
8. Stupp R, Hegi ME, Mason WP, van den Bent MJ, Taphoorn MJB, Janzer RC, Ludwin SK, Allgeier A, Fisher B, Belanger K, Hau P, Brandes AA, Gijtenbeek J, Marosi C, Vecht CJ, Mokhtari K, Wesseling P, Villa S, Eisenhauer E, Gorlia T, Weller M, Lacombe D, Cairncross JG, Mirimanoff RO; European Organisation for Research and Treatment of Cancer Brain Tumour and Radiation Oncology Groups; National Cancer Institute of Canada Clinical Trials Group. Effects of radiotherapy with concomitant and adjuvant temozolomide versus radiotherapy

Disclosures: No disclosures to report.

Conflict of Interest: The authors have no conflict of interest to declare.

- alone on survival in glioblastoma in a randomised phase III study: 5-year analysis of the EORTC-NCIC trial. *Lancet Oncol.* 2009;10:459–466.
9. Stupp R, Taillibert S, Kanner AA, Kesari S, Steinberg DM, Toms SA, Taylor LP, Lieberman F, Silvani A, Fink KL, Barnett GH, Zhu JJ, Henson JW, Engelhard HH, Chen TC, Tran DD, Sroubek J, Tran ND, Hottinger AF, Landolfi J, Desai R, Caroli M, Kew Y, Honnorat J, Idbaih A, Kirson ED, Weinberg U, Palti Y, Hegi ME, Ram Z. Maintenance therapy with tumor-treating fields plus temozolomide vs temozolomide alone for glioblastoma: a randomized clinical trial. *JAMA.* 2015;314:2535–2543.
 10. Weller M, Cloughesy T, Perry JR, Wick W. Standards of care for treatment of recurrent glioblastoma—are we there yet? *Neuro Oncol.* 2013;15:4–27.
 11. Campos B, Olsen LR, Urup T, Poulsen HS. A comprehensive profile of recurrent glioblastoma. *Oncogene.* 2016;35:5819–5825.
 12. Fitzek MM, Thornton AF, Rabinov JD, Lev MH, Pardo FS, Munzenrider JE, Okunieff P, Bussièrè M, Braun I, Hochberg FH, Hedley-Whyte ET, Liebsch NJ, Harsh GR. Accelerated fractionated proton/photon irradiation to 90 cobalt gray equivalent for glioblastoma multiforme: results of a phase II prospective trial. *J Neurosurg.* 1999;91:251–260.
 13. Law M. MR spectroscopy of brain tumors. *Top Magn Reson Imaging.* 2004;15:291–313.
 14. Maudsley AA, Domenig C, Sheriff S. Reproducibility of serial whole-brain MR Spectroscopic Imaging. *NMR Biomed.* 2010;23:251–256.
 15. Law M, Cha S, Knopp EA, Johnson G, Arnett J, Litt AW. High-grade gliomas and solitary metastases: differentiation by using perfusion and proton spectroscopic MR imaging. *Radiology.* 2002;222:715–721.
 16. Cordova JS, Shu H-KG, Liang Z, Gurbani SS, Cooper LAD, Holder CA, Olson JJ, Kairdolf B, Schreiber E, Neill SG, Hadjipanayis CG, Shim H. Whole-brain spectroscopic MRI biomarkers identify infiltrating margins in glioblastoma patients. *Neuro Oncol.* 2016;18:1180–1189.
 17. Cordova JS, Gurbani SS, Olson JJ, Liang Z, Cooper LAD, Shu H-KG, Schreiber E, Neill SG, Hadjipanayis CG, Holder CA, Shim H. A systematic pipeline for the objective comparison of whole-brain spectroscopic MRI with histology in biopsy specimens from grade III glioma. *Tomography.* 2016;2:106–116.
 18. Cordova JS, Kandula S, Gurbani S, Zhong J, Tejani M, Kayode O, Patel K, Prabhu R, Schreiber E, Crocker I, Holder CA, Shim H, Shu HK. Simulating the effect of spectroscopic MRI as a metric for radiation therapy planning in patients with glioblastoma. *Tomography.* 2016;2:366–373.
 19. Gurbani SS, Schreiber E, Sheriff S, Cooper LAD, Shu H-KG, Holder CA, Maudsley AA, Shim H. A software platform for collaborative radiation therapy planning using spectroscopic MRI. *Int J Radiat Oncol Biol Phys.* 2017;99:E667.
 20. Sanderson C, Curtin R. Armadillo: a template-based C++ library for linear algebra. *J Open Source Softw.* 2016;1:26.
 21. Yoo TS, Ackerman MJ, Lorensen WE, Schroeder W, Chalana V, Aylward S, Metaxas D, Whitaker R. Engineering and algorithm design for an image processing API: a technical report on ITK—the insight toolkit. *Stud Health Technol Inform.* 2002;85:586–92.
 22. Maudsley AA, Domenig C, Govind V, Darkazanli A, Studholme C, Arheart K, Bloomer C. Mapping of brain metabolite distributions by volumetric proton MR spectroscopic imaging (MRSI). *Magn Reson Med.* 2009;61:548–559.
 23. McKnight TR, von dem Bussche MH, Vigneron DB, Lu Y, Berger MS, McDermott MW, Dillon WP, Graves EE, Pirzkall A, Nelson SJ. Histopathological validation of a three-dimensional magnetic resonance spectroscopy index as a predictor of tumor presence. *J Neurosurg.* 2002;97:794–802.
 24. Engwer C, Hillen T, Knappitsch M, Surulescu C. Glioma follow white matter tracts: a multiscale DTI-based model. *J Math Biol.* 2015;71:551–582.
 25. Gurbani SS, Schreiber E, Sheriff S, Holder CA, Cooper LAD, Maudsley A, et al. editors. Rapid internal normalization of spectroscopic MRI maps using a gaussian mixture model. In *Proceedings of the American Association of Physicists in Medicine 59th Annual Meeting*; Denver, CO; 2017.
 26. Maudsley AA, Domenig C. Signal normalization for MR spectroscopic imaging using an interleaved water-reference. In *Proceedings of the 16th Annual Meeting of ISMRM*; Toronto, ON; 2008.
 27. Keles GE, Chang EF, Lamborn KR, Tihan T, Chang C-J, Chang SM, Berger MS. Volumetric extent of resection and residual contrast enhancement on initial surgery as predictors of outcome in adult patients with hemispheric anaplastic astrocytoma. *J Neurosurg.* 2006;105:34–40.
 28. Kurita T, Otsu N. Texture Classification by Higher Order Local Autocorrelation. In *Proceedings of the Asian Conference on Computer Vision*; Osaka, Japan; 1993.
 29. Cordova JS, Schreiber E, Hadjipanayis CG, Guo Y, Shu H-KG, Shim H, Holder CA. Quantitative tumor segmentation for evaluation of extent of glioblastoma resection to facilitate multisite clinical trials. *Transl Oncol.* 2014;7:40–47.
 30. Sabati M, Sheriff S, Gu M, Wei J, Zhu H, Barker PB, Spielman DM, Alger JR, Maudsley AA. Multivendor implementation and comparison of volumetric whole-brain echo-planar MR spectroscopic imaging. *Magn Reson Med.* 2015;74:1209–1220.
 31. RTOG. Randomized phase II trial of hypofractionated dose-escalated photon IMRT or proton beam therapy versus conventional photon irradiation with concomitant and adjuvant temozolomide in patients with newly diagnosed glioblastoma. *Radiat Ther Oncol Gr NRG-BN001 Protoc Inf.* 2014.
 32. Gurbani SS, Schreiber E, Maudsley AA, Cordova JS, Soher BJ, Poptani H, Verma G, Barker PB, Shim H, Cooper LAD. A convolutional neural network to filter artifacts in spectroscopic MRI. *Magn Reson Med.* 2018;80:1765–1775.