



Received for publication: February 26, 2019  
Accepted: May 22, 2019

## Research article

# Can intraoperative manometry influence the outcome of the surgical treatment of achalasia?

Lucian Alecu<sup>1</sup>, Iulian Slavu<sup>2</sup>, Adrian Tulin<sup>1</sup>, Daniela Mihaila<sup>1</sup>, Robert Ivascu<sup>3</sup>, Liliana Mirea<sup>4</sup>

<sup>1</sup>Agrippa Ionescu Clinical Emergency Hospital, Department of General Surgery, Bucharest, Romania

<sup>2</sup>Clinical Emergency Hospital Bucharest, Department of General Surgery, Bucharest, Romania

<sup>3</sup>Elias University Emergency Hospital, The Anesthesiology and Critical Care Unit, Bucharest, Romania

<sup>4</sup>Carol Davila University of Medicine and Pharmacy, The Emergency Hospital of Bucharest, Romania

### Abstract

*Introduction.* Achalasia is defined as incomplete or even absent relaxation of the lower esophageal sphincter secondary to the chronic degeneration of unspecified etiology of the myenteric nerve plexus. *Material and method.* The retrospective study extended over 1 year. The collected variables were: age, sex, type of surgical intervention, intraoperative manometry results, and postoperative complications. *Results.* We identified 8 patients. The mean operative time was 100 minutes. The use of manometry determined an increase in time of 30 to 40 minutes. Manometry was successfully achieved in all cases, although in one case the sensor could not pass through the lower esophagus, so a prior pneumatic dilation was required. Manometry has proven useful during fundoplication as it offers a direct view of the pressure produced when knots set at 12 - 15 mmHg with a length of 4-5 cm were tightened. Of the 8 patients, 6 required an increase in the length of the resection of the esophagus after the results of the intraoperative manometry were reviewed. *Conclusion.* In our opinion, after reviewing our experience and the literature data, intraoperative manometry should become a standard procedure in the laparoscopic treatment of achalasia.

**Keywords** : manometry, achalasia, myotomy, surgical treatment

**Highlights**

- ✓ The use of manometry in the treatment of achalasia seems to be convincing.
- ✓ Although the expense is higher, it is still less than having to reoperate on a patient due to persistent symptoms.

**To cite this article:** Alecu L, Slavu I, Tulin A, Mihaila D, Ivascu R, Mirea L. Can intraoperative manometry influence the outcome of the surgical treatment of achalasia? *J Mind Med Sci.* 2019; 6(2): 346-350. DOI: 10.22543/7674.62.P346350

## Introduction

Achalasia is defined as incomplete or even absent relaxation of the lower esophageal sphincter secondary to the chronic degeneration of unspecified etiology of the myenteric nerve plexus (1). The global incidence is 1.6 per 100,000 inhabitants. If left undiagnosed and untreated, in time, it can lead to increased rates of esophageal cancer, simultaneously decreasing the patient's quality of life due to dysphagia (2).

The diagnostic method of choice for this pathology is esophageal manometry and endoscopy. The gold treatment involves surgical resection of the circular muscle fibers which form the inferior esophageal sphincter through the technique of Heller myotomy, first described over 100 years ago when it was first practiced through a transthoracic approach (2).

This procedure has undergone multiple changes since then and, at present, can be successfully performed through a laparoscopic approach, completed through a partial Dor (anterior) or Toupet (posterior) fundoplication. Another option is to perform a Nissen fundoplication on 360% to protect the exposed submucosal portion of the esophagus and to prevent any reflux disease, since the inferior esophageal sphincter is partially redone. Although the procedure has a success rate of up to 90% in symptom relief, 10% of the patients complain about the persistence of symptoms, most often due to the incomplete resection of the circular muscle fibers at the level of the esogastric junction. Macroscopically, an exact approximation of the resection length of these fibers is difficult to assess. The universal recommendation nowadays is 10-11 cm, of which 6-7 cm are in the esophagus and 4 cm in the stomach (3). However, recent studies have demonstrated that a 5-cm length is sufficient for symptom relief if the resection location is correctly noted (3).

Recent studies have reported that myomectomy at the level of the lower esophagus is responsible for reducing the pressure values to 0 and allows for a complete improvement of the symptoms. Therefore, other direct methods presumably reflect the impact that real-time surgery has on the degree of relaxation of the lower esophageal sphincter.

Intraoperative manometry may provide such real-time information, allowing the surgeon to adapt the technique according to the real-time results provided on each patient, customizing the location and extent of the resection of these circular muscle fibers, and thus discarding the notion of one size fits all (10-11cm of resection). This study aimed to evaluate the real-time changes in the lower esophageal sphincter induced by real-time esocardiomyotomy observed through manometry based on our preliminary experience.

## Materials and Methods

This retrospective analysis was conducted at a single institution. Data were collected over 1 year (01.01.2018-01.01.2019) and included: age, sex, type of surgical intervention, intraoperative manometry results, and postoperative complications. Data were retrieved from "Agrippa Ionescu" Clinical Emergency Hospital, Bucharest, Romania.

We identified 8 qualifying patients during the selected time period. All had been diagnosed with achalasia and were operated on through a laparoscopic approach. The length of myotomy varied with each patient as indicated by the pressure areas confirmed with the aid of intraoperative manometry. All surgical interventions were completed through an anterior Dor fundoplication. The Dor fundoplication allows the sides of myotomy to remain separated, thus obtaining a good anti-reflux mechanism. As the stomach was tightened around the esophagus, the pressures were recorded and the technique adopted. A ten-lumen probe with a 10 mm diameter was used. The catheter was marked to constantly evaluate its position regarding the depth and angle of rotation with respect to the pressure sensors. The sensors which recorded the pressure waves were placed circumferentially in order to obtain a 3D image of the pressures produced by the lower esophageal sensor.

## Results

We identified 8 patients (5 females and 3 males) laparoscopically operated on for achalasia using the aforementioned technique. All patients were diagnosed by means of endoscopy and manometry, and the mean operative time was 100 minutes. The use of manometry resulted in an increase in time of 30 to 40 minutes during the first 4 cases, followed by a decrease in time to around 20 minutes/per case. No deaths or conversions to open surgery were recorded. One patient had a perforation which was diagnosed through the intraoperative administration of methylene blue. The mucosa was sutured and the postoperative evolution was uneventful (conversion was not required). The average hospital stay was 4 days. All patients had been inserted with a nasogastric tube which was removed 1 day after surgery when fluids were administered. The existence of a perforation in all patients was verified with methylene blue after myotomy.

Manometry was successfully achieved in all cases, although in one case the sensor could not pass through the lower esophagus, so a prior pneumatic dilation was required. The pressure sensor had to pass several times to obtain an ideal myotomy (0 pressure at the level of the esogastric junction) (Figure 1, 2).

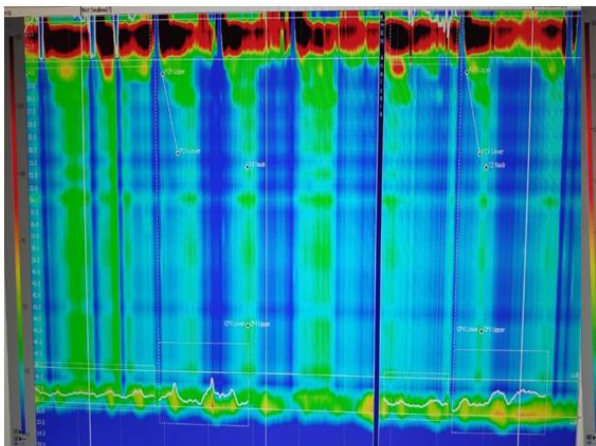


Figure 1. Type II achalasia-before myotomy

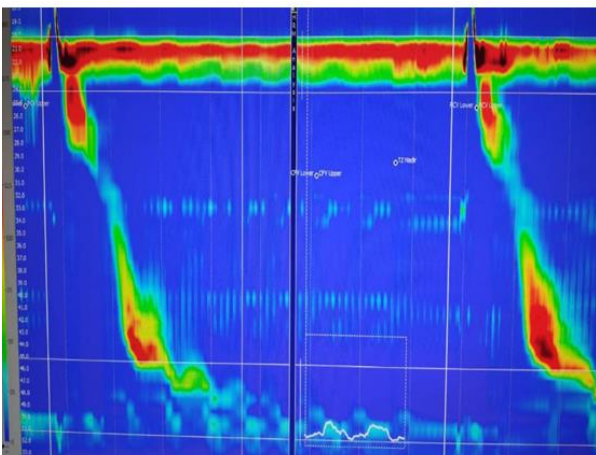


Figure 2. Manometry after myotomy of the same patient

Accordingly, good communication between the gastroenterologist and the surgeon is essential. The sensitivity of the pressure sensor was extremely high as it could identify an increase in the pressure produced by individual circular muscle fibers. Manometry has proven useful during fundoplication as it can offer a direct view of the pressure produced when knots were tightened, which was set at 12 - 15 mmHg with a length of 4-5 cm, as demonstrated in Figure 3.

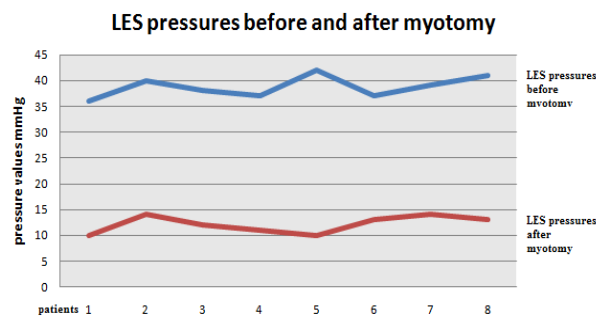


Figure 3. LES pressures before and after myotomy

Of the 8 patients, 6 required an increase in the length of the resection, usually on the esophagus after the results of the intraoperative manometry were reviewed (Figure 4).

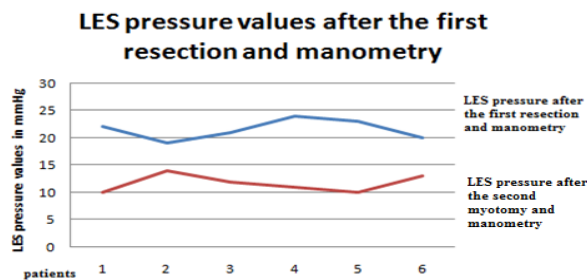


Figure 4. LES values after the first resection + manometry and the second resection + manometry

## Discussions

Twenty-four years have passed since one of the first studies published by Taniguchi et al. used manometry in the surgical treatment of achalasia. That study concluded that manometry was a useful tool to correctly calibrate the pressure areas in the lower esophagus. Despite this, wide acceptance of this procedure has thus far not occurred, as it is used only at specific centers, and the research literature lacks high quality large, prospective randomized trials (4).

Heller esocardiomy together with a form of fundoplication (partial fundoplication - Dor or Toupet or 360 degrees Nissen) is currently the standard treatment for achalasia (5). Dor or Toupet partial fundoplication is preferred over 360-degree Nissen fundoplication, which is associated with high rates of dysphagia (5). Given this difference, our clinic has exclusively used the Dor fundoplication with extremely favorable results (6).

The pressure area at the level of the lower esophageal sphincter responsible for the gastric contention resulting from fundoplication is recommended to have a length of about 4 cm (7). Within the fundoplication, the tension that closes the esogastric junction and prevents the reflux is given by the two sutures, which is why it is not recommended to resect the short gastric vessels, as this action translates into a decreased relaxation of the esogastric junction of up to 10mmHg, far exceeding the accepted values (7). However, up to 10% of patients continue to exhibit persistent symptomatology during the postoperative period after Heller myotomy (8).

To assist these patients, techniques have been developed for the direct intraoperative monitoring of the impact of myotomy on the lower esophageal sphincter pressure. These techniques are represented by intraoperative manometry and intraoperative esophageal volumetry (8). The inclusion of manometry in the standard treatment arsenal can lead to a 95% success rate of the surgical intervention (9).

In the studied group, of the 8 patients who required surgery, the extensive resection of muscle fibers was

performed in 6 cases following the visualization of the manometry results. Incomplete resection of the muscle fibers in the lower esophageal sphincter will lead to a recurrence of dysphagia that will eventually require surgical reintervention. A series of cases published by Clemente et al. demonstrated the persistence of high pressures at the level of the esogastric junction confirmed manometrically although, from the laparoscopic and endoscopic point of view, the intervention was considered a success (10).

The persistence of the symptomatology is most often due to the incomplete resection of the esophageal and gastric (more commonly esophageal) muscle fibers. So, close attention to this region should be standard (11-13). Leaving in place even a single circular muscle bundle is sufficient to produce an increase in the pressure at the level of the lower esophageal sphincter, thus demonstrating the usefulness of manometry (14). Bearing these aspects in mind, myomectomy must be efficient and extended even on the lateral edges of the esophagus. In our clinic, we dissect the esophagus until we achieve a mucosal exposure on an area of at least 50% of the diameter of the esophagus (15, 16).

The utility of intraoperative manometry has also been confirmed by Endo et al. and Chapman et al., who reported a reduction in clinical symptomatology in the postoperative period compared to the groups in which no manometry was performed (16, 17).

## Conclusions

Although this study is limited by its reduced dimensions, the results regarding the use of manometry in the treatment of achalasia is convincing. This technology has only been used for 1.5 years in our institution, but the efficiency with which it can identify the pressure areas produced by even one muscle fiber has made it standard practice in the treatment of achalasia. Although the expense is higher, it is still less than having to reoperate on a patient due to persistent symptoms.

Excellent communication between surgeon and gastroenterologist is of utmost importance in order to achieve optimal results. Furthermore, the increased operative time required in the first cases decreases with experience. In our opinion, after reviewing our experience and the research literature, the use of manometry should become a standard practice in the laparoscopic treatment of achalasia.

## Conflict of interest disclosure

There are no known conflicts of interest in the publication of this article. The manuscript was read and approved by all authors.

## Compliance with ethical standards

Any aspect of the work covered in this manuscript has been conducted with the ethical approval of all relevant bodies and that such approvals are acknowledged within the manuscript.

## References

1. Boeckstaens G E, Zaninotto G, Richter J E. Achalasia. *Lancet*. 2014; 383: 83–93.
2. Heller E. Extramuköse Kardioplastik beim chronischen Kardiospasmus mit dilatation des oesophagus. *Mit Grenzgeb Med Chir*. 1913; 27: 141–9.
3. Ilcyszyn A, Hamaoui K, Cartwright J, Botha A. Botha I Intraoperative distensibility measurement during laparoscopic Heller's myotomy for achalasia may reduce the myotomy length without compromising patient outcome. *Dis Esophagus*. 2016; 29(5): 455-62. DOI: 10.1111/dote.12343
4. Taniguchi E, Kamiike W, Iwase K, Nishida T, Miyata M, Inoue M, Ohashi S, Okada T, Matsuda H. Laparoscopic extramucosal myectomy with anterior fundoplication (Dor) for esophageal achalasia using intraoperative manometry. *Surg Endosc*. 1995; 9(7): 817-819.
5. Possati L, Bragaglia RB, Mattioli S. In: Stipa S, Belsey RHR, Moraldi A, Results of the surgical management of achalasia. Medical and surgical problems of the esophagus. London: Academic Press; 1981. p. 281-3.
6. Campos GM, Vittinghoff E, Rabl C, et al. Endoscopic and surgical treatments for achalasia: a systematic review and metaanalysis. *Ann Surg*. 2009; 249: 45–57.
7. Mattioli S, Ruffato A, Lugaresi M, Pilotti V, Aramini B, D'Ovidio F. Long-term results of the Heller–Dor operation with intraoperative manometry for the treatment of esophageal achalasia. *J Thorac Cardiovasc Surg*. 2010; 140(5): 962-9. DOI: 10.1016/j.jtcvs.2010.07.053.
8. Pandolfino JE, Gawron AJ. Achalasia: a systematic review. *JAMA*. 2015; 313(18): 1841–1852.
9. Campos GM, Vittinghoff E, Rabl C, et al. Endoscopic and surgical treatments for achalasia: a systematic review and meta-analysis. *Ann Surg*. 2009; 249(1): 45–57.

10. Khan M, Smythe A, Elghellal K, et al. Can intraoperative manometry during laparoscopic fundoplication predict postoperative dysphagia? *Surg Endosc.* 2010; 24: 2268–2272.
11. Clemente G, D'Ugo D, Granone P, et al. Intraoperative esophageal manometry in surgical treatment of achalasia: a reappraisal. *Hepatogastroenterology* 1996; 43(12): 1532-6.
12. Mattioli S, Pilotti V, Felice V, et al. Intraoperative study on the relationship between the lower esophageal sphincter pressure and the muscular components of the gastro-esophageal junction in achalasic patients. *Ann Surg.* 1993; 218(5): 635-9.
13. Bolocan A, Paduraru DN, Nitipir C, et al. Mixed adenoneuroendocrine carcinoma of the gastrointestinal tract-features, diagnosis, management and prognostics. *Romanian Biotechnological Letters.* 2018; 23(6): 14193-14202.
14. Hainarosie R, Zainea V, Pantea Stoian AM, et al. Prevention of the medico-legal implications of surgical fire in laryngeal CO<sub>2</sub> laser surgery. *Romanian Journal of Legal Medicine.* 2018; 26(2): 188-191.
15. Popa CC, Badiu DC, Andronache LF, et al. Differential Diagnosis in Esophageal Cancer Review on literature. *Rev Chim. (Bucharest).* 2019; 70(1): 331-335.
16. Ardeleanu V, Chebac GR, Georgescu C, et al. The modifications suffered by the peri-esophageal anatomical structures in the hiatal hernia disease: a qualitative and quantitative microanatomic study. *Romanian journal of morphology and embryology.* 2010; 51(4): 765-770.
17. Chapman JR, Joehl RJ, Murayama KM, et al. Achalasia treatment: improved outcome of laparoscopic myotomy with operative manometry. *Arch Surg.* 2004; 139: 508–513.
18. Endo S, Nakajima K, Nishikawa K, et al. Laparoscopic Heller-Dor surgery for esophageal achalasia: impact of intraoperative real-time manometric feedback on postoperative outcomes. *Dig Surg.* 2009; 26: 342–348.