







Review

Full-Digital Customized Meshes in Guided Bone Regeneration Procedures: A Scoping Review

Andrea Scribante ¹, Martina Ghizzoni ¹, Matteo Pellegrini ^{2,3,*}, Federica Pulicari ^{2,3},
Mattia Manfredini ^{2,3,*}, Pier Paolo Poli ^{2,3}, Carlo Maiorana ^{2,3} and Francesco Spadari ^{2,3}

¹ Section of Dentistry, Department of Clinical, Surgical, Diagnostic and Pediatric Sciences, University of Pavia, 27100 Pavia, Italy; andrea.scribante@unipv.it (A.S.); martina.ghizzoni01@universitadipavia.it (M.G.)

² Maxillofacial Surgery and Dental Unit, Fondazione IRCCS Cà Granda Ospedale Maggiore Policlinico, 20122 Milan, Italy; federica.pulicari@studenti.unimi.it (F.P.); pierpaolo.poli@unimi.it (P.P.P.); carlo.maiorana@unimi.it (C.M.); francesco.spadari@unimi.it (F.S.)

³ Department of Biomedical, Surgical and Dental Sciences, University of Milan, Via della Commenda 10, 20122 Milan, Italy

* Correspondence: matteo.pellegrini@unimi.it (M.P.); mattia.manfredini@unimi.it (M.M.)

Abstract: Meshes, especially titanium ones, are being widely applied in oral surgery. In guided bone regeneration (GBR) procedures, their use is often paired with membranes, being resorbable or non-resorbable. However, they present some limitations, such as difficulty in the treatment of severe bone defects, alongside frequent mesh exposure. Customized meshes, produced by a full-digital process, have been recently introduced in GBR procedures. Therefore, the focus of the present review is to describe the main findings in recent years of clinical trials regarding patient-specific mesh produced by CAD/CAM and 3D printing workflow, made in titanium or even PEEK, applied to GBR surgeries. The purpose is to analyze their clinical management, advantages, and complications. This scoping review considered randomized clinical trials, observational studies, cohort studies, and case series/case reports studies. Studies that did not meet inclusion criteria were excluded. The preferred reporting items for scoping reviews (PRISMA-ScR) consensus was followed. A total of 15 studies were selected for this review. Based on the studies included, the literature suggests that meshes produced by a digital process are used to restore complex and severe bone defects. Moreover, they give satisfactory aesthetic results and fit the defects, counteracting grid exposure. However, more clinical trials should be conducted to evaluate long-term results, the rate of complications, and new materials for mesh manufacturing.

Keywords: CAD/CAM; customized mesh; dentistry; digital workflow; GBR; guided bone regeneration; oral surgery; PEEK; titanium mesh; 3D printing



Citation: Scribante, A.; Ghizzoni, M.; Pellegrini, M.; Pulicari, F.; Manfredini, M.; Poli, P.P.; Maiorana, C.; Spadari, F. Full-Digital Customized Meshes in Guided Bone Regeneration Procedures: A Scoping Review. *Prosthesis* **2023**, *5*, 480–495. <https://doi.org/10.3390/prosthesis5020033>

Academic Editor: Bruno Chrcanovic

Received: 28 April 2023

Revised: 14 May 2023

Accepted: 16 May 2023

Published: 18 May 2023



Copyright: © 2023 by the authors. Licensee MDPI, Basel, Switzerland. This article is an open access article distributed under the terms and conditions of the Creative Commons Attribution (CC BY) license (<https://creativecommons.org/licenses/by/4.0/>).

1. Introduction

The alveolar bone undergoes two successive processes after extraction or loss of a dental element: resorption and atrophy. This leads to a reduction in the alveolar ridge in the first six months in the horizontal dimension and then in the vertical dimension. Therefore, the bone is often inadequate for implant placement [1,2].

The guided bone regeneration (GBR) procedure, due to its numerous advantages, such as osteogenic stability and multidirectional osteogenesis capability, appears to be one of the most used and reliable techniques to restore bone deficits in height and/or width in association with implant treatment [3,4].

Currently, the GBR technique involves the employment of membranes, resorbable or non-resorbable, combined with bone substitute materials, depending on bone defect features [5].

Bone grafts, membranes, and biological materials have been tested for their regenerative characteristics for intrabony defect treatment, as well as furcation defects, peri-implantitis sites, alveolar ridge preservation, and implant site development [6–9].

Throughout the GBR procedure, osteoblasts can favorably and selectively enter the site of the defect to stimulate and regenerate the affected bone. Indeed, barrier membranes have the purpose of inhibiting early epithelial and connective cells' colonization of the area, while bone-filling materials direct and control osteoblastic progenitor cells' proliferation and differentiation [5,10].

Thanks to their excellent mechanical properties, titanium meshes are broadly used in the surgical field. Stiffness and strength help the osteogenesis process, stability permits bone-filling materials to maintain their volume during healing, and elasticity may decrease oral mucosa's compression [11,12].

Bone-augmentation techniques that require titanium mesh and implant placement can occur synchronically or delayed, as well as GBR with other bone-grafting techniques [11,13–16].

When using surgical meshes, the main complication is wound dehiscence and subsequent mesh exposure during the healing process. Mesh exposure can be classified as early exposure occurring within 4 weeks post-surgery and delayed mesh exposure occurring after 4 weeks post-surgery. Early dehiscence manifestation is related to a reduction in new bone formation and synchronic increment in fibrous tissue; when this event occurs, the grid should be quickly eliminated, and disinfection procedures carried out [17,18]. On the other hand, late mesh exposure could potentially create substitute materials' resorption, leading to a decrease in bone dimension and inadequate quantity. However, the mesh can be left in place, as disinfection with chlorhexidine, plaque management, and smoothing of the sharp edges could solve the problem without alterations in the process of bone regeneration [19–21].

Standardized meshes are products with pre-determined characteristics such as thickness and width; hence they must be manually modeled to adapt to the alveolar ridge of the specific patient. This procedure presents many drawbacks, such as longer surgery, imprecise fitting, infection, pain, flap laceration, and possible future mesh exposure [22–24].

Therefore, recent clinical research has focused more on customized titanium mesh, thanks to the latest digitalization trends and technologies available on the market (Figure 1). Pre-operative cross-sectional imaging (cone beam computed tomography-CBCT) and 3D digital models have to be collected; thus, the patient's alveolar ridge can be virtually reconstructed with CAD technology [25].

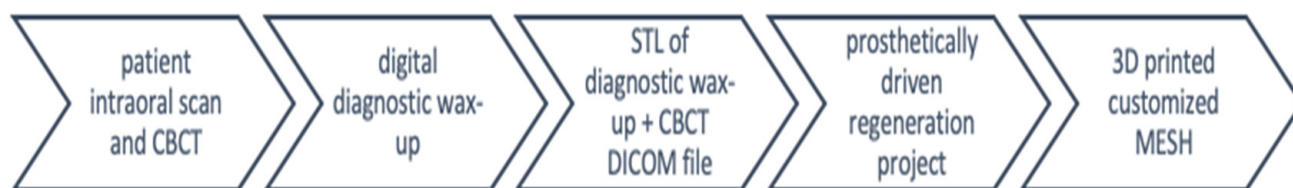

Figure 1. Full-digital customized mesh—summary diagram of the process.

Custom-made titanium mesh can be produced with different protocols: CAD/CAM-3D printing or mesh-preforming on patients' 3D jaws models [26,27].

Personalized meshes showed numerous advantages, such as quicker surgery, tailored fitting, less retention used to pin the mesh, smoother edges, and subsequent mucosal stress reduction [11,28].

In the last decade, research has concentrated on customized mesh applications in the surgical field. Therefore, this review aims to analyze the recent literature concerning full-digital customized mesh applied to guided bone regeneration in oral surgery, their clinical aspects and management (complex bone defects, aesthetic outcomes, bone regeneration rates), and future perspectives.

2. Materials and Methods

2.1. Focused Questions

Do full-digital customized mesh in GBR surgeries provide clinical advantages? Are they useful for treating bone defects and giving satisfactory aesthetic results?

2.2. Eligibility Criteria

The inclusion criteria guiding this review were: (I) study model—interventional studies, observational studies, cohort studies, case series/case reports studies; (II) patients with bone defects undergoing GBR; (III) interventions—guided bone regeneration with digitally custom-made mesh; and (IV) outcome—clinical results for customized mesh produced with a fully digital process. Exclusively studies that adhere to all the inclusion criteria were examined. Regarding exclusion criteria, the following were considered: (I) abstract of articles published in non-English languages; (II) duplicate studies; (III) irrelevant studies (full-text articles purpose not appropriate to answer the focused questions, analysis of different supplementary treatments, and full-text content not corresponding to abstract); (IV) *ex vivo* or experimental animal studies; (V) absence of Ethics Committee approval; and (VI) narrative reviews, systematic reviews, or systematic and meta-analysis reviews.

2.3. Search Strategy

According to the JBI methodology for scoping review, a three-step searching process was performed: (i) preliminary limited search on PubMed (MEDLINE) and Scopus; (ii) key terms selection from retrieved articles for devising search strategy; and (iii) reference list search of all included articles for additional research [29].

Additionally, the PCC model was applied, which is based on the following three elements: population (people undergoing GBR procedures), concept (full-digital customized meshes), and context (in this regard, the review has not been circumscribed to any specific cultural element or setting). Studies' abstracts that analyzed the effects of digitally customized mesh in GBR procedures and their clinical outcomes were reviewed. During this scoping review of the literature, the preferred reporting items for scoping reviews (PRISMA-ScR) consensus was followed (Table S1 Supplementary Material) [30].

2.4. Research

The medical subject heading (MeSH) terms are bone regeneration, computer-aided design and manufacturing, digital technology, guided tissue regeneration, surgical mesh, and 3D printing; an electronic search was performed with PubMed (MEDLINE) and Scopus databases. The articles published in the years 2010 to 2023 were selected. The data extraction period was between November 2022 and April 2023. The last search was performed on 24 April 2023. Four calibrated reviewers (M.G., M.P., F.P., and M.M.) conducted the search. Disagreements and discrepancies were resolved by consensus, and four other reviewers were consulted (A.S., C.M., F.S., and P.P.P.). All the titles and abstracts were analyzed carefully from the articles searched first, and non-relevant studies were not included. All relevant articles were reviewed and scrutinized by analyzing full texts, documenting the findings, and recognizing any similar studies that matched the inclusion criteria selected.

The present protocol has been registered within the Open Science Framework platform (Registration DOI-10.17605/OSF.IO/VRDF6).

The elaborated strategies applied for each electronic database are exhibited in Table S2 (Supplementary Material).

2.5. Quality Assessment of Included Studies

This review was performed by evaluating the risk of bias by conducting a qualitative analysis of the clinical studies via the National Heart, Lung, and Blood Institute (NHLBI) Quality Assessment of Controlled Intervention Studies for Observational Cohort and Cross-Sectional Studies [31].

3. Results

The primary search identified 143 articles based on MeSH terms. Following this, 117 articles were removed (13 abstracts of articles published in non-English languages, 198 duplicates, 68 in vitro or animal clinical studies, 114 because they were not pertinent, and 9 because of the absence of Ethics Committee approval), and 26 articles were screened based on title and abstracts. The remaining 15 full-text articles were assessed for eligibility. Additionally, 11 full-text articles were further excluded because they were irrelevant articles. The 15 relevant articles were finally included and analyzed in this review. The flowchart of the review process is described in Figure 2.

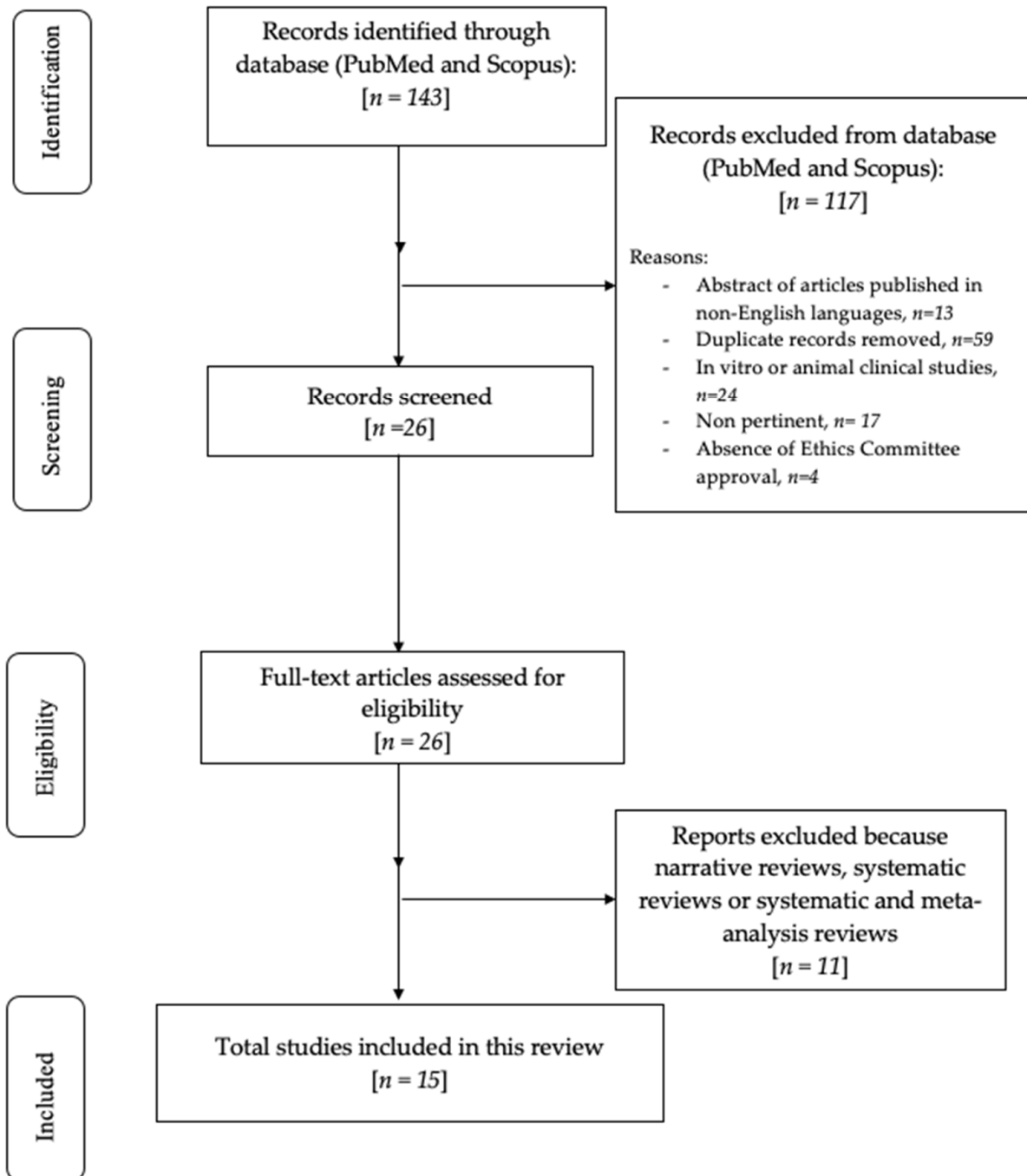


Figure 2. Flowchart of the review process.

Table S3 (Supplementary Materials) shows the studies excluded from this review and the reasons for exclusion [32–42].

The studies were from four categories: controlled intervention studies [43,44], before–after (Pre–Post) studies with no control group [45], observational cohort studies [46–51], and case series/case report studies [52–57].

Risk of Bias

The Cochrane Collaboration tool was applied to assess the risk of bias in the articles included in this review (Table 1), using the judging criteria for risk of bias shown in Table S4 (Supplementary Materials). A moderate risk of bias was observed in this review.

Table 1. Risk of bias of the studies included in this review: the green symbol represents a low risk of bias, while the yellow symbol represents a high risk of bias.

	Random Sequence Generation	Allocation Concealment	Blinding	Incomplete Outcome Data	Selective Reporting
Cucchi et al., 2021 [43]					
Mounir et al., 2019 [44]					
Cucchi et al., 2022 [45]					
Lizio et al., 2022 [46]					
Dellavia et al., 2021 [47]					
Ciocca et al., 2018 [48]					
Chiapasco 2021 [49]					
Navarro Cuellar 2021 [50]					
Yang et al., 2022 [51]					
Ghanaati et al., 2019 [52]					
Boogaard et al., 2019 [53]					

Table 1. Cont.

	Random Sequence Generation	Allocation Concealment	Blinding	Incomplete Outcome Data	Selective Reporting
Nickenig et al., 2022 [54]					
De Santis et al., 2022 [55]					
Geletu et al., 2022 [56]					
Tallarico et al., 2020 [57]					

Table 2 shows the baseline characteristics of patients included in the selected studies. Evidence of studies included in this review (study design and aim, methods, results, and conclusions) is shown in Table S5 (Supplementary Materials).

Table 2. Baseline characteristics of patients included in the selected studies.

References (Authors, Year of Publication, and Study Design)	N° of Patients and % Women	Mean Age (Years), Mean (SD or Range)	Inclusion and Exclusion Criteria	Clinical Outcome
Cucchi et al., 2021 [43]: randomized controlled clinical trial	Group 1: 15 W: 53.3% Group 2: 15 W: 46.7%	N.R.	Inclusion criteria: partial edentulism of upper maxilla or mandible with vertical and horizontal bone resorption of the alveolar ridge requiring three-dimensional bone regeneration for prosthetically guided implant placement and capacity to understand and accept the written conditions of the study. Exclusion criteria: insufficient oral hygiene; smoking habit of >10 cigarettes/day; abuse of alcohol or drugs; pregnancy, acute local or systemic infections; uncontrolled diabetes or other metabolic diseases; severe hepatic or renal dysfunction; autoimmune disorders; patients who underwent radiotherapy in the last 5 years and patients undergoing immunosuppressive therapy or immunocompromised patients.	Complex bone defects
Mounir et al., 2019 [44]: randomized controlled clinical trial	Group 1: 8 W: 25% Group 2: 8 W: 50%	Group 1: 38 Group 2: 39	Inclusion criteria: patients who had a partial or completely edentulous maxillary alveolar ridge with apparent 3D defect following teeth loss. The ridge had to exhibit severe vertical and horizontal (3D) alveolar ridge deficiency with alveolar ridge height less than 6 mm from the alveolar crest to the basal bone and a ridge width of less than 2 mm or a clinically apparent increase in inter-arch space relative to the adjacent natural teeth. Exclusion criteria: N.R.	Complex bone defects
Cucchi et al., 2022 [45]: preliminary clinical trial	10 W: 50%	54	Inclusion criteria: age > 18 years; partial edentulism of the maxilla or mandible; VBD requiring 3D bone augmentation for prosthetically guided implant placement; informed consent for experimental treatment and processing of personal data. Exclusion criteria: poor oral hygiene; untreated periodontal disease; smoking > 10 cigarettes per day; abuse of alcohol or drugs; pregnancy; presence of odontostomatological and/or systemic infections; metabolic, liver, kidney, or autoimmune disease; radiotherapy in the head and neck region in the last 5 years; patients undergoing immunosuppressive therapy and/or immunocompromised patients.	Optimal bone regeneration: 90%

Table 2. Cont.

References (Authors, Year of Publication, and Study Design)	N° of Patients and % Women	Mean Age (Years), Mean (SD or Range)	Inclusion and Exclusion Criteria	Clinical Outcome
Lizio et al., 2022 [46]: retrospective clinical study	17 W: 70.6%	55.9 ± 13.7	Inclusion criteria: the absence of any systemic or local contraindication to surgical treatment: acute or chronic infections in the head and neck; smoking > 10 cigarettes per day; uncontrolled diabetes; a history of radiation therapy in the head or neck region; current anti-tumor chemotherapy; liver, blood, or kidney disease; immunosuppression; everyday corticosteroid use; pregnancy; inflammatory and autoimmune disease of the oral cavity; and poor oral hygiene and motivation. The specific conditions for intervention were the presence of maxillary or mandibular complex defects (with horizontal and vertical deficits in the same site), which was considered inadequate for the placement of at least two standard fixtures (≥6 mm long and ≥3.3 wide).	Optimal bone regeneration: 88%
Dellavia et al., 2021 [47]: retrospective cohort study	20 W: 75%	43–81	Inclusion criteria: age > 18 years, general good health conditions, adequate compliance both in terms of home oral hygiene maneuvers and in the ability to show up at the controls and to have completely understanding informed consent. Furthermore, in the posterior mandibular edentulous sites, they presented severe bone atrophy incompatible with placement of even short (≤6 mm) or narrow (<3 mm) implants in an appropriate and prosthetically guided position. Exclusion criteria: systemic diseases and conditions conflicting with GBR and implant placement: severe kidney and/or liver disease, congenital or acquired immunodeficiency, ongoing antineoplastic chemotherapy at the time of first examination, sequelae of radiotherapy in the head and neck area, smoking > 10 cigarettes per day, alcohol abuse, non-compensated diabetes, bisphosphonate chemotherapy in progress and pregnant women, patients with diseases of oral mucosa (lichen planus, FMPS, and FMBS > 20%, active periodontal disease)	Regeneration of vital, well-structured, and vascularized alveolar bone
Ciocca et al., 2018 [48]: preliminary prospective study	9 W: 66.7%	50 (25–68)	Inclusion criteria: N.R. Exclusion criteria: N.R.	High post-operative morbidity related to mesh exposure
Chiapasco 2021 [49]: retrospective clinical study	41 W: 75.6%	53.98 ± 14.32 (20–81)	Inclusion criteria: systemically healthy patients; a minimum age of 18 years; relevant or severe bone atrophy at the edentulous sites incompatible with placement of even short (≤6 mm) or narrow (<3 mm) implants in an appropriate and prosthetically guided position; adequate compliance of patients, both in terms of oral hygiene and respect the follow-up recalls; and ability to understand the proposed surgical treatment and to understand and sign the informed consent. Exclusion criteria: severe kidney and/or liver disease; congenital or acquired immunodeficiency; ongoing antineoplastic chemotherapy at the time of first examination; sequelae of radiotherapy in the head and neck area; oral mucosa disease, such as lichen planus; FMPS and FMBS > 20%; non-compliant patients; tobacco (>10 cigarettes per day) or alcohol abuse; non compensated diabetes; active periodontal disease at the time of first examination (in these cases, patients underwent etiologic therapy and motivation in personal oral hygiene and were re-evaluated for surgical treatment); bisphosphonate chemotherapy in progress; and pregnant women.	Severe bone defects
Navarro Cuellar et al., 2021 [50]: retrospective clinical study	8 W: 37.5%	N.R.	Inclusion criteria: Oncologic patients treated with segmental mandibulectomy and reconstructed with fibula flap; patients with traumatic injuries and mandibular segmental defects reconstructed with fibula flap; patients with three-dimensional discrepancy between the native mandible and the fibula flap; VSP, stereolithographic models, and CAD/CAM titanium mesh for 3D fibula reconstruction; and Cortico-cancellous iliac crest graft. Exclusion criteria: segmental mandibular defects reconstructed with double-barrel fibula flap and patients who previously underwent vertical distraction of the fibula flap.	Aesthetic and functional results

Table 2. Cont.

References (Authors, Year of Publication, and Study Design)	N° of Patients and % Women	Mean Age (Years), Mean (SD or Range)	Inclusion and Exclusion Criteria	Clinical Outcome
Yang et al., 2022 [51]: retrospective clinical study	Group 1: 10 Group 2: 10 W: 40%	35.7 (21–56)	Inclusion criteria: adults (at least 18 years); with good physical health, willing to actively cooperate with the clinical study; had undergone implant placement 6–9 months after GBR therapy with patient-specific titanium mesh in the first period. Exclusion criteria: No regular follow-up information; without complete imaging data.	Effective for minor and major bone defects
Ghanaati et al., 2019 [52]: case series	7 W: 71.4%	41	Inclusion criteria: N.R. Exclusion criteria: N.R.	Complex bone defects
Boogaard et al., 2019 [53]: case series	2 W: 50%	59.5	Inclusion criteria: N.R. Exclusion criteria: N.R.	Complex bone defects
Nickenig et al., 2022 [54]: case series	3 W: 66.7%	23.6	Inclusion criteria: N.R. Exclusion criteria: N.R.	Aesthetic results in severe bone defects
De Santis et al., 2022 [55]: case series	9 W: 66.7%	53.11 ± 6.79 43–65	1. Inclusion criteria: clear clinical and radiographic identification (using some or all the tools at our disposal) of maxillary /mandibular bone defects or atrophic ridge (different in causality but similar for problems presented), specifically less than 8 mm in height and 5 mm in thickness. 2. No presence of any local or systemic contraindication to surgical treatment, such as infections; smoking habit of >10 cigarettes a day; uncontrolled diabetes (HbA1c ≥ 7.5%); previous radiotherapy in the head and neck anatomical areas; chemotherapy; liver, blood, and kidney diseases; immunosuppression; state of pregnancy; inflammatory and autoimmune diseases of the oral cavity; poor oral hygiene; and poor motivation. 3. No (learned from clinical practice) need to insert dental implants before 8 months of complete healing. Exclusion criteria: N.R.	Severe or complex bone defects
Geletu et al., 2022 [56]: case report	1 W: 100%	27	Inclusion criteria: N.R. Exclusion criteria: N.R.	Aesthetic maxillary defects
Tallarico et al., 2020 [57]: case report	1 W: 100%	19	Inclusion criteria: N.R. Exclusion criteria: N.R.	Aesthetic maxillary defects

Legend: CAD/CAM: computed-aided design and manufacturing; FMBS: full mouth bleeding score; FMPS: full mouth plaque score; GBR: guided bone regeneration; HbA1c: glycosylated hemoglobin; N.R.: not reported; VBD: vertical bone defect; VSP: virtual surgical planning; W: women.

The NHLBI Quality Assessment Tool for Controlled Intervention Studies is shown in Table S6 (Supplementary Materials). The NHLBI Quality Assessment Tool for Before–After (Pre–Post) Studies with No Control Group is shown in Table S7. The NHLBI Quality Assessment Tool for Observational Cohort and Cross-Sectional Studies is shown in Table S8 (Supplementary Materials). The NHLBI Quality Assessment Tool for Case Series Studies/Case Reports is shown in Table S9 (Supplementary Materials).

4. Discussion

A total of 15 studies belonging to 4 different categories (controlled intervention studies, observational cohort studies, before–after (Pre–Post) studies with no control group, and case series/case report studies) were considered in this review.

In the last few years, thanks to recent digital technologies development and new materials testing, the GBR procedure has improved its clinical outcomes. Materials such as titanium (Ti) and polyether-ether-ketone (PEEK) have been used to perform alveolar bone enhancement and reconstruction thanks to their antimicrobial and osteogenic aspects [58]. Concerning oncologic, traumatological, and implantology fields, alveolar bone dimensions are fundamental to satisfy both aesthetic and functional aspects [59]. In the recent literature, several authors suggested customized mesh as an efficient device to reconstruct complex or severe bone deficits, intended as wide horizontal or vertical deficiencies or even the combination of both [45,60].

Therefore, this scoping review focuses on clinical management and clinical outcomes of the GBR procedure using custom-made full-digital meshes.

4.1. Bone Defect Dimension

The 3D technology and additive manufacturing procedure development permitted the creation of a patient-specific grid for GBR, established on the bone defect dimension, with notable properties, being physical or biological [27,61]. Contrary to standard Ti-mesh, the 3D-printed ones have smooth margins, with the chance of reducing mucosal detriment and consequential mesh exposure, the main complication occurring after GBR surgery. Moreover, bone deficits could be reconstructed more accurately and patient-specifically [28,62].

Some studies showed that 3D precision of bone increment is not significantly related to bone deficit dimensions, being minor or major bone defects [51]. Large combined alveolar bone defects in a horizontal and vertical dimension and simultaneous implant placement could be safely and predictably treated with virtual planning and CAD/CAM patient-specific mesh manufacturing [53]. The 3D patient models used for shaping the customized mesh permit a correct fitting to the alveolar bone.

Vertical bone deficiency can be efficiently treated with up to a 90% bone regeneration rate [45,46]. In complex bone defects, patient-specific Ti-mesh has been demonstrated to potentially concur to significant bone augmentation up to 11.48 mm in horizontal and 8.90 mm in vertical dimensions, suggesting laser-sintered CAD/CAM mesh as a reliable alternative in GBR procedure related to extended atrophic alveolar ridges [49].

4.2. Aesthetic Aspects

Maxillary and mandibular defects, being related to traumatic, tumoral, or congenital conditions, can significantly impact functional and aesthetic aspects of patients' lives; thus, their reconstruction is essential [63]. A key factor to consider when restoring aesthetic and functional features is the application of a grid, which permits obtaining and reinforcing 3D bone reconstruction.

Digital planning of the surgical procedure and tailored mesh permit the maintenance of bone shape. Additionally, they cooperate in the correct positioning of graft material to place implant fixtures and enhance the precision of bone augmentation and maxillary interconnection [50,64]. Regarding the anterior maxillary region, aesthetic considerations need to be conducted.

Implant placement is strictly related to an adequate volume of alveolar bone. Thus, individualized mesh seems to give promising results as far as it concerns bone augmentation and aesthetics [56].

In patients who present critical concavities of the vestibular bone, virtual bone volume augmentation and customized titanium mesh fabrication through 3D-printing technology showed a notable bone augmentation (after 6 months $3.7 \text{ mm } SD \pm 0.59$ and after 12 months $4.3 \text{ mm } (SD \pm 0.83)$ [54].

When positioning a personalized 3D Ti-mesh, it is important to consider the chance of obtaining good soft tissue management as well as good aesthetic results with voluminous and healthy tissue characteristics without any signs of scar or fibrosis [52].

A possible solution to ensure a complex bone regeneration in the aesthetic area could be a fully digital protocol that some clinicians already apply. This combines patient-specific titanium mesh with a prosthetically guided regeneration (PGR) to achieve predictable and satisfactory outcomes (Figures 3 and 4) [57].

Specifically, overlaying a digital diagnostic wax-up can make the bone reconstruction procedure prophetically guided, allowing the maintenance of an adequate buccal cortical to ensure a satisfactory esthetic outcome [65,66].

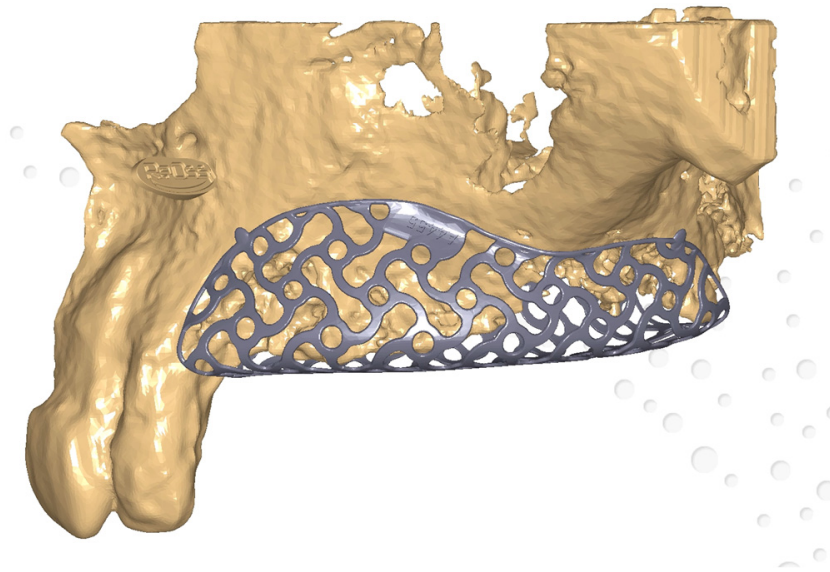


Figure 3. Customized mesh—virtual planning.

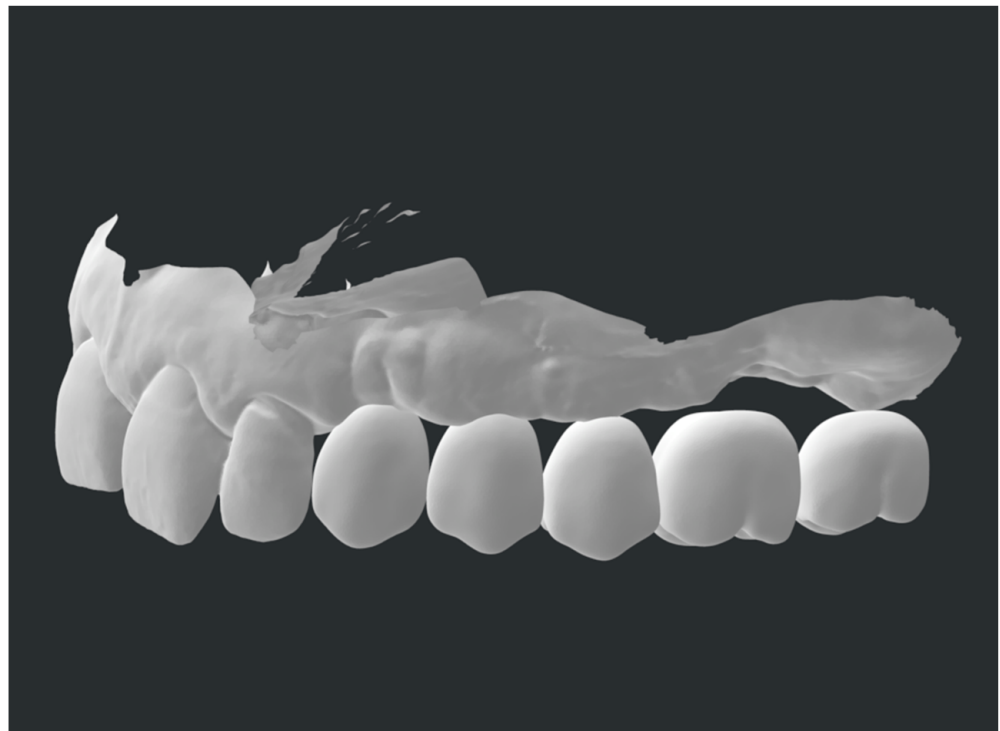


Figure 4. Prosthetically guided regeneration.

4.3. Biological Considerations

Considering the histological characteristics of augmented alveolar bone, thanks to digital and individualized meshes, the freshly regenerated bone appeared mineralized at different stages. Close to the bone substitute materials residues in the connective tissue or medullary cavities, no signs of inflammation were noticed, leading to a newly regenerated tissue with structure, organization, vitality, and functioning processes of remodeling and assimilation of grafting materials [47].

Associated with bone regeneration, in the case of custom-made grid positioning, rapid and natural re-epithelialization under the intern portion of the mesh was noticed. This sign may be related to the initial bone augmentation with limited depletion [49].

4.4. Clinical Success and Complications

Virtual planning and personalized grid manufacturing associated with flap layout and its control are crucial aspects to consider in order to achieve clinical success in the GBR procedure [55]. Individualized Ti-meshes are more rigid than standard ones; thus, mesh exposure could happen eventually, even with this digital procedure [67].

This may be due to mechanical stress to the mucosal tissue's flap, post-surgical removable prosthesis positioning, or eventually, the digital software learning curve and grid-projecting procedures [48].

Thus, a prudent approach must be adopted to ensure the clinical success of the procedure and avoid complications. Some authors showed that the application of a resorbable membrane above the customized mesh could reduce healing complication rates (13.3% vs. 33.3%) [43].

4.5. Early and Late Complication Management

In the case of mesh exposure, correct management can still lead to GBR success. The treatment consists of pharmacological or mechanical procedures.

Mesh exposure that occurs within 4 weeks after the surgical procedure is usually treated with chlorhexidine 0.2% (CHX) gels applied two to four times daily, followed by curettage of the interested site until tissue healing. Bone augmentation for implant positioning purposes is not limited in any way [21,68].

Alternatively, for CHX gel applications, the literature also suggests CHX mouthwashes or CHX spray with heterogeneous concentrations. However, gel preparations seem to be more effective than mouthwashes [69].

In the case of suspects of graft infection, topical antibiotic administration becomes relevant, while in the occurrence of mesh exposure, antibiotic administration is scarcely reported in the literature. This condition requires immediate mesh removal because of infection and pus. Plaque control and correct oral hygiene are also fundamental in these stages. Hence, saline washes and toothbrushes allow plaque removal [21].

For late exposure management, CHX 0.2% or, in some cases, 1% gel application two times a day until tissue healing appears to be useful and permits the maintenance of the mesh [20,70].

Mechanical smoothing of mesh edges with carbide or diamond burs for late exposure helps to create secondary healing of the wound [71,72].

4.6. New Materials

Despite titanium mesh being the most utilized material in guided-bone-regeneration processes, recently, the research has focused on different materials. Since PEEK material is starting to be broadly applied in the surgical field—orthopedic, traumatological, or even craniomaxillofacial—due to its inertness and biocompatibility, it could also be used in regenerative approaches [73,74].

In GBR procedures, customized PEEK grids have been applied to three-dimensional alveolar bone defects to place implant fixtures, and it has been demonstrated that there are no statistical differences (p -value = 0.2) between PEEK and pre-bent Ti-mesh, as far as it concerns bone regenerative processes [44].

Full-digital meshes represent one component of a digitization process that includes other stages that complete a surgical case, such as case design, CAD/CAM abutments and crowns, and other 3D-printed components [75–78].

This report presents some limitations. The search procedure could have been too specific for a scoping question. Moreover, the comparison between results could be complicated and might vary depending on the sample considered; indeed, digital software may give different results considering individual learning curves or technicians' capabilities. The same consideration should be applied to surgical procedures, mesh positioning, and management, which can vary based on clinician experience or patient compliance. Lastly,

the heterogeneity of digital software and 3D-printing devices available on the market can influence clinical results and thus clinical trial outcomes.

Future studies, especially randomized clinical trials, are needed to deeply analyze customized mesh produced through digital approaches for complex defects and new material testing other than titanium, as well as their complication rates.

5. Conclusions

The recent development of digital technologies such as CAD/CAM and 3D printing permits the creation of full-digital customized meshes, which can be applied in GBR procedures.

Personalized meshes are used to restore complex and severe bone defects, giving satisfactory aesthetic results. They adapt to the defects, counteracting grid exposure.

However, more studies should be conducted to evaluate long-term results, the rate of complications, and eventually to test new materials or technologies for mesh manufacturing.

Supplementary Materials: The following supporting information can be downloaded at: <https://www.mdpi.com/article/10.3390/prosthesis5020033/s1>, Table S1: PRISMA-ScR checklist.; Table S2: Search strategies for electronic databases; Table S3: Summary table of studies excluded in this scoping review; Table S4: Criteria for judging risk of bias in the “Risk of bias” assessment tool; Table S5: Evidence of studies included in this scoping review; Table S6: NHLBI Quality Assessment Tool for Controlled Intervention Studies; Table S7: NHLBI Quality Assessment for Before–After (Pre–Post) Studies with No Control Group; Table S8: NHLBI Quality Assessment Tool for Observational Cohort and Cross-Sectional Studies; Table S9: NHLBI Quality Assessment Tool for Case Series and Case Reports studies.

Author Contributions: Conceptualization, F.S. and C.M.; methodology, A.S. and F.S.; software, M.P. and A.S.; validation, A.S., F.S. and C.M.; formal analysis, F.S. and C.M.; investigation, F.P. and F.S.; resources, F.S. and A.S.; data curation, F.S., A.S. and P.P.P.; writing—original draft preparation, M.G., M.P. and F.P.; writing—review and editing, M.G., M.P. and A.S.; visualization, M.M. and P.P.P.; supervision, A.S., F.S. and C.M.; project administration, M.M. and C.M. All authors have read and agreed to the published version of the manuscript.

Funding: This research received no external funding.

Institutional Review Board Statement: Not applicable.

Informed Consent Statement: Not applicable.

Data Availability Statement: The data are available for use upon request to the corresponding author.

Conflicts of Interest: The authors declare no conflict of interest.

Protocol Registration: The protocol of the review was registered with the Open Science Framework (OSF) with DOI No 10.17605/OSF.IO/VRDF6 and registered at osf.io/4uwbj (accessed on 24 April 2023).

References

1. Hansson, S.; Halldin, A. Alveolar ridge resorption after tooth extraction: A consequence of a fundamental principle of bone physiology. *J. Dent. Biomech.* **2012**, *3*, 1758736012456543. [[CrossRef](#)] [[PubMed](#)]
2. Tan, W.L.; Wong, T.L.; Wong, M.C.; Lang, N.P. A systematic review of post-extraction alveolar hard and soft tissue dimensional changes in humans. *Clin. Oral Implant. Res.* **2012**, *23*, 1–21. [[CrossRef](#)] [[PubMed](#)]
3. Elgali, I.; Omar, O.; Dahlin, C.; Thomsen, P. Guided bone regeneration: Materials and biological mechanisms revisited. *Eur. J. Oral Sci.* **2017**, *125*, 315–337. [[CrossRef](#)] [[PubMed](#)]
4. Bornstein, M.M.; Halbritter, S.; Harnisch, H.; Weber, H.P.; Buser, D. A retrospective analysis of patients referred for implant placement to a specialty clinic: Indications, surgical procedures, and early failures. *Int. J. Oral Maxillofac. Implant.* **2008**, *23*, 1109–1116.
5. Retzepi, M.; Donos, N. Guided Bone Regeneration: Biological principle and therapeutic applications. *Clin. Oral Implant. Res.* **2010**, *21*, 567–576. [[CrossRef](#)]
6. Ortega-Oller, I.; Padiá-Molina, M.; Galindo-Moreno, P.; O’Valle, F.; Jódar-Reyes, A.B.; Peula-García, J.M. Bone Regeneration from PLGA Micro-Nanoparticles. *Biomed. Res. Int.* **2015**, *2015*, 415289. [[CrossRef](#)]

7. Padiál-Molina, M.; O'Valle, F.; Lanis, A.; Mesa, F.; Dohan Ehrenfest, D.M.; Wang, H.L.; Galindo-Moreno, P. Clinical Application of Mesenchymal Stem Cells and Novel Supportive Therapies for Oral Bone Regeneration. *Biomed. Res. Int.* **2015**, *2015*, 341327. [[CrossRef](#)]
8. Gallo, S.; Pascadopoli, M.; Pellegrini, M.; Pulicari, F.; Manfredini, M.; Zampetti, P.; Spadari, F.; Maiorana, C.; Scribante, A. Latest Findings of the Regenerative Materials Application in Periodontal and Peri-Implant Surgery: A Scoping Review. *Bioengineering* **2022**, *9*, 594. [[CrossRef](#)]
9. Kormas, I.; Pedercini, A.; Alassy, H.; Wolff, L.F. The Use of Biocompatible Membranes in Oral Surgery: The Past, Present & Future Directions. A Narrative Review. *Membranes* **2022**, *12*, 841.
10. Polo-Corrales, L.; Latorre-Esteves, M.; Ramirez-Vick, J.E. Scaffold design for bone regeneration. *J. Nanosci. Nanotechnol.* **2014**, *14*, 15–56. [[CrossRef](#)]
11. Jung, G.; Jeon, J.; Hwang, K.; Park, C. Preliminary evaluation of a three-dimensional, customized, and preformed titanium mesh in peri-implant alveolar bone regeneration. *J. Korean Assoc. Oral Maxillofac. Surg.* **2014**, *40*, 181–187. [[CrossRef](#)] [[PubMed](#)]
12. Badhey, A.; Kadakia, S.; Mourad, M.; Inman, J.; Ducic, Y. Calvarial Reconstruction. *Semin. Plast. Surg.* **2017**, *31*, 222–226. [[CrossRef](#)] [[PubMed](#)]
13. Konstantinidis, I.; Kumar, T.; Kher, U.; Stanitsas, P.D.; Hinrichs, J.E.; Kotsakis, G.A. Clinical results of implant placement in resorbed ridges using simultaneous guided bone regeneration: A multicenter case series. *Clin. Oral Investig.* **2015**, *19*, 553–559. [[CrossRef](#)]
14. Poli, P.P.; Beretta, M.; Cicciu, M.; Maiorana, C. Alveolar ridge augmentation with titanium mesh. A retrospective clinical study. *Open Dent. J.* **2014**, *8*, 148–158. [[CrossRef](#)] [[PubMed](#)]
15. Zhou, M.; Li, S.Y.; Terheyden, H.; Cao, S.S.; Che, Y.J.; Geng, Y.M. Particulate Coral Hydroxyapatite Sheltered by Titanium Mesh for Localized Alveolar Rehabilitation After Onlay Graft Failure: A Case Report. *J. Oral Implantol.* **2018**, *44*, 147–152. [[CrossRef](#)]
16. Maiorana, C.; Manfredini, M.; Beretta, M.; Signorino, F.; Bovio, A.; Poli, P.P. Clinical and Radiographic Evaluation of Simultaneous Alveolar Ridge Augmentation by Means of Preformed Titanium Meshes at Dehiscence-Type Peri-Implant Defects: A Prospective Pilot Study. *Materials* **2020**, *13*, 2389. [[CrossRef](#)]
17. Louis, P.J.; Gutta, R.; Said-Al-Naief, N.; Bartolucci, A.A. Reconstruction of the maxilla and mandible with particulate bone graft and titanium mesh for implant placement. *J. Oral Maxillofac. Surg.* **2008**, *66*, 235–245. [[CrossRef](#)]
18. Corinaldesi, G.; Pieri, F.; Sapiigni, L.; Marchetti, C. Evaluation of survival and success rates of dental implants placed at the time of or after alveolar ridge augmentation with an autogenous mandibular bone graft and titanium mesh: A 3- to 8-year retrospective study. *Int. J. Oral Maxillofac. Implant.* **2009**, *24*, 1119–1128.
19. Maiorana, C.; Santoro, F.; Rabagliati, M.; Salina, S. Evaluation of the use of iliac cancellous bone and anorganic bovine bone in the reconstruction of the atrophic maxilla with titanium mesh: A clinical and histologic investigation. *Int. J. Oral Maxillofac. Implant.* **2001**, *16*, 427–432.
20. Rocuzzo, M.; Ramieri, G.; Bunino, M.; Berrone, S. Autogenous bone graft alone or associated with titanium mesh for vertical alveolar ridge augmentation: A controlled clinical trial. *Clin. Oral Implant. Res.* **2007**, *18*, 286–294. [[CrossRef](#)]
21. Poli, P.P.; Beretta, M.; Maiorana, C.; Souza, F.Á.; Bovio, A.; Manfredini, M. Therapeutic Strategies in the Management of Nonresorbable Membrane and Titanium Mesh Exposures Following Alveolar Bone Augmentation: A Systematic Scoping Review. *Int. J. Oral Maxillofac. Implant.* **2022**, *37*, 250–269. [[CrossRef](#)] [[PubMed](#)]
22. Benic, G.I.; Hämmerle, C.H. Horizontal bone augmentation by means of guided bone regeneration. *Periodontol. 2000* **2014**, *66*, 13–40. [[CrossRef](#)] [[PubMed](#)]
23. Okubo, T.; Tsukimura, N.; Taniyama, T.; Ishijima, M.; Nakhaei, K.; Rezaei, N.M.; Hirota, M.; Park, W.; Akita, D.; Tateno, A.; et al. Ultraviolet treatment restores bioactivity of titanium mesh plate degraded by contact with medical gloves. *J. Oral Sci.* **2018**, *60*, 567–573. [[CrossRef](#)] [[PubMed](#)]
24. Hartmann, A.; Hildebrandt, H.; Schmohl, J.U.; Kämmerer, P.W. Evaluation of risk parameters in bone regeneration using a customized titanium mesh: Results of a clinical study. *Implant. Dent.* **2019**, *28*, 543–550. [[CrossRef](#)] [[PubMed](#)]
25. Al-Ardah, A.J.; Alqahtani, N.; AlHelal, A.; Goodacre, B.J.; Swamidass, R.; Garbacea, A.; Lozada, J. Using Virtual Ridge Augmentation and 3-Dimensional Printing to Fabricate a Titanium Mesh Positioning Device: A Novel Technique Letter. *J. Oral Implantol.* **2018**, *44*, 293–299. [[CrossRef](#)] [[PubMed](#)]
26. Hartmann, A.; Seiler, M. Minimizing risk of customized titanium mesh exposures—A retrospective analysis. *BMC Oral Health* **2020**, *20*, 36. [[CrossRef](#)]
27. Inoue, K.; Nakajima, Y.; Omori, M.; Suwa, Y.; Kato-Kogoe, N.; Yamamoto, K.; Kitagaki, H.; Mori, S.; Nakano, H.; Ueno, T. Reconstruction of the Alveolar Bone Using Bone Augmentation With Selective Laser Melting Titanium Mesh Sheet: A Report of 2 Cases. *Implant. Dent.* **2018**, *27*, 602–607. [[CrossRef](#)]
28. Ciocca, L.; Fantini, M.; De Crescenzo, F.; Corinaldesi, G.; Scotti, R. Direct metal laser sintering (DMLS) of a customized titanium mesh for prosthetically guided bone regeneration of atrophic maxillary arches. *Med. Biol. Eng. Comput.* **2011**, *49*, 1347–1352. [[CrossRef](#)]
29. Aromataris, E.; Munn, Z. JBI Manual for Evidence Synthesis. 2020. Available online: <https://synthesismanual.jbi.global> (accessed on 24 April 2023).

30. Tricco, A.C.; Lillie, E.; Zarin, W.; O'Brien, K.K.; Colquhoun, H.; Levac, D.; Moher, D.; Peters, M.D.; Horsley, T.; Weeks, L.; et al. PRISMA extension for scoping reviews (PRISMA-ScR): Checklist and explanation. *Ann. Intern. Med.* **2018**, *169*, 467–473. [[CrossRef](#)]
31. Nhlbi, N.I.H. Study Quality Assessment Tool. Available online: <https://www.nhlbi.nih.gov/health-topics/study-quality-assessment-tools> (accessed on 24 April 2023).
32. Xie, Y.; Li, S.; Zhang, T.; Wang, C.; Cai, X. Titanium mesh for bone augmentation in oral implantology: Current application and progress. *Int. J. Oral Sci.* **2020**, *12*, 37. [[CrossRef](#)]
33. Tolstunov, L.; Hamrick, J.F.E.; Broumand, V.; Shilo, D.; Rachmiel, A. Bone Augmentation Techniques for Horizontal and Vertical Alveolar Ridge Deficiency in Oral Implantology. *Oral Maxillofac. Surg. Clin. N. Am.* **2019**, *31*, 163–191. [[CrossRef](#)] [[PubMed](#)]
34. Zhou, L.; Su, Y.; Wang, J.; Wang, X.; Liu, Q.; Wang, J. Effect of Exposure Rates With Customized Versus Conventional Titanium Mesh on Guided Bone Regeneration: Systematic Review and Meta-Analysis. *J. Oral Implantol.* **2022**, *48*, 339–346. [[CrossRef](#)] [[PubMed](#)]
35. Herford, A.S.; Lowe, I.; Jung, P. Titanium Mesh Grafting Combined with Recombinant Human Bone Morphogenetic Protein 2 for Alveolar Reconstruction. *Oral Maxillofac. Surg. Clin. N. Am.* **2019**, *31*, 309–315. [[CrossRef](#)] [[PubMed](#)]
36. Casap, N.; Rushinek, H.; Jensen, O.T. Vertical Alveolar Augmentation Using BMP-2/ACS/Allograft with Printed Titanium Shells to Establish an Early Vascular Scaffold. *Oral Maxillofac. Surg. Clin. N. Am.* **2019**, *31*, 473–487. [[CrossRef](#)]
37. Trento, G.S.; Carvalho, P.H.A.; Macedo, D.V.; Gabrielli, M.A.C.; Monnazzi, M.S.; Pereira-Filho, V.A. Titanium mesh associated with rhBMP-2 in alveolar ridge reconstruction. *Int. J. Oral Maxillofac. Surg.* **2019**, *48*, 546–553. [[CrossRef](#)] [[PubMed](#)]
38. Lim, G.; Lin, G.H.; Monje, A.; Chan, H.L.; Wang, H.L. Wound Healing Complications Following Guided Bone Regeneration for Ridge Augmentation: A Systematic Review and Meta-Analysis. *Int. J. Oral Maxillofac. Implant.* **2018**, *33*, 41–50. [[CrossRef](#)] [[PubMed](#)]
39. Ricci, L.; Perrotti, V.; Ravera, L.; Scarano, A.; Piattelli, A.; Iezzi, G. Rehabilitation of deficient alveolar ridges using titanium grids before and simultaneously with implant placement: A systematic review. *J. Periodontol.* **2013**, *84*, 1234–1242. [[CrossRef](#)]
40. Rasia-dal Polo, M.; Poli, P.P.; Rancitelli, D.; Beretta, M.; Maiorana, C. Alveolar ridge reconstruction with titanium meshes: A systematic review of the literature. *Med. Oral Patol. Oral Cir. Bucal.* **2014**, *19*, e639–e646. [[CrossRef](#)]
41. Briguglio, F.; Falcomatà, D.; Marconcini, S.; Fiorillo, L.; Briguglio, R.; Farronato, D. The Use of Titanium Mesh in Guided Bone Regeneration: A Systematic Review. *Int. J. Dent.* **2019**, *2019*, 9065423. [[CrossRef](#)]
42. Carini, F.; Longoni, S.; Amosso, E.; Paleari, J.; Carini, S.; Porcaro, G. Bone augmentation with TiMesh. autologous bone versus autologous bone and bone substitutes. A systematic review. *Ann. Stomatol.* **2014**, *5*, 27–36.
43. Cucchi, A.; Vignudelli, E.; Franceschi, D.; Randellini, E.; Lizio, G.; Fiorino, A.; Corinaldesi, G. Vertical and horizontal ridge augmentation using customized CAD/CAM titanium mesh with versus without resorbable membranes. A randomized clinical trial. *Clin. Oral Implant. Res.* **2021**, *32*, 1411–1424. [[CrossRef](#)] [[PubMed](#)]
44. Mounir, M.; Shalash, M.; Mounir, S.; Nassar, Y.; El Khatib, O. Assessment of three-dimensional bone augmentation of severely atrophied maxillary alveolar ridges using prebent titanium mesh vs customized poly-ether-ether-ketone (PEEK) mesh: A randomized clinical trial. *Clin. Implant Dent. Relat. Res.* **2019**, *21*, 960–967. [[CrossRef](#)] [[PubMed](#)]
45. Cucchi, A.; Bettini, S.; Corinaldesi, G. A novel technique for digitalisation and customisation of reinforced polytetrafluoroethylene meshes: Preliminary results of a clinical trial. *Int. J. Oral Implantol.* **2022**, *15*, 129–146.
46. Lizio, G.; Pellegrino, G.; Corinaldesi, G.; Ferri, A.; Marchetti, C.; Felice, P. Guided bone regeneration using titanium mesh to augment 3-dimensional alveolar defects prior to implant placement. A pilot study. *Clin. Oral Implant. Res.* **2022**, *33*, 607–621. [[CrossRef](#)]
47. Dellavia, C.; Canciani, E.; Pellegrini, G.; Tommasato, G.; Graziano, D.; Chiapasco, M. Histological assessment of mandibular bone tissue after guided bone regeneration with customized computer-aided design/computer-assisted manufacture titanium mesh in humans: A cohort study. *Clin. Implant Dent. Relat. Res.* **2021**, *23*, 600–611. [[CrossRef](#)]
48. Ciocca, L.; Lizio, G.; Baldissara, P.; Sambuco, A.; Scotti, R.; Corinaldesi, G. Prosthetically CAD-CAM-Guided Bone Augmentation of Atrophic Jaws Using Customized Titanium Mesh: Preliminary Results of an Open Prospective Study. *J. Oral Implantol.* **2018**, *44*, 131–137. [[CrossRef](#)]
49. Chiapasco, M.; Casentini, P.; Tommasato, G.; Dellavia, C.; Del Fabbro, M. Customized CAD/CAM titanium meshes for the guided bone regeneration of severe alveolar ridge defects: Preliminary results of a retrospective clinical study in humans. *Clin. Oral Implant. Res.* **2021**, *32*, 498–510. [[CrossRef](#)]
50. Navarro Cuéllar, C.; Tousidonis Rial, M.; Antúnez-Conde, R.; Ochandiano Caicoya, S.; Navarro Cuéllar, I.; Arenas de Frutos, G.; Sada Urmeneta, Á.; García-Hidalgo Alonso, M.I.; Navarro Vila, C.; Salmerón Escobar, J.I. Virtual Surgical Planning, Stereolithographic Models and CAD/CAM Titanium Mesh for Three-Dimensional Reconstruction of Fibula Flap with Iliac Crest Graft and Dental Implants. *J. Clin. Med.* **2021**, *10*, 1922. [[CrossRef](#)]
51. Yang, W.; Chen, D.; Wang, C.; Apicella, D.; Apicella, A.; Huang, Y.; Li, L.; Zheng, L.; Ji, P.; Wang, L.; et al. The effect of bone defect size on the 3D accuracy of alveolar bone augmentation performed with additively manufactured patient-specific titanium mesh. *BMC Oral Health* **2022**, *22*, 557. [[CrossRef](#)]
52. Ghanaati, S.; Al-Maawi, S.; Conrad, T.; Lorenz, J.; Rössler, R.; Sader, R. Biomaterial-based bone regeneration and soft tissue management of the individualized 3D-titanium mesh: An alternative concept to autologous transplantation and flap mobilization. *J. Craniomaxillofac. Surg.* **2019**, *47*, 1633–1644. [[CrossRef](#)]

53. Boogaard, M.J.; Santoro, F.; Romanos, G.E. Mesh Ridge Augmentation Using CAD/CAM Technology for Design and Printing: Two Case Reports. *Compend. Contin. Educ. Dent.* **2022**, *43*, 654–663. [[PubMed](#)]
54. Nickenig, H.J.; Riekert, M.; Zirk, M.; Lentzen, M.P.; Zöller, J.E.; Kreppel, M. 3D-based buccal augmentation for ideal prosthetic implant alignment—an optimized method and report on 7 cases with pronounced buccal concavities. *Clin. Oral Investig.* **2022**, *26*, 3999–4010. [[CrossRef](#)] [[PubMed](#)]
55. De Santis, D.; Luciano, U.; Donadello, D.; Faccioni, P.; Zarantonello, M.; Alberti, C.; Verlato, G.; Gelpi, F. Custom Bone Regeneration (CBR): An Alternative Method of Bone Augmentation—A Case Series Study. *J. Clin. Med.* **2022**, *11*, 4739. [[CrossRef](#)] [[PubMed](#)]
56. Gelețu, G.L.; Burlacu, A.; Murariu, A.; Andrian, S.; Golovcencu, L.; Baci, E.R.; Maftai, G.; Onica, N. Customized 3D-Printed Titanium Mesh Developed for an Aesthetic Zone to Regenerate a Complex Bone Defect Resulting after a Deficient Odontectomy: A Case Report. *Medicina* **2022**, *58*, 1192. [[CrossRef](#)]
57. Tallarico, M.; Park, C.J.; Lumbau, A.I.; Annucci, M.; Baldoni, E.; Koshovari, A.; Meloni, S.M. Customized 3D-Printed Titanium Mesh Developed to Regenerate a Complex Bone Defect in the Aesthetic Zone: A Case Report Approached with a Fully Digital Workflow. *Materials* **2020**, *13*, 3874. [[CrossRef](#)]
58. Shi, Y.; Liu, J.; Du, M.; Zhang, S.; Liu, Y.; Yang, H.; Shi, R.; Guo, Y.; Song, F.; Zhao, Y.; et al. Customized Barrier Membrane (Titanium Alloy, Poly Ether-Ether Ketone and Unsintered Hydroxyapatite/Poly-L-Lactide) for Guided Bone Regeneration. *Front. Bioeng. Biotechnol.* **2022**, *10*, 916967. [[CrossRef](#)]
59. Matsuo, A.; Chiba, H.; Takahashi, H.; Toyoda, J.; Abukawa, H. Clinical Application of a Custom-Made Bioresorbable Raw Particulate Hydroxyapatite/Poly-L-Lactide Mesh Tray for Mandibular Reconstruction. *Odontology* **2010**, *98*, 85–88. [[CrossRef](#)]
60. El Morsy, O.A.; Barakat, A.; Mekhemer, S.; Mounir, M. Assessment of 3-dimensional Bone Augmentation of Severely Atrophied Maxillary Alveolar Ridges Using Patient-specific Poly Ether-ether Ketone (PEEK) Sheets. *Clin. Implant Dent. Relat. Res.* **2020**, *22*, 148–155. [[CrossRef](#)]
61. Kadkhodazadeh, M.; Amid, R.; Moscowchi, A. Management of extensive peri-implant defects with titanium meshes. *Oral Maxillofac. Surg.* **2021**, *25*, 561–568. [[CrossRef](#)]
62. Windisch, P.; Orban, K.; Salvi, G.E.; Sculean, A.; Molnar, B. Vertical-guided bone regeneration with a titanium-reinforced d-PTFE membrane utilizing a novel split-thickness flap design: A prospective case series. *Clin. Oral Investig.* **2021**, *25*, 2969–2980. [[CrossRef](#)]
63. Cuellar, C.N.; Gil, M.C.; Delgado, J.P.; Martínez, B.G.; Sanz, J.A.; de Atalaya, J.L.; Ochandiano, S.; Vila, C.N. Reconstrucción oromandibular con colgajo libre de peroné e implantes osteointegrados. *Acta Otorrinolaringol. Esp.* **2003**, *54*, 54–64. [[CrossRef](#)] [[PubMed](#)]
64. Iino, M.; Fukuda, M.; Nagai, H.; Hamada, Y.; Yamada, H.; Nakaoka, K.; Mori, Y.; Chikazu, D.; Saijo, H.; Seto, I.; et al. Evaluation of 15 mandibular reconstructions with Dumbach titan mesh-system and particulate cancellous bone and marrow harvested from bilateral posterior ilia. *Oral Surg. Oral Med. Oral Pathol. Oral Radiol. Endod.* **2009**, *107*, e1–e8. [[CrossRef](#)] [[PubMed](#)]
65. Farronato, D.; Pasini, P.M.; Orsina, A.A.; Manfredini, M.; Azzi, L.; Farronato, M. Correlation between Buccal Bone Thickness at Implant Placement in Healed Sites and Buccal Soft Tissue Maturation Pattern: A Prospective Three-Year Study. *Materials* **2020**, *13*, 511. [[CrossRef](#)] [[PubMed](#)]
66. Chiapasco, M.; Casentini, P. Horizontal bone-augmentation procedures in implant dentistry: Prosthodontically guided regeneration. *Periodontol.* **2000** **2018**, *77*, 213–240. [[CrossRef](#)]
67. Lorenz, J.; Al-Maawi, S.; Sader, R.; Ghanaati, S. Individualized Titanium Mesh Combined With Platelet-Rich Fibrin and Deproteinized Bovine Bone: A New Approach for Challenging Augmentation. *J. Oral Implantol.* **2018**, *44*, 345–351. [[CrossRef](#)]
68. Lizio, G.; Corinaldesi, G.; Marchetti, C. Alveolar ridge reconstruction with titanium mesh: A three-dimensional evaluation of factors affecting bone augmentation. *Int. J. Oral Maxillofac. Implant.* **2014**, *29*, 1354–1363. [[CrossRef](#)]
69. Canullo, L.; Laino, L.; Longo, F.; Filetici, P.; D’Onofrio, I.; Troiano, G. Does chlorhexidine prevent complications in extractive, periodontal, and implant surgery? A systematic review and meta-analysis with trial sequential analysis. *Int. J. Oral Maxillofac. Implant.* **2020**, *35*, 1149–1158. [[CrossRef](#)]
70. Rocuzzo, M.; Ramieri, G.; Spada, M.C.; Bianchi, S.D.; Berrone, S. Vertical alveolar ridge augmentation by means of a titanium mesh and autogenous bone grafts. *Clin. Oral Implant. Res.* **2004**, *15*, 73–81. [[CrossRef](#)]
71. Al-Ardah, A.J.; AlHelal, A.; Proussaefs, P.; AlBader, B.; Al Humaidan, A.A.; Lozada, J. Managing titanium mesh exposure with partial removal of the exposed site: A case series study. *J. Oral Implantol.* **2017**, *43*, 482–490. [[CrossRef](#)]
72. Her, S.; Kang, T.; Fien, M.J. Titanium mesh as an alternative to a membrane for ridge augmentation. *J. Oral Maxillofac. Surg.* **2012**, *70*, 803–810. [[CrossRef](#)]
73. Suresh, V.; Anolik, R.; Powers, D. The Utility of Polyether-Ether-Ketone Implants Adjacent to Sinus Cavities after Craniofacial Trauma. *J. Oral Maxillofac. Surg.* **2018**, *76*, 2361–2369. [[CrossRef](#)]
74. Honigsmann, P.; Sharma, N.; Okolo, B.; Popp, U.; Msallem, B.; Thieringer, F.M. Patient-Specific Surgical Implants Made of 3D Printed PEEK: Material, Technology, and Scope of Surgical Application. *Biomed. Res. Int.* **2018**, *2018*, 4520636. [[CrossRef](#)]
75. Salem, D.; Reher, P.; Evans, J.L.; Mansour, M.H. Exploring digital technologies used in the design and manufacture of craniofacial implant surgical guides: A scoping review. *J. Prosthet. Dent.* **2023**, in press. [[CrossRef](#)] [[PubMed](#)]

76. Thakur, J.; Parlani, S.; Shivakumar, S.; Jajoo, K. Accuracy of marginal fit of an implant-supported framework fabricated by 3D printing versus subtractive manufacturing technique: A systematic review and meta-analysis. *J. Prosthet. Dent.* **2023**, *129*, 301–309. [[CrossRef](#)] [[PubMed](#)]
77. Gallo, S.; Pascadopoli, M.; Pellegrini, M.; Pulicari, F.; Manfredini, M.; Zampetti, P.; Spadari, F.; Maiorana, C.; Scribante, A. CAD/CAM Abutments versus Stock Abutments: An Update Review. *Prosthesis* **2022**, *4*, 468–479. [[CrossRef](#)]
78. Cabello-Domínguez, G.; Pérez-López, J.; Veiga-López, B.; González, D.; Revilla-León, M. Maxillary zirconia and mandibular composite resin-lithium disilicate-modified PEEK fixed implant-supported restorations for a completely edentulous patient with an atrophic maxilla and mandible: A clinical report. *J. Prosthet. Dent.* **2020**, *124*, 403–410. [[CrossRef](#)]

Disclaimer/Publisher’s Note: The statements, opinions and data contained in all publications are solely those of the individual author(s) and contributor(s) and not of MDPI and/or the editor(s). MDPI and/or the editor(s) disclaim responsibility for any injury to people or property resulting from any ideas, methods, instructions or products referred to in the content.