

SUPPLEMENTARY MATERIAL

Supplementary Table S1. Evaluation Criteria for Tissue for Study Enrollment.

	Adequate	Not Adequate
Morphology (H&E)	Cellular elements of interest are visualized, allowing clinical interpretation of the stain	Cellular elements of interest are not visualized, compromising clinical interpretation of the stain
Tumor Content	≥ 50% of tissue with CRC	< 50% of tissue with CRC
Pre-analytical Preparation (H&E)	Formalin-fixed, paraffin-embedded with indications of proper fixation	Formalin-fixed, paraffin-embedded with unacceptable morphology and indications of poor fixation
Tissue Quantity (FFPE Block)	Sufficient tissue to support IHC (20 slides), sequencing (100 microns) and methylation testing (50 microns)	Insufficient tissue to fulfill study needs

Supplementary Table S2. Key Genomic Loci Sequenced in ColoSeq™

Target	Reference Transcript
<i>MLH1</i>	NM_000249.3
<i>MSH2</i>	NM_000251.1
<i>MSH6</i>	NM_000179.2
<i>PMS2</i>	NM_000535.5
<i>BRAF</i>	NM_004333.4
<i>POLE</i>	NM_006231.2
<i>POLD1</i>	NM_002691.3

Supplementary Table S3. Molecular Status & IHC Assay Congruency

	Molecular Status	IHC Status
Abnormal (presence of pathogenic mutation)	<i>MLH1</i> Pathogenic Mutation	MLH1 loss with PMS2 loss
	<i>MLH1</i> Promoter Hypermethylation	MLH1 loss with PMS2 loss
	<i>PMS2</i> Pathogenic Mutation	PMS2 loss only
	<i>MSH2</i> Pathogenic Mutation	MSH2 loss only MSH2 loss with MSH6 loss
	<i>MSH6</i> Pathogenic Mutation	MSH6 loss only
	<i>BRAF</i> p.V600E mutation	BRAF V600E positive
Normal/Expected (Absence of pathologic mutation)ⁱ	<i>MLH1</i> negative hypermethylation	MLH1 intact
	<i>PMS2</i>	PMS2 intact PMS2 loss with MLH1 loss
	<i>MSH2</i>	MSH2 intact
	<i>MSH6</i>	MSH6 intact MSH6 loss with MSH2 loss
	<i>BRAF</i>	BRAF V600E negative

i- Due to the heterodimerization of MLH1/PMS2 and MSH2/MSH6, loss of partner staining can be observed in the absence of a mutation in that specific gene.

Supplementary Table S4. Agreement between IHC using VENTANA anti-BRAF V600E (VE1) antibody and NGS Testing

BRAF V600E Status (NGS/IHC)	Agreement			
	Type	n/N	%	95% CI
Positive/Abnormal	PPA	23/23	100.0	(85.7, 100.0)
Negative/Normal	NPA	95/95	100.0	(96.1, 100.0)
Total	OPA	118/118	100.0	(96.8, 100.0)

Status for *BRAF* p.V600E was defined as Positive or Negative IHC results and Abnormal (presence of the p.V600E mutation) or Normal (wild-type *BRAF*) results by molecular testing.

Supplementary Table S5. IHC vs. Molecular Testing Status for Enrichment & Sequential Cohort

Cohort	IHC Test	Molecular Tests[i]			Agreement		
		Normal [ii]	Abnormal/ Hypermethylated[iii]	Total	Type	n/N	% (95% CI)
Enrichment	Correct [iv]	49	12	61	PPA	49/52	94.2 (87.5,100.0)
	Incorrect [iv]	3	1	4	NPA	12/13	92.3 (75.0,100.0)
	Total	52	13	65	OPA	61/65	93.8 (87.7,98.5)
Sequential	Correct [iv]	474	46	520	PPA	474/474	100.0 (n.e.)
	Incorrect [iv]	0	3	3	NPA	46/49	93.9 (86.7,100.0)
	Total	474	49	523	OPA	520/523	99.4 (98.7,100.0)

[i] For MLH1, molecular testing included both sequencing data and *MLH1* promoter hypermethylation results. For PMS2, abnormal included sequencing data for *PMS2* and *MLH1* and *MLH1* hypermethylation as PMS2 stability is linked to MLH1 status; For MSH2, molecular testing was solely based on the sequencing test; for MSH6, molecular testing included sequencing test results for *MSH6* and *MSH2* as MSH2 stability is linked to MSH6 status. For BRAF V600E, molecular testing was solely based on the sequencing test.

[ii] Normal = Molecular results support intact protein expression.

[iii] Abnormal/Hypermethylated = A sequencing result consistent with loss of protein expression or positive for promoter hypermethylation.

[iv] A "Correct" or "Incorrect" IHC assessment was determined by viewing the congruency between molecular and IHC testing.

Supplementary Table S6. Pooled Analysis for VENTANA MMR IHC Panel Agreement between IHC and Molecular Testing

Status* (Molecular/IHC)	Agreement			
	Type	n/N	%	95% CI
Normal/Intact	PPA	523/526	99.4	(98.7,100.0)
Abnormal/Loss	NPA	58/62	93.5	(87.1, 98.6)
Total	OPA	581/588	98.8	(97.8, 99.7)

*For IHC, MMR Status is Intact or Loss for protein expression. For this analysis, BRAF V600E negative and positive cases were included in Intact or Loss categories, respectively. Molecular testing indicates absence (Normal) or presence (Abnormal) of potential pathogenic mutations or *MLH1* promoter hypermethylation.

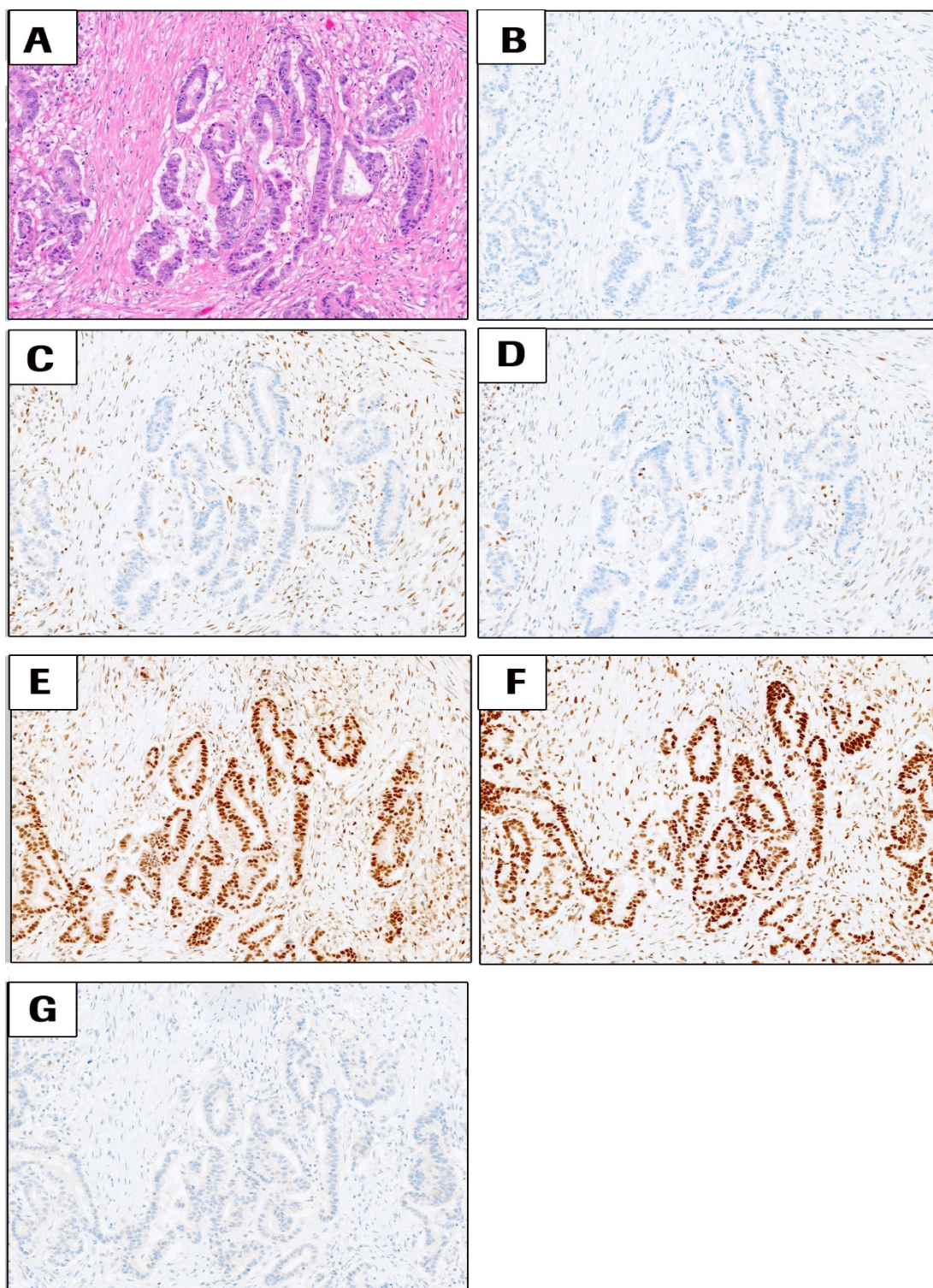
Supplementary Table S7. Pooled Analysis for four MMR IHC markers (without VENTANA anti-BRAF V600E (VE1) antibody) Agreement between IHC and Molecular Testing

Status* (Molecular/IHC)	Agreement			
	Type	n/N	%	95% CI
Normal/Intact	PPA	428/431	99.3	(98.4, 100.0)
Abnormal/Loss	NPA	35/39	89.7	(79.4, 97.7)
Total	OPA	463/470	98.5	(97.3, 99.6)

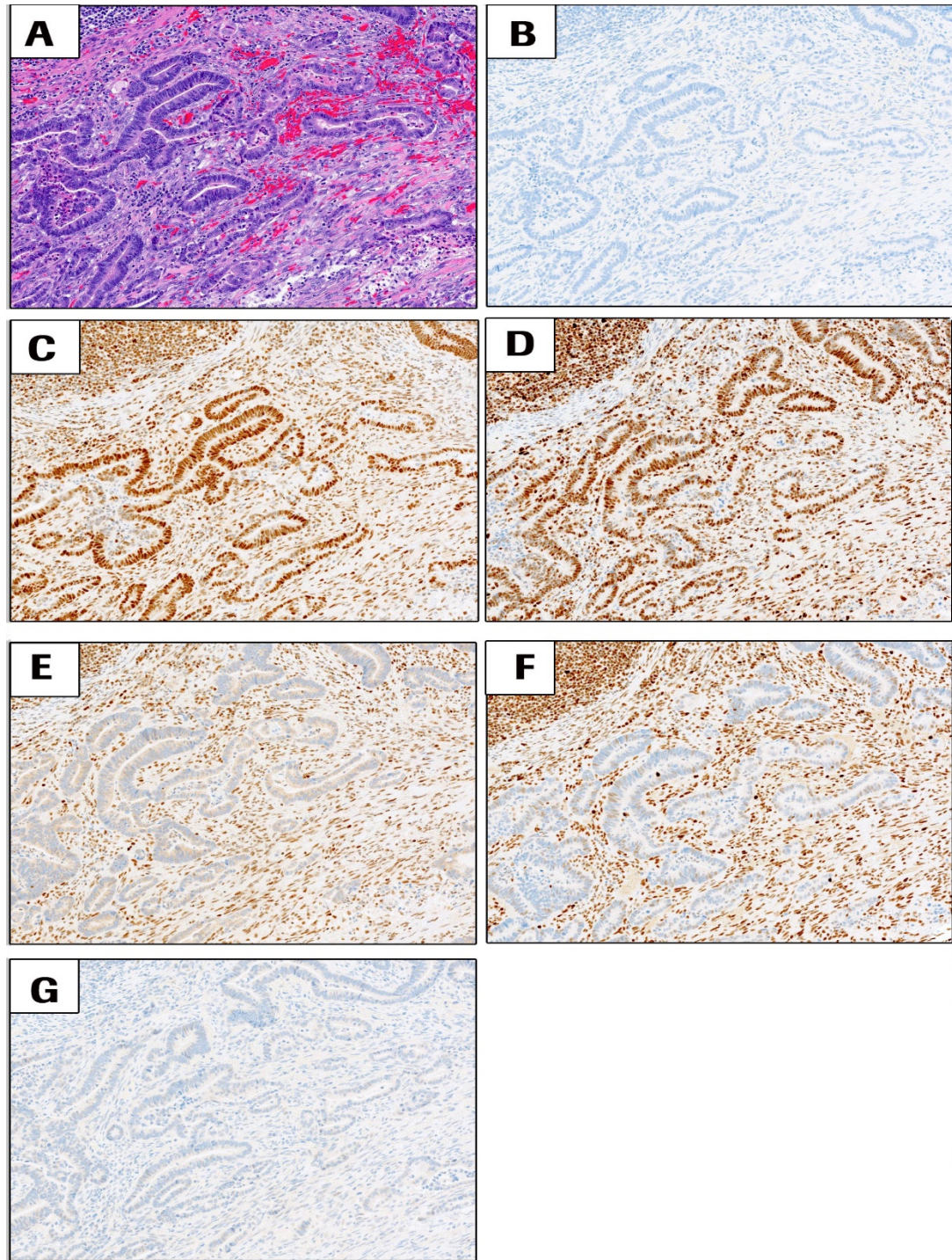
*For IHC, Status is Intact or Loss for protein expression. Molecular testing indicates absence (Normal) or presence (Abnormal) of potential pathogenic mutations or *MLH1* promoter hypermethylation.

Supplementary Table S8. Description of Discrepant Cases

Case ID	Discrepant Marker	Sequencing Status	IHC Status	MSI Status	Comments
pUID00021	MSH6	<i>MSH6</i> Abnormal	MLH1 intact PMS2 intact MSH2 intact MSH6 intact	MSS	<i>POLE</i> - p.P286R mutation, <i>MSH6</i> – multiple variants, one variant of unknown significance is non-synonymous, which may not result in loss of staining by IHC, negative for MLH1 promoter methylation (UW-GSTL)
pUID00023	MSH6	<i>MSH6</i> Abnormal	MLH1 loss PMS2 loss MSH2 intact MSH6 intact	MSI-H	<i>MSH6</i> -p.R1095H @37%, p.F1088Lfs*5 @16%. One variant is SNV, <i>MSH6</i> could be expressed and detected by IHC <i>MLH1</i> -p.K196Nfs*6 @36% - likely heterozygous in tumor <i>PMS2</i> – p.E109Gfs*30 @28% - likely heterozygous in tumor, positive for <i>MLH1</i> promoter methylation
pUID00024	MSH6	<i>MSH6</i> Abnormal	MLH1 intact PMS2 intact MSH2 intact MSH6 intact	MSI-H	<i>MSH6</i> - p.Q177* @26%, p.F1088Lfs*5 @14%, IHC – heterogeneous staining
pUID00042	PMS2	Normal	MLH1 intact PMS2 loss MSH2 intact MSH6 intact	MSI-H	Poor DNA quality, low coverage 55x, <i>MSH6</i> - p.F1088Sfs*2 @13%, low VAF frameshift - likely secondary to MSI, negative for <i>MLH1</i> promoter methylation (UW-GSTL)
pUID00080	MSH2	Normal	MLH1 intact PMS2 intact MSH2 loss MSH6 loss	MSI-H	<i>MSH2</i> - p.T320Yfs*13 @29%, heterozygous frameshift, <i>PMS2</i> – p.R628* @31% – probably not resulting in loss of PMS2, <i>MSH6</i> – p.S126P @34%, p.F1088Lfs*5 @15%
pUID00087	MSH2	Normal	MLH1 intact PMS2 intact MSH2 loss MSH6 loss	MSI-H	<i>MSH2</i> - p. T320Yfs*13 @27% - probably secondary to MSI <i>MSH6</i> - p.S126P @31%, p.F1088Lfs*5 @17%
pUID000124	MSH6	<i>MSH6</i> Abnormal	MLH1 loss PMS2 loss MSH2 intact MSH6 intact	MSI-H	Possible Lynch syndrome – <i>MSH6</i> - p.K13T, p.F1191Lfs*4 no BRAF mutation, <i>MLH1</i> promoter methylation - positive on residual DNA (UW-GSTL)



Supplementary Figure S1. Representative images of possible Lynch syndrome CRC case with deficient DNA mismatch repair status (dMMR) due to MLH1 and PMS2 loss, with intact MSH2 and MSH6, BRAF V600E is negative for this case. All images are 10x magnification. (A) H&E, (B) negative control antibody, (C) MLH1, (D) PMS2, (E) MSH2, (F) MSH6 and (G) BRAF V600E staining. All images are at 10x magnification.



Supplementary Figure S2. Possible Lynch Syndrome. This case exhibits deficient DNA mismatch repair status (dMMR) due to MSH2 and MSH6 loss, with intact MLH1 and PMS2. BRAF V600E is negative for this case. All images are 10x magnification. (A) H&E, (B) negative control antibody, (C) MLH1, (D) PMS2, (E) MSH2, (F) MSH6 and (G) BRAF V600E staining. All images are at 10x magnification.