

Case Report

A Case of a Giant Sublingual Epidermoid Cyst Removed by Content Reducing Surgery

Hiroshi Hikasa ^{1,2}, Ken-ichiro Sakata ^{1,2,*} , Takayuki Mizuno ¹, Takumi Kato ¹, Yoshimasa Kitagawa ² and Noriyuki Sakakibara ¹

¹ Department of Oral and Maxillofacial Surgery, Nikko Memorial Hospital, Muroran 051-8501, Japan; hiroshi.hikasa@gmail.com (H.H.); takayuki.mizuno@nikko-kinen.or.jp (T.M.); takumi.kato@nikko-kinen.or.jp (T.K.); noriyuki.sakakibara@nikko-kinen.or.jp (N.S.)

² Oral Diagnosis and Medicine, Division of Oral Pathobiological Science, Graduate School of Dental Medicine, Hokkaido University, Sapporo 060-8586, Japan; ykitagaw@den.hokudai.ac.jp

* Correspondence: sakata-0303@den.hokudai.ac.jp

Abstract: The frequency of epidermoid cysts in the maxillofacial region is relatively low. Reported: a case of a giant sublingual epidermoid cyst on the floor of the mouth. Case: 38-year-old woman. Chief complaint: oral swelling and respiratory distress. History of present illness: no special notes. Current medical history: she was aware of swelling of the floor of the mouth six months before visiting our department and was referred to our department because of increasing size. Present symptoms: at the time of examination, forced respiration and dysarthria were observed and a spherical soft elastic and well-defined mass was observed on the floor of the mouth. Due to the lesion, the tongue was displaced to the pharyngeal side and the tip of the tongue could not be confirmed. Imaging tests revealed a 65 mm × 76 mm × 54 mm well-defined mass on the mylohyoid muscle, and a dermoid or epidermoid cyst was suspected. Based on the clinical diagnosis of the cyst, the bulk of the cyst contents was reduced under general anesthesia, and the cyst was removed by intraoral surgery. The pathological diagnosis was an epidermoid cyst. For sublingual giant epidermoid cysts, removal by content reducing surgery was considered to be effective.

Keywords: epidermoid cyst; intraoral surgery; content reducing surgery



Citation: Hikasa, H.; Sakata, K.-i.; Mizuno, T.; Kato, T.; Kitagawa, Y.; Sakakibara, N. A Case of a Giant Sublingual Epidermoid Cyst Removed by Content Reducing Surgery. *Oral* **2022**, *2*, 126–136. <https://doi.org/10.3390/oral2010013>

Academic Editor: Andrea Santarelli

Received: 19 January 2022

Accepted: 3 March 2022

Published: 8 March 2022

Publisher's Note: MDPI stays neutral with regard to jurisdictional claims in published maps and institutional affiliations.



Copyright: © 2022 by the authors. Licensee MDPI, Basel, Switzerland. This article is an open access article distributed under the terms and conditions of the Creative Commons Attribution (CC BY) license (<https://creativecommons.org/licenses/by/4.0/>).

1. Introduction

Epidermoid cysts and dermoid cysts can occur in any part of the body due to embryonic developmental disorders or acquired epithelium due to trauma or inflammation [1]. More than 80% of epidermoid cysts are identified as 30 mm or less, but giant cysts have occasionally been reported [2]. These lesions rarely occur in the head and neck with an incidence ranging from 1.6 to 6.9%, and they represent less than 0.01% of all oral cavity cysts [3–5]. Here, we report a large sublingual epidermoid cyst on the floor of the mouth excised by a using an intraoral method combined with content reducing surgery.

2. Case Presentation

The patient was a 38-year-old female who first visited our department with chief complaints of dysarthria, eating disorders, and respiratory discomfort.

She noticed swelling of the floor of the mouth that gradually increased six months before the first visit to our department.

She lost 6 kg in weight during the six-month period when the size of the mass on the oral floor increased. She was slender, 158 cm tall, weighed 39 kg, and had a BMI of 15.6. Respiratory status was SpO₂ 96% with forced breathing. A soft elastic mass filling the entire oral cavity was found under the mucosa of the oral floor and she had difficulty closing her mouth (Figure 1A,B).

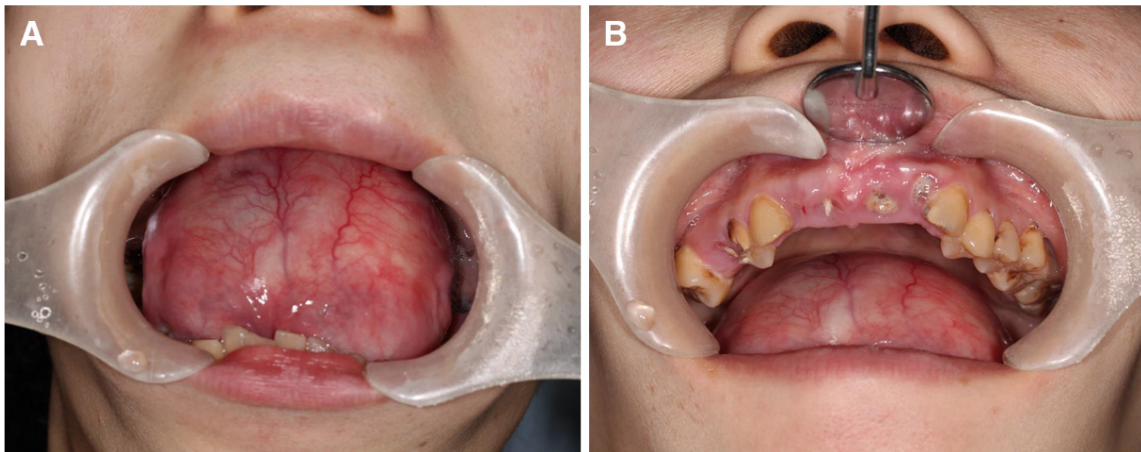


Figure 1. (A) Intraoral photograph at the first visit. (B) The tongue was displaced to the pharyngeal side by the giant cyst.

A mass of 40 mm × 30 mm was found in the median floor of the mouth, causing dysarthria and eating disorders.

The tongue was displaced posteriorly and the position of the tongue tip could not be confirmed, making it difficult to inspect the entire mass. The surface was smooth and the content of the mass could not be seen.

Computed tomography (CT) revealed a clearly defined cystic lesion with maximum dimensions of 65 mm × 76 mm × 54 mm that was observed on the hyoid muscle from the median floor to the septum of the tongue (Figure 2A–C).

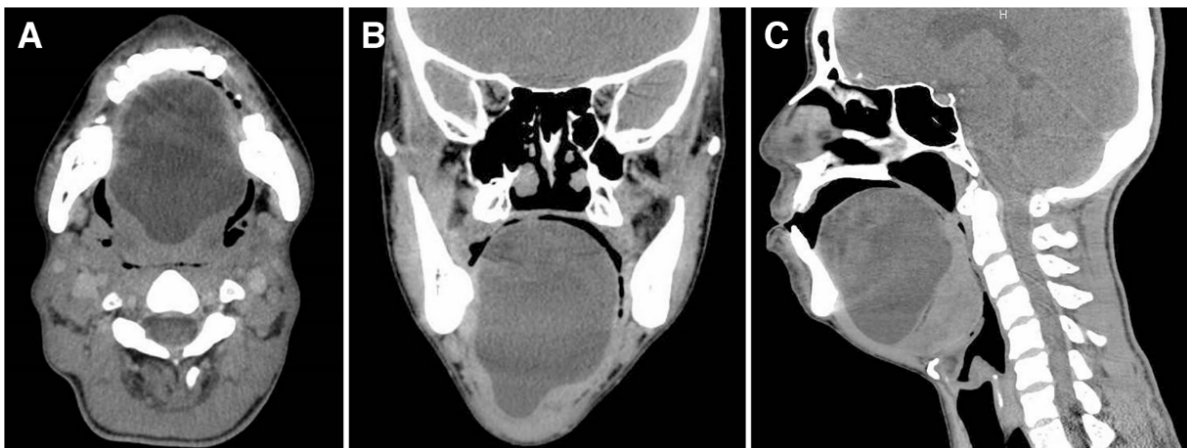


Figure 2. CT findings. (A–C) A well-defined cystic lesion with a maximum diameter of 75 mm was found on the mylohyoid muscle.

Magnetic resonance imaging (MRI) showed a low signal at T1 and a high signal at T2 and showed a contrast effect only around the disease lesion (Figure 3A–C). Diffusion-weighted images showed an increase in the internal signal and a decrease in the diffusion coefficient, suggesting an increase in the internal viscosity (Figure 3D,E).

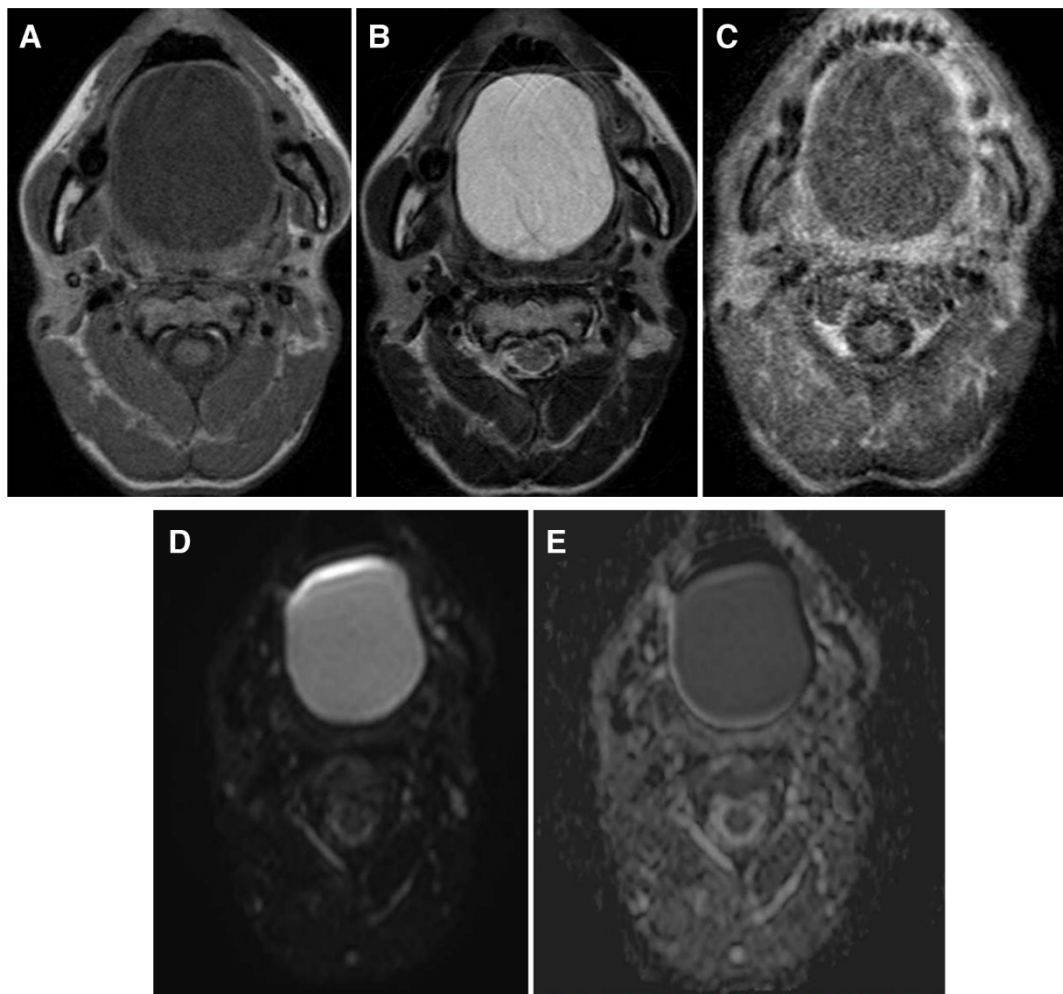


Figure 3. MRI findings. (A) Low signal at T1. (B) High signal at T2. (C) Contrast effect only around lesion. (D) Diffusion weighted image. (E) Apparent diffusion coefficient image.

Clinical and radiographic findings suggested an epidermoid or dermoid cyst (sublingual type). Monitoring at the time of admission revealed that SpO₂ declined repeatedly during nighttime sleep. With a decrease in SpO₂, the patient was diagnosed with second-degree atrioventricular block and QT prolonged syndrome. It was pointed out that hypoxia due to sleep apnea could worsen the atrioventricular block and a temporary extracorporeal pacemaker was inserted as a preoperative procedure the day before the operation. General anesthesia was performed by nasal intubation using a fiberscope and ultrasound. The tumor was so large that it was difficult to secure a visual field of view and to perform surgery. Removal of the entire cyst by surgical resection using an intraoral method combined with content reducing surgery was planned.

Since it was difficult to secure a field of view and to perform surgery due to the large size of the tumor, a part of the tumor was opened to reduce the content. A 15 mm incision was added to the clearly indicated cyst wall to reduce the content (Figure 4A,B).

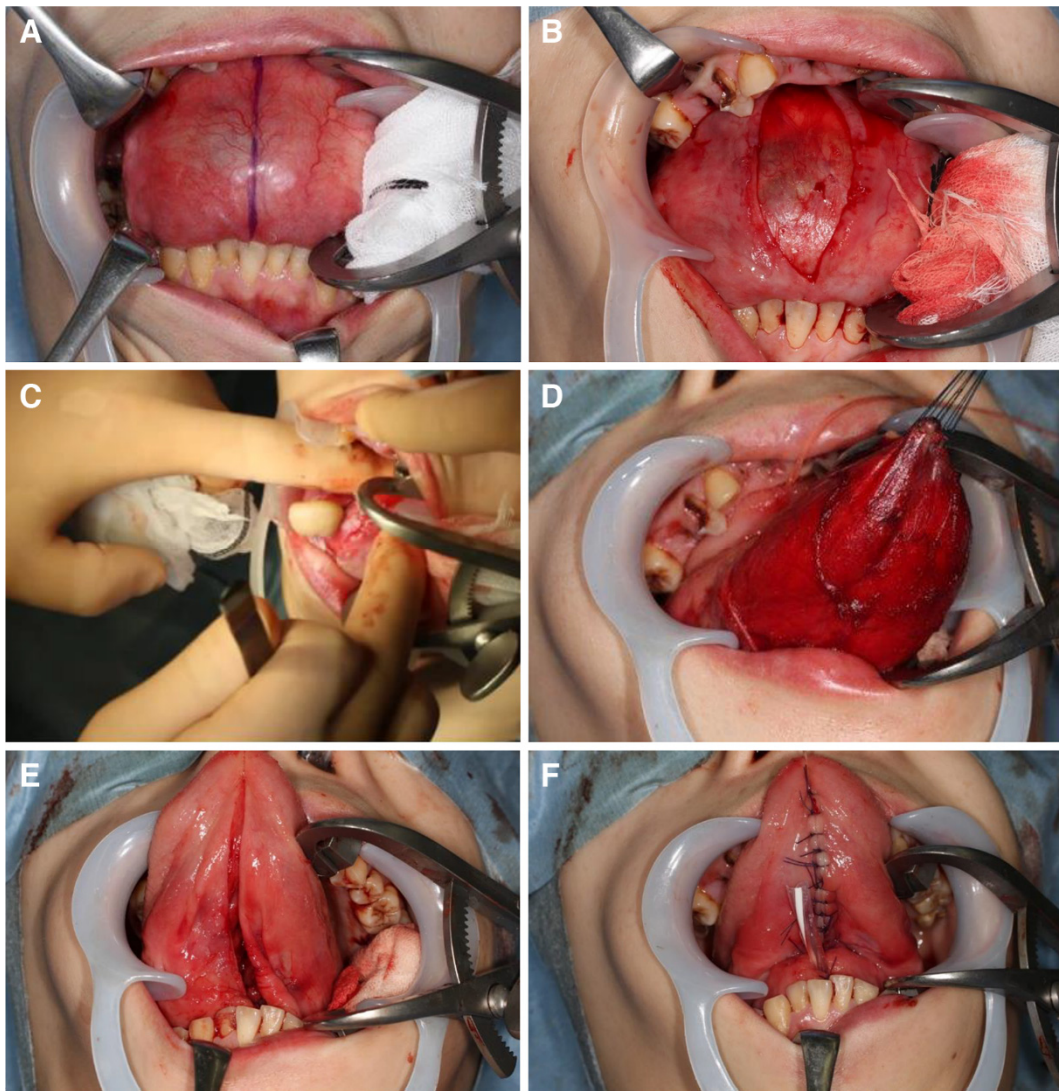


Figure 4. Intraoperative images. The cyst was reduced in size by removing contents to obtain a field of view and the necessary space to perform the surgery. (A,B) A 15 mm incision made in cyst wall. (C) Milky-white contents removed. (D) Posterior detachment while pulling. (E,F) Wound closed and a Penrose drain placed.

Milky-white mud-like contents were observed coming from inside the cyst (Figure 4C). After reducing the size, the incision in the cyst wall was sutured with nylon thread, and the posterior detachment was advanced while pulling (Figure 4D). If an operative field of view could not be obtained, the content was again reduced as necessary to proceed with the exfoliation.

The inferior aspect of the tongue and the cyst wall were easily detached, but the mylohyoid muscle and the genioglossus muscle were partly adhered making detachment difficult.

Following cystectomy, the wound was closed and a Penrose drain was placed (Figure 4E,F).

The total mass of the cyst was 105 g, and the size of the cyst was equivalent to one baseball ball (Figure 5A,B). The patient was returned to the ICU without extubation because there was concern regarding airway closure due to postoperative bleeding and swelling of the wound.

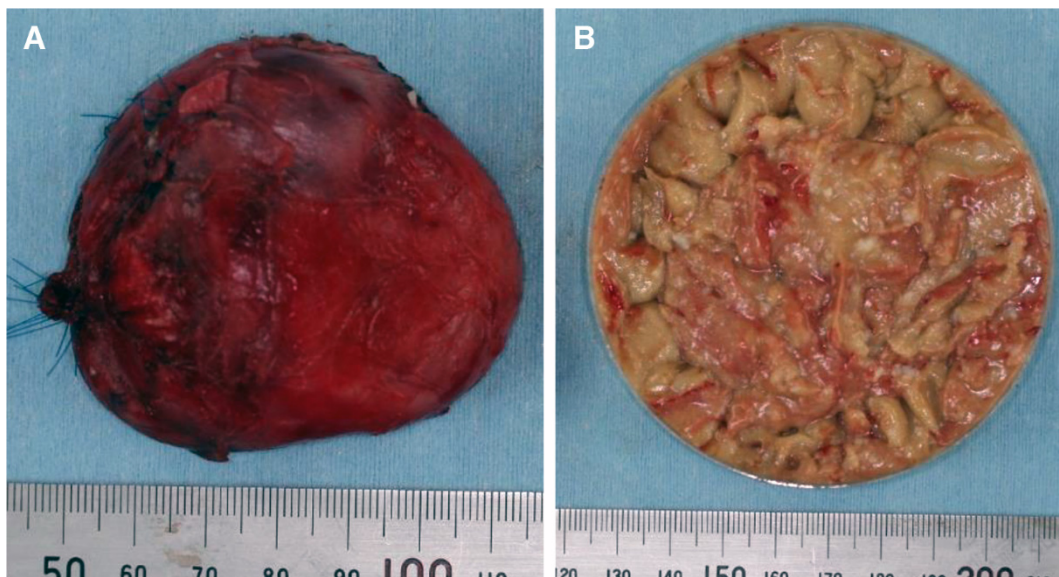


Figure 5. (A) Removed cyst, weight 105 g. (B) Milky-white mud-like contents of cyst.

3. Histological Diagnosis

Histopathology confirmed an epidermoid cyst lined with squamous cells without any skin adnexa. A layered keratinized substance was found in the lumen (Figure 6A–D).

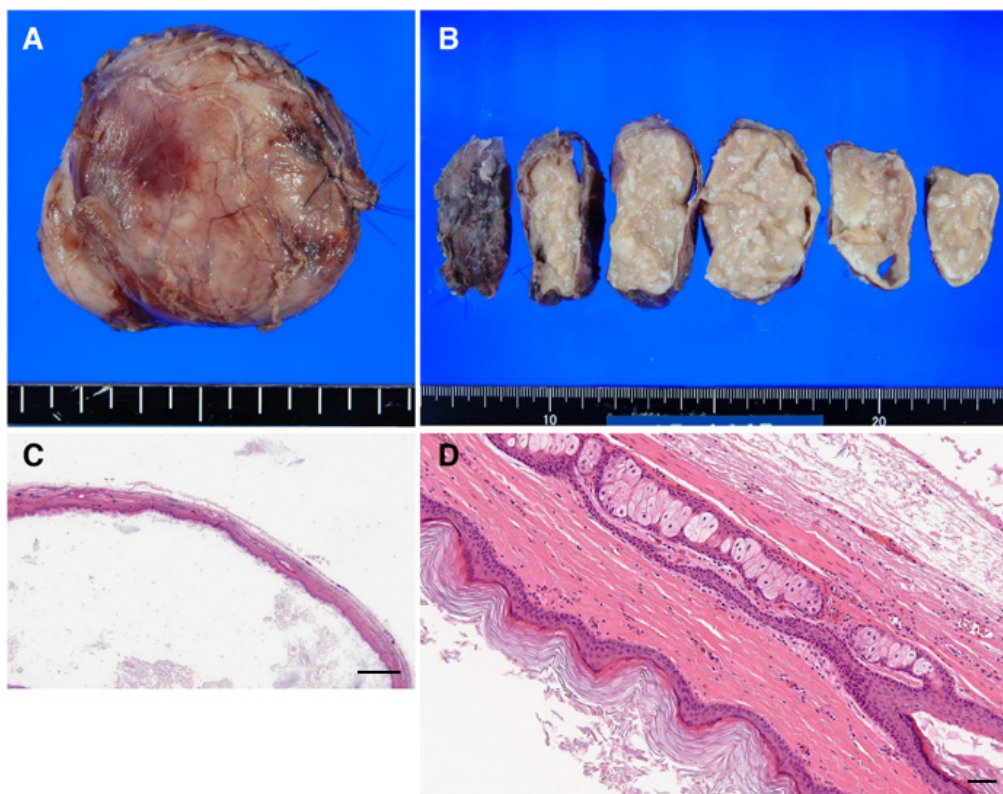


Figure 6. Histological images of epidermoid cyst. (A,B) Macroscopic view of epidermoid cyst. (C) Cyst with keratinized squamous epithelium (H-E \times 20, Bar 100 μ m). (D) A keratinized substance was found in the cyst cavity (H-E \times 200, Bar 100 μ m).

Swallowing training was started on the 6th postoperative day, and on the 17th postoperative day, the patient was transferred to the cardiology department for pacemaker implantation. She was discharged on the 25th postoperative day due to good progress.

Figure 7A,B shows intraoral photographs taken 4 months after the operation. There were no cyst recurrences, dysarthria or dysphagia, and functional recovery was observed. Follow-up was planned on an outpatient basis but the patient discontinued examination on their own accord.

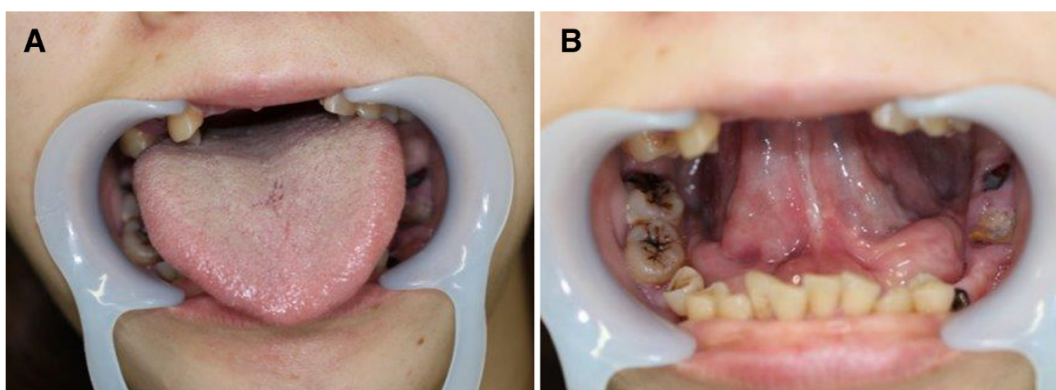


Figure 7. (A,B) Four months after surgery. Swallowing function and articulation function improved and the course was good.

4. Discussion

In general, the histological classification of this cyst is determined by Meyer's classification [6]. They can be classified as epidermoid (lined with simple squamous epithelium), dermoid (when skin adnexa are found in the cyst wall) or teratoid (when other tissues, such as muscle, cartilage and bone are present). This case was diagnosed as an epidermoid cyst because there was no skin adnexa.

It has been reported that the onset of cysts tend to increase at the age when the activity of skin adnexa such as sebaceous glands and sweat glands are activated and are often observed after puberty [6]. Epidermoid cells do not have skin adnexa, it is thought that there is a tendency to increase autonomously at the same time as the cell [2]. In this case, subjective symptoms occurred in the late thirties, and no history of trauma or inflammation was observed. Therefore the cause was unknown. Surgical excision is generally selected as the method of treatment [2]. Although there are reports of recurrence in cases where the capsule remains at the time of removal, there are no reports of recurrence after total removal [2].

Many reports have been made on the size of this type of cyst [7]. This cyst is slow growing and does not cause any dysfunction (dysphonia, dysphagia, dyspnea, or mastication disorders) until it is relatively large [8]. As a result, the period of time until a hospital visit is delayed, and the cyst at that time is often huge [9].

In some instances, where the differential diagnosis of sublingual swellings is more challenging, imaging techniques may be used for preoperative diagnosis and surgical planning [10]. MRI and CT allow more precise localization of the lesion, and also enable the surgeon to choose the most appropriate approach [10]. Characteristics upon imaging show that CT images have an encapsulated low-signal similar to adipose tissue and often show a contrast effect around the cyst. An MRI image with a high signal on T2 and a low signal on T1-weighted imaging typically indicates the presence of cystic structures [11].

In this case as well, CT images showed a relatively thick capsule-like structure around the lesion and MRI images showed a low signal at T1 and a high signal at T2. The contrast effect was observed only around the lesion.

According to the anatomic relationship between the cyst and the muscles of the floor of the mouth, epidermoid cysts can be designated as: submental (between geniohyoid

and mylohyoid muscles), sublingual (above mylohyoid and genioglossal muscles), and submandibular (lateral to the musculature) [10,12]. In our case, the cyst was located above the mylohyoid muscle and designated as a sublingual type.

To identify patients who might develop dysfunction and to survey therapeutic methods, we examined dermoid and epidermoid cysts in the oral region with the assumption that these cysts have similar clinical features. Cases with descriptions of cyst size, dysfunction, and therapeutic methods were found using a search in PubMed, Google Scholar and CiteSeerX with “oral”, “sublingual”, “epidermoid”, and “dermoid” used as keywords. This search was performed by three authors and identified 56 reports over the 25 years from 1995 to 2020 (Table 1). There was no difference in sex, and the ages of the patients ranged from day 1 after birth to 60 years (mean: 15 years), indicating that dysfunction can develop in any age group. Histopathological type included 30 cases of dermoid cysts and 26 cases of epidermoid cysts. Larger cysts were associated with dysfunction and tended to undergo tracheostomy (4/56, 7%) before removal. The surgical methods selected included the extraoral method (4/56, 7%) and a combination extraoral and intraoral method (3/56, 5%). This study is inadequate due to lack of all item data, but past case experience has a lot of useful information.

In addition, there were no cases in which content reducing surgery was performed as in our case. The anatomical location of the cyst is the most significant factor when considering the selection of surgical method. The method is generally selected by the positional relationship with the mylohyoid muscle. The intraoral method is preferred for sublingual types, the extraoral method for submental types and a combination of intraoral and extraoral for submandibular types [10,12].

In principle, the treatment method for epidermoid cysts that have developed in the oral cavity is total excision including the cyst wall. Incision and puncture are not recommended because they may cause recurrence or infection [2]. However, there is no consensus on the surgical procedure for giant cysts, such as our case. Previous papers suggest the effectiveness of a combination of extraoral and intraoral approaches. The method used in our case of making a vertical incision in the midline of the sublingual and reducing the amount of cyst contents was considered to be a good method without damage to the Wharton’s canal or nerves. Kobayashi et al. [2] reported that the cause of recurrence was damage to the cyst wall during excision. In our case, the cyst was incised to reduce the size of the cyst during the excision, but the site of the incision was made in a location that had already been detached. Therefore, we considered that it would not increase the risk of recurrence.

It is necessary to carefully consider the location of the lesion, securing an operative field of view, the possibility of wound infection by the intraoral method, the aesthetic affects caused by the extraoral method, and the possibility of damage to surrounding tissues, taking into consideration age and gender. As in this case, the case of a relatively young woman, the scar formation caused by a tracheostomy was also a cause for concern. It should also be taken into consideration that endotracheal intubation is difficult during general anesthesia. In our case, the tongue base was displaced posteriorly, and normal oral intubation was not possible for laryngeal deployment. Therefore, nasal intubation under bronchial fiberscope was performed. After the operation, intubation management was performed in the ICU, but we feel that for safer anesthesia management and postoperative management, it is necessary to consider respiratory management by tracheostomy.

Table 1. List of cases: oral dermoid and epidermoid cysts.

Year	Author	Age (Years)	Sex	Disease Duration (Months)	Tracheostomy	Category ¹	Size (mm)	Surgical Method	Reduction Performed	Dysarthria	Dysphagia	Breathing Disorder
1999	Obiechina [13]	5	M	60	(-)	D	45 × 50 × 35	intraoral	(-)	(+)	(+)	(-)
2003	Ho [11]	0.125 (1.5 months)	M	0.07	(-)	D	11 × 10 × 7	intraoral	(-)	(-)	(+)	(-)
2004	Seah [14]	19	M	0.1	(-)	D	35 × 26	intraoral	(-)	(-)	(-)	(-)
2007	Jham [15]	25	M	2	(-)	E	50 × 50	intraoral	(-)	(+)	(+)	(-)
2008	El-Hakim [16]	22	M	120	(-)	D	120 × 120	extraoral	(-)	(+)	(-)	(-)
2009	Papadogeorgakis [17]	21	F	120	(+)	D	75 × 55 × 35	intraoral/extraoral	(-)	(+)	(+)	(+)
2009	Tsirevelou [18]	14	F	120	(-)	E	14 × 12	intraoral	(-)	(-)	(-)	(-)
2009	Patil [19]	28	M	5	(-)	E	30 × 20 × 20	intraoral	(-)	(-)	(-)	(-)
2009	Jadwani [20]	22	M	12	(-)	D	40 × 20	intraoral	(-)	(-)	(-)	(-)
2010	Anantanarayanan [21]	12	F	12	(-)	E	40	intraoral	(-)	(+)	(-)	(-)
2011	Pan [22]	0.4 (5 months)	M	0	(-)	D	30 × 20 × 10	intraoral	(-)	(+)	(-)	(+)
2012	Jain [23]	17	F	48	(-)	D	90 × 90	intraoral	(-)	(-)	(+)	(+)
2012	Ohta [24]	21	F	24	(+)	D	55 × 56 × 45	intraoral	(-)	(-)	(+)	(-)
2012	Assaf [25]	39	M	no data	(-)	E	no data	intraoral	(-)	(+)	(+)	(+)
2012	Verma [26]	16	F	5	(-)	E	70 × 50 × 45	intraoral	(-)	(-)	(+)	(-)
2013	Dutta [27]	23	F	360	(+)	E	75 × 60 × 45	extraoral	(-)	(+)	(+)	(-)
2013	Dutta [27]	36	M	60	(-)	E	60 × 40 × 30	intraoral	(-)	(-)	(-)	(-)
2014	Aydin [28]	30	M	36	(-)	D	36 × 39	intraoral	(-)	(-)	(-)	(-)
2014	Oginni [29]	0.67 (8 months)	no data	0.9	(-)	E	40 × 30	intraoral	(-)	(-)	(-)	(-)
2014	Viera [30]	29	M	no data	(-)	D	45 × 55	intraoral	(-)	no data	no data	no data
2014	Yoshida [31]	39	F	48	(-)	E	95 × 80 × 40	intraoral	(-)	(+)	(-)	(+)
2015	Gordon [32]	79	F	300	(-)	D	53 × 29 × 27	intraoral	(-)	(-)	(-)	(-)
2015	Kyriakidou [7]	17	F	3	(-)	D	60 × 50 × 35	intraoral	(-)	(+)	(-)	(-)
2015	Gulati [33]	16	M	3	(-)	E	62 × 60 × 57	intraoral/extraoral	(-)	(-)	(+)	(-)
2015	Dabán [34]	3	F	2	(-)	E	20 × 15	intraoral	(-)	(-)	(-)	(-)
2016	Nishar [35]	60	M	360	(+)	E	100 × 80	extraoral	(-)	(-)	(-)	(-)
2016	Berbel [8]	8	F	36	(-)	D	60 × 50	intraoral	(-)	(+)	(-)	(-)

Table 1. Cont.

Year	Author	Age (Years)	Sex	Disease Duration (Months)	Tracheostomy	Category ¹	Size (mm)	Surgical Method	Reduction Performed	Dysarthria	Dysphagia	Breathing Disorder
2017	Basterzi [36]	10	M	no data	(-)	E	30 × 40 × 40	extraoral	(-)	(-)	(+)	(+)
2018	Brunet-Garcia [37]	43	M	24	(-)	D	40 × 32 × 34	intraoral	(-)	(-)	(-)	(-)
2019	Silveira [38]	26	M	24	(-)	E	70 × 70	intraoral	(-)	(+)	(+)	(-)
2020	Baliga [39]	26	F	36	(-)	E	30	intraoral	(-)	(+)	(+)	(-)
2020	Oluleke [40]	0.002 (1 day)	M	Birth	(-)	D	no data	intraoral	(-)	(-)	(+)	(+)
2020	Oluleke [40]	0.002 (1 day)	F	Birth	(-)	D	no data	intraoral	(-)	(-)	(+)	(+)
2020	Oluleke [40]	0.002 (1 day)	M	Birth	(-)	D	no data	intraoral	(-)	(-)	(+)	(+)
2020	Oluleke [40]	0.002 (1 day)	M	Birth	(-)	D	no data	intraoral	(-)	(-)	(+)	(+)
2020	Oluleke [40]	0.002 (1 day)	F	Birth	(-)	D	no data	intraoral	(-)	(-)	(+)	(+)
2020	Oluleke [40]	0.16	M	2	(-)	D	no data	intraoral	(-)	(-)	(+)	(+)
2020	Oluleke [40]	1	F	12	(-)	D	no data	intraoral	(-)	(-)	(+)	(+)
2020	Oluleke [40]	7	M	84	(-)	E	no data	intraoral	(-)	(-)	(-)	(+)
2020	Oluleke [40]	9	M	108	(-)	E	no data	intraoral	(-)	(-)	(-)	(-)
2020	Oluleke [40]	10	F	120	(-)	E	no data	intraoral	(-)	(-)	(-)	(-)
2020	Oluleke [40]	13	M	156	(-)	E	no data	intraoral	(-)	(-)	(-)	(-)
2020	Misch [41]	12	F	no data	(-)	D	54 × 38 × 41	intraoral	no data	no data	no data	no data
2020	Misch [41]	8	F	no data	(-)	D	14 × 10 × 15	intraoral	no data	no data	no data	no data
2020	Misch [41]	1	F	no data	(-)	E	4 × 4 × 2	intraoral	no data	no data	no data	no data
2020	Misch [41]	16	F	no data	(-)	D	44 × 21 × 26	intraoral	no data	no data	no data	no data
2020	Misch [41]	11	M	no data	(-)	D	43 × 20 × 28	intraoral	no data	no data	no data	no data
2020	Misch [41]	0.17	M	no data	(-)	E	22 × 16 × 20	intraoral	no data	no data	no data	no data
2020	Misch [41]	14	F	no data	(-)	D	37 × 38 × 31	intraoral	no data	no data	no data	no data
2020	Misch [41]	8	F	no data	(-)	D	19 × 12 × 24	intraoral	no data	no data	no data	no data
2020	Misch [41]	0.5	M	no data	(-)	E	6 × 5 × 5	intraoral	no data	no data	no data	no data
2020	Misch [41]	2	F	no data	(-)	D	10 × 10 × 10, 12 × 10 × 12	intraoral/extraoral	no data	no data	no data	no data
2020	Misch [41]	6	F	no data	(-)	E	12 × 11 × 5	intraoral	no data	no data	no data	no data
2020	Misch [41]	3	M	no data	(-)	E	6 × 5 × 3	intraoral	no data	no data	no data	no data
2020	Klibngern [42]	26	F	no data	(-)	E	65 × 32 × 25	intraoral	(-)	(+)	(+)	(+)
2020	Vélez-Cruz [43]	0.58	F	8	(-)	D	25 × 20 × 10	intraoral	(-)	(-)	(+)	(-)
	Present Case: Hikasa	38	F	6	(-)	E	65 × 76 × 54	intraoral	(-)	(+)	(+)	(+)

¹ Category: dermoid (D), epidermoid (E).

5. Conclusions

We reported on a giant sublingual epidermoid cyst excised by a using an intraoral method combined with content reducing surgery. During surgery, it is necessary to consider the size of the cyst, anatomical positional relationship, and securing an operative field of view for extirpation. Furthermore, postoperative respiratory management should also be considered.

Author Contributions: H.H., K.-i.S., T.M., T.K. and N.S. participated directly in the care and diagnosis of the patient; Y.K. and N.S. conducted the review and editing; H.H. and K.-i.S. visualized; and H.H. wrote the paper. All authors have read and agreed to the published version of the manuscript.

Funding: This research received no external funding.

Informed Consent Statement: Informed consent was obtained from all subjects involved in the study.

Data Availability Statement: Data are contained within the article.

Acknowledgments: We would like to give my heartfelt thanks to Sakakibara, whose comments and suggestions were innumerable valuable throughout the course of my study. We are also in debt to Kitagawa, whose meticulous comments were an enormous help to me. We would also like to express my gratitude to my family for their moral support and warm encouragement.

Conflicts of Interest: The authors declare no conflict of interest.

References

1. New, G.B.; Erich, J.B. Dermoid cysts of the head and neck. *Surg. Gynecol. Obs.* **1937**, *65*, 48–55.
2. Kobayashi, Y.; Kino, K.; Manita, H.; Satou, R.; Kikuchi, K.; Yoshimasu, H.; Amagasa, T. Clinical Observation of Dermoid Cyst and Epidermoid Cyst in the Oral and Maxillofacial Region. *J. Jpn. Stomatol. Soc.* **1998**, *47*, 101–107.
3. Ege, G.; Akman, H.; Senvar, A.; Kuzucu, K. Case report: Sublingual dermoid cyst. *Tani. Gir. Radyol.* **2003**, *9*, 57–59.
4. De Ponte, F.S.; Brunelli, A.; Marchetti, E.; Bottini, D. Sublingual epidermoid cyst. *J. Craniofac. Surg.* **2002**, *13*, 308–310. [[CrossRef](#)] [[PubMed](#)]
5. Kandogan, T.; Koc, M.; Vardar, E.; Selek, E.; Sezgin, O. Sublingual epidermoid cyst: A case report. *J. Med. Case Rep.* **2007**, *1*, 87. [[CrossRef](#)]
6. Meyer, I. Dermoid cysts (dermoids) of the floor of the mouth. *Oral Surg. Oral Med. Oral Pathol.* **1955**, *8*, 1149–1164. [[CrossRef](#)]
7. Kyriakidou, E.; Howe, T.; Veale, B.; Atkins, S. Sublingual dermoid cysts: Case report and review of the literature. *J. Laryngol. Otol.* **2015**, *129*, 1036–1039. [[CrossRef](#)]
8. Berbel, P.; Ostrosky, A.; Tosti, F. Large Sublingual Dermoid Cyst: A Case of Mandibular Prognathism. *Craniofacial Trauma Reconstr.* **2016**, *9*, 345–348. [[CrossRef](#)]
9. Ueda, M.; Dehari, H.; Nakamori, K.; Shiratori, K.; Suzuki, R.; Hiratsuka, H. A case of a large epidermoid cyst in the floor of the mouth associated with dyspnea. *Jpn. J. Oral Maxillofac. Surg.* **2010**, *56*, 476–479. [[CrossRef](#)]
10. Longo, F.; Maremonti, P.; Mangone, G.M.; De Maria, G.; Califano, L. Midline (dermoid) cysts of the floor of the mouth: Report of 16 cases and review of surgical techniques. *Plast. Reconstr. Surg.* **2003**, *112*, 1560–1565. [[CrossRef](#)]
11. Ho, M.W.; Crean, S.J. Simultaneous occurrence of sublingual dermoid cyst and oral alimentary tract cyst in an infant: A case report and review of the literature. *Int. J. Paediatr. Dent.* **2003**, *13*, 441–446. [[CrossRef](#)] [[PubMed](#)]
12. Di Francesco, A.; Chiapasco, M.; Biglioli, F.; Ancona, D. Intraoral approach to large dermoid cysts of the floor of the mouth: A technical note. *Int. J. Oral Maxillofac. Surg.* **1995**, *24*, 233–235. [[CrossRef](#)]
13. Obiechina, A.E.; Arotiba, J.T.; Ogunbiyi, J.O. Coexisting congenital sublingual dermoid and bronchogenic cyst. *Br. J. Oral Maxillofac. Surg.* **1999**, *37*, 58–60. [[CrossRef](#)] [[PubMed](#)]
14. Seah, T.E.; Sufyan, W.; Singh, B. Case report of a dermoid cyst at the floor of the mouth. *Ann. Acad. Med. Singap.* **2004**, *33* (Suppl. 4), 77–79. [[PubMed](#)]
15. Jham, B.C.; Duraes, G.V.; Jham, A.C.; Santos, C.R. Epidermoid cyst of the floor of the mouth: A case report. *J. Can. Dent. Assoc.* **2007**, *73*, 525–528. [[PubMed](#)]
16. El-Hakim, I.E.; Alyamani, A. Alternative surgical approaches for excision of dermoid cyst of the floor of mouth. *Int. J. Oral Maxillofac. Surg.* **2008**, *37*, 497–499. [[CrossRef](#)]
17. Papadogeorgakis, N.; Kalfarentzos, E.F.; Vourlakou, C.; Alexandridis, C. Surgical management of a large median dermoid cyst of the neck causing airway obstruction. *Case Rep. Oral Maxillofac. Surg.* **2009**, *13*, 181–184. [[CrossRef](#)]
18. Tsirevelou, P.; Papamantinos, M.; Chlopsidis, P.; Zourou, I.; Skoulakis, C. Epidermoid cyst of the floor of the mouth: Two case reports. *Cases J.* **2009**, *2*, 9360. [[CrossRef](#)]
19. Patil, K.; Mahima, V.G.; Malleshi, S.N. Sublingual epidermoid cyst: A case report. *Cases J.* **2009**, *2*, 8848. [[CrossRef](#)]

20. Jadwani, S.; Misra, B.; Kallianpur, S.; Bansod, S. Dermoid cyst of the floor of the mouth with abundant hair: A case report. *J. Maxillofac. Oral Surg.* **2009**, *8*, 388–389. [[CrossRef](#)]
21. Anantanarayanan, P.; Manikandhan, R.; Bhargava, D.; Sivapathasundara, B. Sub-lingual epidermoid cyst. *Head Neck Pathol.* **2010**, *4*, 136–138. [[CrossRef](#)] [[PubMed](#)]
22. Pan, M.; Nakamura, Y.C.; Clark, M.; Eisig, S. Intraoral dermoid cyst in an infant: A case report. *J. Oral Maxillofac. Surg.* **2011**, *69*, 1398–1402. [[CrossRef](#)] [[PubMed](#)]
23. Jain, H.; Singh, S.; Singh, A. Giant sublingual dermoid cyst in floor of the mouth. *J. Maxillofac. Oral Surg.* **2012**, *11*, 235–237. [[CrossRef](#)] [[PubMed](#)]
24. Ohta, N.; Watanabe, T.; Ito, T.; Kubota, T.; Suzuki, Y.; Ishida, A.; Kakehata, S.; Aoyagi, M. A case of sublingual dermoid cyst: Extending the limits of the oral approach. *Case Rep. Otolaryngol.* **2012**, *2012*, 634949. [[CrossRef](#)] [[PubMed](#)]
25. Assaf, A.T.; Heiland, M.; Blessmann, M.; Friedrich, R.E.; Zustin, J.; Al-Dam, A. Extensive sublingual epidermoid cyst—diagnosis by immunohistological analysis and proof by podoplanin. *In Vivo* **2012**, *26*, 323–326. [[PubMed](#)]
26. Verma, S.; Kushwaha, J.K.; Sonkar, A.A.; Kumar, R.; Gupta, R. Giant sublingual epidermoid cyst resembling plunging ranula. *Natl. J. Maxillofac. Surg.* **2012**, *3*, 211–213. [[CrossRef](#)] [[PubMed](#)]
27. Dutta, M.; Saha, J.; Biswas, G.; Chattopadhyay, S.; Sen, I.; Sinha, R. Epidermoid cysts in head and neck: Our experiences, with review of literature. *Indian J. Otolaryngol. Head Neck Surg.* **2013**, *65* (Suppl. 1), 14–21. [[CrossRef](#)]
28. Aydın, S.; Demir, M.G.; Demir, N.; Şahin, S.; Kayıpmaz, S.S. A Giant Plunging Sublingual Dermoid Cyst Excised by Intraoral Approach. *J. Maxillofac. Oral Surg.* **2016**, *15*, 277–280. [[CrossRef](#)]
29. Oginni, F.O.; Oladejo, T.; Braimah, R.O.; Adenekan, A.T. Sublingual epidermoid cyst in a neonate. *Ann. Maxillofac. Surg.* **2014**, *4*, 96–98. [[CrossRef](#)]
30. Vieira, E.M.M.; Borges, A.H.; Volpato, L.E.R.; Porto, A.N.; Carvalhosa, A.A.; Botelho, G.A.; Bandeca, M.C. Unusual dermoid cyst in oral cavity. *Case Rep. Pathol.* **2014**, *2014*, 389752. [[CrossRef](#)]
31. Yoshida, N.; Kodama, K.; Iino, Y. Sublingual epidermoid cyst presenting with distinctive magnetic resonance imaging findings. *Clin. Pract.* **2014**, *4*, 664. [[CrossRef](#)] [[PubMed](#)]
32. Gordon, P.E.; Faquin, W.C.; Lahey, E.; Kaban, L.B. Floor-of-mouth dermoid cysts: Report of 3 variants and a suggested change in terminology. *J. Oral Maxillofac. Surg.* **2013**, *71*, 1034–1041. [[CrossRef](#)] [[PubMed](#)]
33. Gulati, U.; Mohanty, S.; Augustine, J.; Gupta, S.R. Potentially fatal supramylohyoid sublingual epidermoid cyst. *J. Maxillofac. Oral Surg.* **2015**, *2015* (Suppl. 1), 355–359. [[CrossRef](#)] [[PubMed](#)]
34. Dabán, R.P.; Díez, E.G.; Navarro, B.G.; López-López, J. Epidermoid cyst in the floor of the mouth of a 3-year-old. *Case Rep. Dent.* **2015**, *2015*, 172457. [[CrossRef](#)]
35. Nishar, C.C.; Ambulgekar, V.K.; Gujrathi, A.B.; Chavan, P.T. Unusually Giant Sublingual Epidermoid Cyst: A Case Report. *Iran J. Otorhinolaryngol.* **2016**, *28*, 291–296.
36. Basterzi, Y.; Sari, A.; Ayhan, S. Giant Epidermoid Cyst on the Forefoot. *Dermatol. Surg.* **2002**, *28*, 639–640.
37. Brunet-Garcia, A.; Lucena-Rivero, E.; Brunet-Garcia, L.; Faubel-Serra, M. Cystic mass of the floor of the mouth. *J. Clin. Exp. Dent.* **2018**, *10*, e287–e290. [[CrossRef](#)]
38. Silveira, H.A.; Almeida, L.Y.; Dominguet, M.H.L.; Graciano, K.P.P.; Bufalino, A.; León, J.E. Intraoral epidermoid cyst with extensive elastofibromatous changes: An unusual finding. *Oral Maxillofac. Surg.* **2019**, *23*, 493–497. [[CrossRef](#)]
39. Baliga, M.; Shenoy, N.; Poojary, D.; Mohan, R.; Naik, R. Epidermoid cyst of the floor of the mouth. *Natl. J. Maxillofac. Surg.* **2014**, *5*, 79–83. [[CrossRef](#)]
40. Oluleke, O.O.; Akau, K.S.; Godwin, A.I.; Kene, A.I.; Sunday, A.O. Sublingual Dermoid Cyst: Review of 14 Cases. *Ann. Maxillofac. Surg.* **2020**, *10*, 279–283. [[CrossRef](#)]
41. Misch, E.; Kashiwazaki, R.; Lovell, M.A.; Herrmann, B.W. Pediatric sublingual dermoid and epidermoid cysts: A 20-year institutional review. *Int. J. Pediatr. Otorhinolaryngol.* **2020**, *138*, 110265. [[CrossRef](#)] [[PubMed](#)]
42. Klibngern, H.; Pornchaisakuldee, C. A large sublingual epidermoid cyst with parapharyngeal space extension: A case report. *Int. J. Surg. Case Rep.* **2020**, *72*, 233–236. [[CrossRef](#)] [[PubMed](#)]
43. Vélez-Cruz, M.E.; Gómez-Clavel, J.F.; Licéaga-Escalera, C.J.; Pérez, L.A.M.; Fandiño, J.J.T.; Iriarte, C.J.T.; Ramírez-Cano, M.F.; García-Muñoz, A. Sublingual dermoid cyst in an infant: A case report and review of the literature. *Clin. Case Rep.* **2020**, *8*, 1403–1408. [[CrossRef](#)] [[PubMed](#)]