


Review

The Science Behind Stress: From Theory to Clinic, Is Basal Septal Hypertrophy the Missing Link between Hypertension and Takotsubo Cardiomyopathy?

Boran Çağatay ¹, Fatih Yalçın ^{2,3,*}, Adnan Kırac ¹, Nagehan Küçükler ⁴ and Maria Roselle Abraham ³

¹ Medical School, Mustafa Kemal University, Antioch 31060, Türkiye; borancagatay1@gmail.com (B.Ç.); adnan-kirac@hotmail.com (A.K.)

² Department of Cardiology, Medical School, Mustafa Kemal University, Antioch 31060, Türkiye

³ Cardiac Imaging, Department of Cardiology, School of Medicine, UCSF HEALTH, San Francisco, CA 94143, USA; roselle.abraham@ucsf.edu

⁴ Department of Cardiology, Medical School, Akdeniz University, Antalya 07058, Türkiye; drnagehan@gmail.com

* Correspondence: fatih.yalcin@ucsf.edu

Abstract: The modern theory of stress, initially proposed by Hans Selye in 1956, signifies an important development in our understanding of this phenomenon. Selye's *The Stress of Life* serves as a foundational book for subsequent scientific questions. In this article, we focus on a comprehensive look at stress and use a literature review to explain its theoretical foundations as well as its clinical equivalent. Our research focuses on the complex mechanisms of stress, with a particular emphasis on the consequences of cardiac remodeling and adaptation processes. Myocardial remodeling might be seen as a response to increased stress in acute or chronic situations. Stressed heart morphology (SHM) is a very interesting description representing basal septal hypertrophy (BSH), which is detectable in both acute emotional stress and chronic stress due to increased afterload in hypertension. Acute stress cardiomyopathy (ASC) and hypertension in the same individuals could be clinically linked. Also, in this report, we mention the geometric and functional similarity of the left ventricle (LV) septal base in both acute and chronic clinical situations. Therefore, cardiac imaging methods are crucial to assessing LV segmental aspects in ASC patients. We propose a new paradigm that ASC may develop in hypertensive patients with SHM. We document the segmental progression of microscopic LV remodeling using a third-generation microscopic ultrasound and note that BSH takes a longer time to occur morphologically than an acutely developed syndrome. However, the majority of ASC events have a predominant base, and the absence of segmental remodeling details, including BSH and cardiac decompensation with apical ballooning, on echocardiographic reports may mask the possible underlying hypertensive disease. In fact, beyond ASC cases, previously undiagnosed hypertension is very common, even in developed countries, and is associated with masked target organ damage.

Keywords: acute stress cardiomyopathy; basal septal hypertrophy; hypertension; early imaging biomarker; stressed heart morphology



Citation: Çağatay, B.; Yalçın, F.; Kırac, A.; Küçükler, N.; Abraham, M.R. The Science Behind Stress: From Theory to Clinic, Is Basal Septal Hypertrophy the Missing Link between Hypertension and Takotsubo Cardiomyopathy? *Stresses* **2024**, *4*, 330–341. <https://doi.org/10.3390/stresses4020021>

Academic Editor: Nebojša Jasnić

Received: 28 March 2024

Revised: 9 May 2024

Accepted: 13 May 2024

Published: 15 May 2024



Copyright: © 2024 by the authors. Licensee MDPI, Basel, Switzerland. This article is an open access article distributed under the terms and conditions of the Creative Commons Attribution (CC BY) license (<https://creativecommons.org/licenses/by/4.0/>).

1. Background of Stress Theory

The concept of stress originates from the Latin “*estrictia*”, which in the 17th century denoted calamity, misfortune, affliction, trouble, sorrow, and grief. By the 18th and 19th centuries, it had evolved to encompass meanings related to force, pressure, and difficulty when applied to objects, individuals, organs, and mental structures [1].

The term “stress” is commonly used in contemporary culture to encompass both psychological and physiological responses arising from our lifestyles, work environments, and interactions within an increasingly intricate society. This understanding of stress, along with its experiences, has its roots, at least in part, in the “general adaptation syndrome”

initially introduced by Hans Selye over 85 years ago in his influential *Nature* publication. Selye emerged as the pioneer in identifying “stress” as the underlying factor behind the nonspecific indicators and symptoms of illness.

Selye found remarkable morphological changes related to stress in his animal studies, during which gathered cow ovaries for analysis and injected various extracts into female rats and observed their reactions. Surprisingly, autopsies revealed three key findings: enlarged adrenal glands, lymphatic system atrophy (including the thymus), and peptic ulcers in the stomach and duodenum. These outcomes were consistent across different noxious agents [2].

Selye proposed that stress is a constant presence in an individual throughout their exposure to a nonspecific demand. He made a distinction between acute stress and the overall response to chronically applied stressors, labeling the latter as ‘general adaptation syndrome’ or Selye’s syndrome. This syndrome breaks down the total response to stress into three phases: the alarm reaction, the stage of resistance, and the stage of exhaustion. Individuals, when confronted with a stressor, initially react with surprise, attempt to maintain homeostasis by resisting change, and eventually succumb to exhaustion in countering the stressor.

Importantly, stress, according to Selye’s perspective, is a series of orchestrated events and not merely a psychological term. It is experienced by all individuals during periods of illness [3].

2. Stressors and Associated Cardiac Diseases

The role of stress in contributing to the sustained elevation of blood pressure remains considerably less clear compared to the role of lifestyle factors, primarily owing to the inherent complexities associated with defining, perceiving, and subsequently measuring various aspects of stress, thereby posing significant challenges in elucidating its precise impact on cardiovascular health [4].

The differentiation between acute and chronic stress is somewhat arbitrary, as certain acute events can have enduring repercussions that extend beyond their initial occurrence. For example, acute stressful incidents like natural disasters, such as earthquakes, can lead to persistent effects that linger over time. Conversely, studies predominantly classified by the presence of chronic stressors entail recurring and prolonged exposure to stress-inducing factors, notably in occupational settings where individuals face repeated challenges and demands [5]. The most frequently scrutinized stressors in adults encompass challenges encountered in the workplace and social isolation, alongside supplementary factors such as marital discord, caregiving responsibilities for an ailing family member, and the bereavement associated with the loss of a close individual, all of which have been linked to an increased risk of cardiovascular disease. Additionally, natural and man-made disasters, such as earthquakes, terrorist attacks, and wars, have been correlated with clinical events and cardiac abnormalities. The episodic stressors under examination encompass emotional upheaval, participation in sporting events, and notable workplace transitions such as layoffs [6].

The influence of stress on the development of cardiovascular disease manifests over the long term. Childhood experiences such as physical abuse, household substance abuse, mental illness, sexual abuse, and domestic violence can leave enduring impacts, heightening the susceptibility to various chronic conditions in adulthood [7]. A meta-analysis demonstrated a higher risk of cardiovascular disease in individuals with at least four adverse childhood experiences. In the general adult population, associations between chronic stress and cardiovascular disease risk have been less pronounced. Studies have linked social isolation, loneliness, and work-related stressors to increased risks of coronary heart disease, stroke, and atrial fibrillation. Notably, long working hours and job strain have been associated with elevated risks of stroke and atrial fibrillation [7,8]. The experience of both physical and psychological stress has been associated with the development of depression and coronary heart disease. Considering that similar stressful conditions have

been shown to affect the physical properties of major arteries, such as the elasticity of aortic segments, it is reasonable to infer that these changes may be connected to alterations in the macromolecular composition of these arteries [9].

Stress has consistently emerged as a potential and significant contributor to hypertension, in conjunction with other risk factors such as low potassium intake, inadequate physical activity, and sleep disturbances. Although acute stress can induce temporary spikes in blood pressure, it remains unclear whether this effect translates into sustained hypertension over time [5]. The findings of the INTERHEART study, which highlighted stress as an independent risk factor for myocardial infarction, have reignited interest in stress as a risk factor for cardiovascular diseases. Stress is defined as a process wherein environmental demands surpass an organism's adaptive capacity, leading to psychological and physiological changes that may predispose individuals to disease [10].

Hypertension impacts roughly one-third of adults in the USA and stands as one of the most crucial cardiovascular risk factors that can be modified [11].

Extensive epidemiological investigations have provided compelling evidence regarding the substantial role of psychosocial risk factors, encompassing hostility, chronic psychosocial stress, nonadaptive coping, depression, work-related stress, and low socioeconomic status, in the etiology of hypertension. Consequently, interventions focusing on addressing these psychosocial determinants have emerged as a rational and imperative approach to optimizing blood pressure management and ameliorating the adverse health consequences associated with hypertension. By targeting these underlying psychosocial factors, healthcare practitioners can effectively enhance the effectiveness of hypertension management strategies and facilitate improved cardiovascular health outcomes for individuals afflicted by this condition [12]. Recent reviews indicate that psychosocial interventions employing multiple components of stress or anger management, typically incorporating cognitive-behavioral approaches along with meditative or other relaxation techniques, tend to be more effective in lowering blood pressure compared to single-modality interventions [13,14].

A comprehensive systematic review of cohort studies highlights the complex interplay between psychosocial factors and cardiovascular health in longitudinal analyses, highlighting a significant correlation between anxiety, depression, anger management, social support, and the onset of hypertension [15].

Moreover, the association between physical and mental stress and heightened levels of fatty acids and norepinephrine leads to an escalation in systemic vascular resistance, consequently culminating in elevated diastolic blood pressure. Although both physical and mental stress contribute to increased levels of fatty acids and norepinephrine, as well as minor fluctuations in blood pressure, the basal metabolic rate remains unaltered [16].

In cases of chronic stress where coping mechanisms prove effective, the vagal system is usually activated to reduce the secretion of stress mediators and restore autonomic activity to normal levels. Additionally, the binding of α_2 -adrenergic receptors triggers a negative feedback loop, leading to a decrease in norepinephrine levels [17]. Nevertheless, chronic stress, sleep deprivation or apnea, sedentary lifestyles, substance abuse, abdominal obesity, insulin resistance, hypertension, and depression can all induce chronic sympathetic hyperactivity, leading to a disruption of autonomic homeostasis [18,19]. Prolonged or excessive stress can disrupt coping mechanisms, leading to distress and hyperactivity of the sympathetic-adrenal-medullary system (SAM) as the body attempts to manage escalating demands. In such circumstances, neither the vagal system nor the negative feedback mechanism of α_2 -adrenergic receptors will effectively reduce the release of norepinephrine [17–19]. Elevated concentrations may escalate to norepinephrine overload, reinforcing a hypervigilant defensive coping state. Research suggests that prolonged activation of the SAM system and/or norepinephrine overload can intensify vasoconstriction, modify cardiovascular stress responses, and exacerbate the risk of hypertension, endothelial dysfunction, and atherosclerosis [20,21].

In a study conducted in the USA, the prevalence of insomnia was determined as 14.7%. The study also revealed that the largest group suffering from insomnia were working people

and that women had more insomnia problems than men [22]. A recent meta-analysis study clearly showed that insomnia is a risk factor that increases the risk ratio of hypertension by approximately two times and revealed that it causes severe phenotypes [23]. Other research has shown that this condition not only causes hypertension but also causes many conditions such as atrial fibrillation, coronary artery disease, and heart failure [24]. Another study showed that mental health problems such as major depression and attention deficit and hyperactivity disorder, in addition to insomnia, increase the likelihood of cardiovascular diseases, and showed a correlation between the use of antidepressants in patients with these diseases and the development of various cardiovascular diseases [25].

3. Measurement of Stress

The impact of stress on health spans the entire lifespan, yet consensus regarding the most pertinent types and dimensions of stress for human health and disease remains elusive. This complexity arises from the nuanced nature of stress, which is not a singular entity but rather a dynamic process shaped by various interactions among individual and environmental factors, historical events, current circumstances, allostatic states, and psychological as well as physiological responses. Moreover, the broad spectrum of processes contributing to stress includes numerous factors that are individually labeled as stressors. Advancing stress science necessitates the adoption of a unified conceptual framework integrating epidemiological, affective, and psychophysiological perspectives, alongside the implementation of precise terminology to describe stress measures accurately [26].

Numerous techniques are available for measuring stress, encompassing self-reporting, external observation, and biomarkers. While traditional methods like self-completion questionnaires and interviews persist, advancements in technology, such as mobile health applications on smartphones and wearable devices, offer more accurate monitoring of specific stress exposures. Biomarker measurement involves assessing stress on a moment-to-moment basis, such as by evaluating salivary cortisol, or summarizing it over longer periods, like a 3-month cortisol assay via hair sample analysis. Innovations like mobile electrochemical sensors and biosensors facilitate the real-time, noninvasive monitoring of electrolytes and metabolites in sweat or saliva [27].

4. Cardiac Manifests of Stress

Left ventricular hypertrophy (LVH) develops in an adaptation process to compensate wall stress, but all LVH cases are not adaptive in the disease course and reflect a preclinical heart disease [28]. Patients with mild and moderate hypertension could have abnormal cardiac septum wall thickness, where the septal base is thicker than the mid-apical part. Therefore, focal hypertrophy in hypertensive patients could signal the early stages of LV remodeling [29]. Animal and human pathophysiological data investigations of geometric and functional cardiac biomarkers highly demonstrate the recognition of the adaptive phase of hypertensive remodeling. These findings could assist in effective time management during the course of disease [30]. The current investigations point out the detected early imaging biomarkers could be used for preventing the increasing incidence of cardiac pathologies with LV remodeling and undiagnosed heart failure [31]. Histopathologic analysis of the septal base has shown differences between no fiber disarray and hypertrophic cardiomyopathy [32]. Our previous real-time three-dimensional echocardiography findings mention a decrease in LV basal cavity volume and point out the consequence of basal septal segment hypertrophy in hypertensive LVH patients [33]. We have pointed out in other investigations that BSH induces an increase in intracavitary gradients and basal hyperfunction in the adaptive phases of hypertensive diseases.

Recently, we described the phases of hypertensive heart disease in which a compensatory adaptive phase is associated with an increased rate–pressure product, showing an increased workload and oxygen consumption prior to a sharp reduction in LV gradients and maladaptation of tissue function. Because of these differences, we suggest that focal hypertrophy, rather than primary cardiomyopathy, has a secondary or strengthening

effect on ventricular hyperfunctions. We previously observed a stress-induced dynamic of LV outflow tract obstruction in hypertensive patients with BSH. In fact, alcohol septal ablation had good results in dilating the obstruction caused by hypertensive BSH [34]. In hypertensive BSH patients with a mean age of 55, we also quantitatively confirmed a hypercontractile septal base at stress by tissue Doppler imaging combined with dobutamine stress [35,36]. Global hypertrophic patients generally have stress-induced hypercontraction, which is similar to our BSH imaging findings. This may result in a failure to diagnose coronary artery disease. It was demonstrated using microneurography and isotope dilution methodology that increased sympathetic activity is directly related to the development of hypertensive LVH. Stress-induced hypercontractility may be a reflection of preserved LV function in hypertensive LVH. In fact, using real-time three-dimensional imaging, we observed that complex mitral annulus geometry and dynamics that reflect systolic function are preserved in hypertensive patients with global hypertrophy [37]. It was suggested that hypercontractility with LV cavity obliteration may be associated with a good prognosis. Hypercontractility of the LV base was also described in stress-induced cardiomyopathy. Since this region is more predominant and hypercontractile in both hypertension and ASC, we suggested that stressed heart morphology related to a predominant LV base may be a conjunctive point of determination in clinical conditions with acute or chronic stress exposure due to increased afterload [38–40]. It is known that global remodeling and LV contractile abnormalities may occur with disease progression in elderly (older than 70) patients with hypertension as a consequence of stress [41]. We mentioned the importance of precise LV contractility evaluation and quantitative functional determination by cardiac imaging in the follow-up of patients with hypertensive disease [42]. However, it is a challenge to document the evolution of LV geometry from segmental to global remodeling and functional changes in pressure overload due to chronic hypertension in humans.

Recently, we performed a small animal study to precisely document early-stage LV remodeling and progression of pressure overload using third-generation microscopic ultrasonography [43]. In this study, microimaging showed that BSH is an early imaging biomarker in the evolution of cardiac remodeling and that in animals with transaortic constriction, an early increment in systolic velocity is primarily related to compensatory hyperfunction in the early time points (up to 4 weeks) before the development of LV dysfunction. This early finding in animals confirmed the cross-sectional imaging data found in humans regarding hypercontractility. In advanced hypertensive heart disease, more predominant and severely dysfunctional septal wall compared to free wall could be related to an earlier involvement of the septum in the progression of the disease [44]. Our animal trials on cardiac remodeling found that in mice with transverse aortic constriction, increased intracavitary left ventricular gradient is associated with a compensatory process of the development of global left ventricular hypertrophy [45]. We called this stressed heart morphology (SHM) and found it to be an early imaging biomarker of basal septal hypertrophy in the adaptive phase. We believe this biomarker may be a specific aspect not only in the hypertensive heart [33]. We mentioned the role of the basal septum in acute- and chronic-stress-induced heart diseases. The focal findings of the basal septum could be associated with increased mechanical and functional afterload conditions, including hypertension, ASC, and aortic stenosis. SHM could be associated with both mechanical- and functional-stress-induced clinical conditions due to the basal septum being the closest part of the septum affected by increased afterload [46]. The process of BSH as the first segment to undergo remodeling in response to different stress stimuli supports our SHM paradigm, which stipulates that the cardiac septum has a high sensitivity to a variety of stress stimuli, including functional and mechanical hemodynamic stressors and sympathetic overdrive [47]. SHM seems to be more than pure hemodynamic stress due to hypertension. Complex imaging findings have shown the irregular nature of human SHM compared to regular remodeling in animals. This difference is possibly due to the emotional and mental overdrive of the human cognitive system [48].

5. Cardiac Imaging Methods in Hypertensive Patients

There are many methods used in the diagnosis and evaluation of patients with hypertension, but among these methods there are also methods that produce conflicting results.

Echocardiography is the method that forms the basis of heart imaging. It can show mechanical cardiac alterations, encompassing 2D and 3D longitudinal, circumferential, and radial strains as well as area strain, which serve as dependable indicators of left ventricular systolic function. Among these parameters, global longitudinal strain appears to exhibit higher reproducibility and a greater sensitivity to changes than left ventricular ejection fraction [49]. The primary constraint of echocardiography lies in image quality. While inaccuracies stemming from geometric assumptions, particularly concerning left ventricular mass and volumes, can be addressed with 3D echocardiography, the challenge of maintaining optimal image quality persists. Beyond impeding the measurement of various parameters related to LV structure and function, a less widely acknowledged consequence of suboptimal image quality is the underestimation of LV deformation [50].

One of the methods of echocardiography is exercise echocardiography. Exercise electrocardiography is a method with low specificity, especially in patients with electrocardiographic abnormalities at rest [51]. Dobutamine stress echocardiography is a highly specific method that can be used in the diagnosis and follow-up of patients with hypertension and is better suited to these patients compared to many other methods (especially exercise electrocardiography and myocardial perfusion imaging) [52,53]. At the same time, it has been noted that dobutamine stress echocardiography has similar accuracy rates to single-photon emission computed tomography [54]. The factors associated with producing inaccurate and false-positive outcomes in exercise echocardiography in coronary disease diagnosis have undergone comprehensive research. It has been proposed that the factors predictive of false-positive results in exercise echocardiography to diagnose coronary disease encompass the female gender, elevated blood pressure at the peak of physical activity, a lower risk assessment according to the Duke score, as well as a diminished count of irregular segments and a reduced wall motion score index post exercise. Women seem to display a vulnerability to wall motion irregularities triggered by heightened blood pressure during physical exertion [55]. An interesting study suggests that concave-shaped chest wall deformities such as pectus excavatum (Modified States Index > 2.5) may give false-positive results in exercise echocardiography where the left circumflex artery lies [56,57].

Another method of cardiac imaging for hypertensive patients is cardiac magnetic resonance (CMR). In the context of hypertensive heart disease, aside from concerns related to cost and accessibility, a drawback of using cardiovascular magnetic resonance lies in the comparatively less robust evidence base for CMR-derived strains. Additionally, there is a limitation in CMR's ability to assess diastolic function, focusing primarily on the evaluation of left atrial phasic function [56]. The primary advantage of cardiovascular magnetic resonance lies in its capability to perform tissue characterization. It proves beneficial when LVH appears disproportionate to the level of blood pressure and/or the duration of hypertension, aiding in the exclusion of cardiomyopathies like hypertrophic cardiomyopathy or infiltrative disorders. Nevertheless, access to CMR remains challenging in numerous jurisdictions, and the procedure itself is time-consuming, demanding highly trained personnel [58].

6. Acute Stress Cardiomyopathy

Takotsubo or acute stress cardiomyopathy is a transient phenomenon that occurs during severe emotional stress and might be associated with BSH [59]. In this report and in previous reports, dynamic left ventricular (LV) outflow tract or LV intracavitary obstruction have been emphasized in ASC [59,60]. ASC is a well-described clinical presentation and is more frequently seen in women than in men [61]. In clinical practice, hypertension and ASC could be detected together with basal cavity narrowing due to combined basal segmental remodeling and a hypercontractile LV base [59]. Similarly, we previously documented basal cavity narrowing due to dominant BSH in hypertensive hypertrophy using real-time three-

dimensional echocardiography [62]. Therefore, the heart with ASC seems to have a more severely developed apical enlargement due to microvascular crash compared to the hypertensive heart, which also has a narrow neck and a relatively larger midapical cavity [59–62]. Hypertension is a very common health problem which can easily be missed in clinical practice. A considerable number of previously undiagnosed hypertension cases are associated with target organ damage [63]. We emphasized the similarity of LV geometry in both hypertension and ASC and called this conjunctive point of determination “stressed heart morphology” [38]. BSH can be detected by cardiac imaging independent from whether it presents with acute or chronic stress [38,39,59–63]. Furthermore, basal septal distortion has been linked to combined chronic hypertension and ASC [59,60], which is completely consistent with the paradigm of SHM and supports the occurrence of chronic stressful episodes prior to ASC (Figure 1) [38,39,59]. The severity of hypertensive LV hypertrophy is related to norepinephrine release [64] and a predominant LV base could possibly be related to intensive LV basal innervation, which has been confirmed histologically [65,66]. Consistently, ASC is associated with a predominant LV septal base and excessive emotional stimulation as well as increased catecholamine levels in circulation [67]. Nevertheless, despite the limited number of hypertension histories in ASC cases, we recently discussed the possible underestimation of both previously undiagnosed hypertension records and segmental remodeling data in echocardiographic reports [31,68,69].

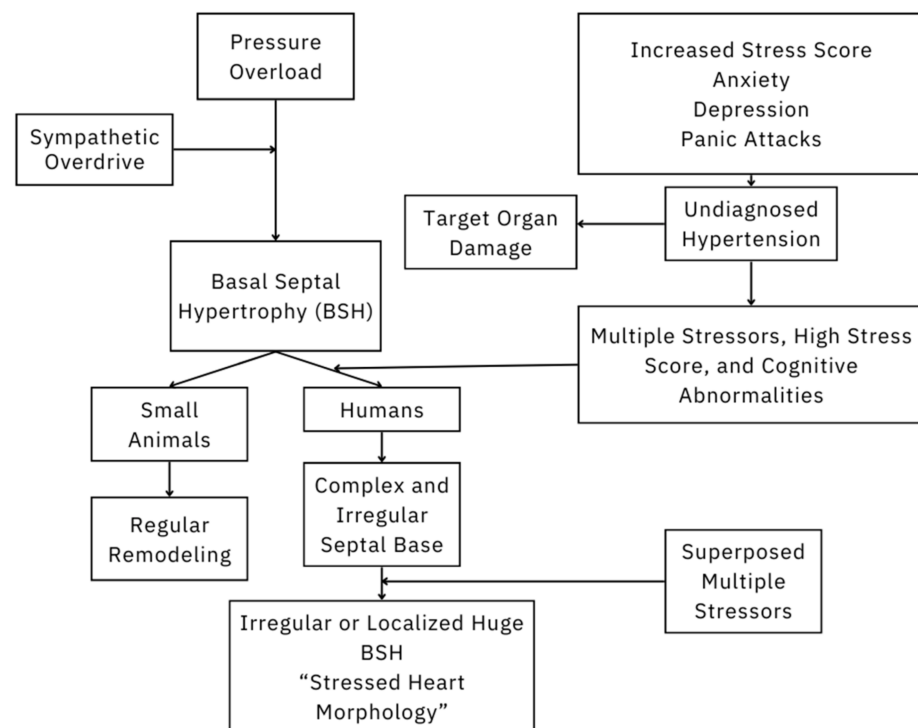


Figure 1. Schematic representation of the effect of multiple superposed stressors on cardiac remodeling.

LV basal hypercontractility is one of the diagnostic components in the clinical presentation of midapical systolic dysfunction in ASC [62]. Similar to LV basal hypercontractility in ASC, we previously quantitatively described the hyperfunction of the basal septum at stress using tissue Doppler imaging in hypertensive patients with BSH [35]. Focal hypertrophy was speculated to develop due to increased LV myocardial dynamics [70]. If ASC cases have a background of chronic hypertension due to repetitive stress, basal hypercontractility could be the case during daily life, since we quantitatively detected increased basal tissue dynamics in BSH using combined dobutamine stress and tissue Doppler imaging. In fact, recent reports have mentioned that beyond LV remodeling towards a concentric geometry,

blood pressure fluctuations are also a risk for both cerebrovascular and cardiovascular events [71].

We documented that BSH is the early imaging biomarker of stress induction due to pressure overload in small animals using third-generation microscopic ultrasonography [43]. In our study, BSH presented with increased LV intracavitary gradients due to compensatory hyperfunction in the early adaptive phase before maladaptation at the global remodeling stage [45]. These very recently documented geometric and functional validations of BSH are completely consistent with cross-sectional human data in the early phases of hypertension before myocardial dysfunction [36,70,72]. After myocardial dysfunction, however, the septal wall is more predominant and severely dysfunctional compared to the free wall, which could be related to the early involvement of the septal wall according to our previous observations [44]. Interestingly, despite the determination of BSH in cross-sectional human data, in some cases, the degree of regional hypertrophy on the septal base could be enormous [36,42,44,73–75] without any global progression compared to the regular progression of remodeling in animals [43,45]. This discrepancy could be caused by the emotional component of stress stimuli in humans compared to animals.

Basal hypercontractility results in increased velocity through the LV outflow tract and leads to dynamic obstruction in ASC. Abuarqoub A, et al. [59] also mentioned that stress-induced LV outflow tract obliteration may lead to hemodynamic instability and cardiogenic shock and lead to basal cavity narrowing like LV basal obliteration in hypertensive patients with BSH [35,70,72]. Hypercontractility is not an uncommon functional feature at stress induction in nuclear studies as well, and it could be related to the hypertension that we mentioned [73], since it is rapidly gaining clinical importance as it may help avoid undiagnosed hypertensive cases [63]. In hypertensive hypertrophy, we investigated a potential relationship between tissue hyperkinesis and dynamic LV outflow tract obstruction and found a meaningful relationship between these parameters [74]. Moreover, differential diagnosis gains importance since dynamic LV outflow tract obstruction can result in devastating hemodynamic instability that may need intensive care [59].

Finally, some patients with hypertension could have no reasonable LV basal tissue response to stress, which could be related to early involvement of septal tissue during increased wall stress due to chronic hypertension [44]. Interestingly, advanced basal septal dysfunction and even basal akinesia have been reported in ASC cases [59]. We know that basal hypercontractility is one of the diagnostic criteria of ASC and suggest that, in confusing cases, the quantitative analysis of tissue function for the differential diagnosis of ASC, beyond a comprehensive geometric evaluation, could be beneficial [42,75]. We strongly believe that the relationship between early LV remodeling and blood pressure fluctuations is extremely important. It will not be a surprise if, in the near future, ASC cases are documented to be associated with previous LV basal tissue predominance as an early imaging biomarker under chronic stress exposure, as we quantitatively validated both BSH and basal hypercontractility under stress in animal validation studies using combined third-generation microscopic ultrasonography and tissue Doppler imaging.

As we mentioned above, echocardiography reports mostly include global LV remodeling data, like in cases of LVH. However, BSH is not a widely documented imaging finding in echocardiography reports [31,68]. This leads to the absence of certainty about the underlying chronic base in ASC cases [47,48]. On the other hand, some ASC case reports include precise hemodynamic records [31], while most case reports of hemodynamic instability do not [30].

As a result, ASC is already understood as a form of acute decompensation, and we strongly believe that, in the near future, segmental data will allow us to explore its underlying chronic-stress-mediated background and confirm the relationship between ASC and chronic hypertension. Adequate segmental analysis of the left ventricular myocardium will be conducted to determine the prevalence of hypertensive BSH [76].

Funding: This research received no external funding.

Conflicts of Interest: The authors declare no conflict of interest. F.Y. is supported by American Government Fulbright Scholarship, Washington DC, USA. He has accepted only research equipment support from Novartis Pharmaceuticals.

References

1. Le Moal, M. Historical approach and evolution of the stress concept: A personal account. *Psychoneuroendocrinology* **2007**, *32*, S3–S9. [[CrossRef](#)] [[PubMed](#)]
2. Selye, H. A Syndrome Produced by Diverse Nocuous Agents. *J. Neuropsychiatry Clin. Neurosci.* **1998**, *10*, 230a–2231. [[CrossRef](#)] [[PubMed](#)]
3. Selye, H. Stress and the general adaptation syndrome. *BMJ* **1950**, *1*, 1383–1392. [[CrossRef](#)] [[PubMed](#)]
4. Beilin, L. Lifestyle and hypertension. *Am. J. Hypertens.* **1999**, *12*, 934–945. [[CrossRef](#)] [[PubMed](#)]
5. Sparrenberger, F.; Cicheler, F.T.; Ascoli, A.M.; Fonseca, F.P.; Weiss, G.; Berwanger, O.; Fuchs, S.C.; Moreira, L.B.; Fuchs, F.D. Does psychosocial stress cause hypertension? A systematic review of observational studies. *J. Hum. Hypertens.* **2009**, *23*, 12–19. [[CrossRef](#)] [[PubMed](#)]
6. Xia, N.; Li, H. Loneliness, social isolation, and cardiovascular health. *Antioxid. Redox Signal.* **2018**, *28*, 837–851. [[CrossRef](#)] [[PubMed](#)]
7. Berg, M.T.; Lei, M.K.; Beach, S.R.; Simons, R.L.; Simons, L.G. Childhood adversities as determinants of cardiovascular disease risk and perceived illness burden in adulthood: Comparing retrospective and prospective self-report measures in a longitudinal sample of African Americans. *J. Youth Adolesc.* **2020**, *49*, 1292–1308. [[CrossRef](#)] [[PubMed](#)]
8. Baldwin, J.R.; Reuben, A.; Newbury, J.B.; Danese, A. Agreement between prospective and retrospective measures of childhood maltreatment. *JAMA Psychiatry* **2019**, *76*, 584. [[CrossRef](#)] [[PubMed](#)]
9. Plante, G.E. Depression and cardiovascular disease: A reciprocal relationship. *Metabolism* **2005**, *54*, 45–48. [[CrossRef](#)]
10. Yusuf, S.; Hawken, S.; Ôunpuu, S.; Dans, T.; Avezum, A.; Lanas, F.; McQueen, M.; Budaj, A.; Pais, P.; Varigos, J.; et al. Effect of potentially modifiable risk factors associated with myocardial infarction in 52 countries (the INTERHEART study): Case-control study. *Lancet* **2004**, *364*, 937–952. [[CrossRef](#)]
11. Gu, Q.; Dillon, C.F.; Burt, V.L.; Gillum, R.F. Association of hypertension treatment and control with all-cause and cardiovascular disease mortality among US adults With Hypertension. *Am. J. Hypertens.* **2010**, *23*, 38–45. [[CrossRef](#)] [[PubMed](#)]
12. Clemow, L.P.; Pickering, T.G.; Davidson, K.W.; Schwartz, J.E.; Williams, V.P.; Shaffer, J.A.; Williams, R.B.; Gerin, W. Stress management in the workplace for employees with hypertension: A randomized controlled trial. *Transl. Behav. Med.* **2018**, *8*, 761–770. [[CrossRef](#)] [[PubMed](#)]
13. von Känel, H. Psychosomatik und arterielle hypertonie—Love it or leave it? *Ther. Umsch.* **2012**, *69*, 315–323. [[CrossRef](#)] [[PubMed](#)]
14. Linden, W.; Moseley, J.V. The Efficacy of behavioral treatments for hypertension. *Assoc. Appl. Psychophysiol. Biofeedback* **2006**, *31*, 51–63. [[CrossRef](#)] [[PubMed](#)]
15. Rutledge, T. A Quantitative review of prospective evidence linking psychological factors with hypertension development. *Psychosom. Med.* **2002**, *64*, 758–766. [[CrossRef](#)] [[PubMed](#)]
16. Motta e Motta, J.; Souza, L.N.; Vieira, B.B.; Delle, H.; Consolim-Colombo, F.M.; Egan, B.M.; Lopes, H.F. Acute physical and mental stress resulted in an increase in fatty acids, norepinephrine, and hemodynamic changes in normal individuals: A possible pathophysiological mechanism for hypertension—Pilot study. *J. Clin. Hypertens.* **2021**, *23*, 888–894. [[CrossRef](#)] [[PubMed](#)]
17. Huang, H.P.; Zhu, F.P.; Chen, X.W.; Xu, Z.Q.D.; Zhang, C.X.; Zhou, Z. Physiology of quantal norepinephrine release from somatodendritic sites of neurons in locus coeruleus. *Front. Mol. Neurosci.* **2012**, *5*, 29. [[CrossRef](#)]
18. Malan, L.; Hamer, M.; Schlaich, M.; Lambert, G.; Ziemssen, T.; Reimann, M.; Frasure-Smith, N.; Amirkhan, J.; Schutte, R.; van Rooyen, J.; et al. Defensive coping facilitates higher blood pressure and early sub-clinical structural vascular disease via alterations in heart rate variability: The SABPA study. *Atherosclerosis* **2013**, *227*, 391–397. [[CrossRef](#)] [[PubMed](#)]
19. Curtis, B.M.; O’Keefe, J.H. Autonomic tone as a cardiovascular risk factor: The dangers of chronic fight or flight. *Mayo Clin. Proc.* **2002**, *77*, 45–54. [[CrossRef](#)]
20. Scheepers, J.D.W.; Malan, L.; de Kock, A.; Malan, N.T.; Cockeran, M.; von Känel, R. Hypercoagulation and hyperkinetic blood pressure indicative of physiological loss-of-control despite behavioural control in Africans: The SABPA study. *Blood Press* **2016**, *25*, 219–227. [[CrossRef](#)]
21. De Kock, A.; Malan, L.; Potgieter, J.; Steenekamp, W.; van der Merwe, M. Metabolic syndrome indicators and target organ damage in urban active coping African and Caucasian men: The SABPA Study. *Exp. Clin. Endocrinol. Diabetes* **2012**, *120*, 282–287. [[CrossRef](#)]
22. Donald, W.; Black, M.D.; Jon, E.; Grant MDMPH, J.D. *DSM-5® Guidebook The Essential Companion to the Diagnostic and Statistical Manual of Mental Disorders*, 5th ed.; American Psychiatric Association Publishing: Washington, DC, USA, 2014.
23. Dai, Y.; Vgontzas, A.N.; Chen, L.; Zheng, D.; Chen, B.; Fernandez-Mendoza, J.; Karataraki, M.; Tang, X.; Li, Y. A meta-analysis of the association between insomnia with objective short sleep duration and risk of hypertension. *Sleep Med. Rev.* **2024**, *75*, 101914. [[CrossRef](#)]

24. Zhang, Z.; Li, L.; Zhang, Z.; Hu, Z.; Xiong, Y.; Zhou, L.; Yao, Y. Associations of 50 modifiable risk factors with atrial fibrillation using Mendelian randomization analysis. *Eur. J. Clin. Investig.* **2024**, *54*, e14194, online ahead of print. [[CrossRef](#)]
25. Cao, H.; Baranova, A.; Zhao, Q.; Zhang, F. Bidirectional associations between mental disorders, antidepressants and cardiovascular disease. *BMJ Ment. Health* **2024**, *27*, e300975.
26. Epel, E.S.; Crosswell, A.D.; Mayer, S.E.; Prather, A.A.; Slavich, G.M.; Puterman, E.; Mendes, W.B. More than a feeling: A unified view of stress measurement for population science. *Front. Neuroendocrinol.* **2018**, *49*, 146–169. [[CrossRef](#)]
27. Samson, C.; Koh, A. Stress monitoring and recent advancements in wearable biosensors. *Front. Bioeng. Biotechnol.* **2020**, *8*, 1037. [[CrossRef](#)]
28. Devereux, R.B.; Alderman, M.H. Role of preclinical cardiovascular disease in the evolution from risk factor exposure to development of morbid events. *Circulation* **1993**, *88*, 1444–1455. [[CrossRef](#)]
29. Baltabaeva, A.; Marciniak, M.; Bijmens, B.; Moggridge, J.; He, F.; Antonios, T.; Macgregor, G.; Sutherland, G. Regional left ventricular deformation and geometry analysis provides insights in myocardial remodeling in mild to moderate hypertension. *Eur. J. Echocardiogr.* **2008**, *9*, 501–508. [[CrossRef](#)]
30. Yalçın, F.; Yalçın, H.; Abraham, R.; Abraham, T.P. Hemodynamic stress and microscopic remodeling. *Int. J. Cardiol. Cardiovasc. Risk Prev.* **2021**, *11*, 200155. [[CrossRef](#)]
31. Yalçın, F.; Garcia, M.J. It is time to focus on “Segmental Remodeling” with validated biomarkers as “Stressed Heart Morphology” in prevention of heart failure. *J. Clin. Med.* **2022**, *11*, 4180. [[CrossRef](#)]
32. Belenkie, I.; MacDonald, R.P.R.; Smith, E.R. Localized septal hypertrophy: Part of the spectrum of hypertrophic cardiomyopathy or an incidental echocardiographic finding? *Am. Heart J.* **1988**, *115*, 385–390. [[CrossRef](#)]
33. Yalçın, F.; Yalçın, H.; Abraham, M.R.; Abraham, T.P. Ultimate phases of hypertensive heart disease and stressed heart morphology by conventional and novel cardiac imaging. *Am. J. Cardiovasc. Dis.* **2021**, *11*, 628.
34. Vieira, M.L.; Filho, R.M.S.; Filho, F.S.B.; Leal, S.B.; Filho, E.B.L.; Fischer, C.H.; de Souza, J.A.; Perin, M.A. Selective contrast echocardiography in percutaneous transluminal septal myocardial ablation in an elderly patient with left ventricular concentric hypertrophy. *Echocardiography* **2003**, *20*, 563–566. [[CrossRef](#)]
35. Yalçın, F.; Yiğit, F.; Erol, T.; Baltali, M.; Korkmaz, M.E.; Müderrisoğlu, H. Effect of dobutamine stress on basal septal tissue dynamics in hypertensive patients with basal septal hypertrophy. *J. Hum. Hypertens.* **2006**, *20*, 628–630. [[CrossRef](#)]
36. Yalçın, F.; Yalçın, H.; Seyfeli, E.; Akgül, F. Stress-induced hypercontractility in patients with hypertension: An interesting imaging finding. *Int. J. Cardiol.* **2010**, *143*, e1–e3. [[CrossRef](#)]
37. Yalçın, F.; Shiota, M.; Greenberg, N.; Thomas, J.D.; Shiota, T. Real time three-dimensional echocardiography evaluation of mitral annular characteristics in patients with myocardial hypertrophy. *Echocardiography* **2008**, *25*, 424–428. [[CrossRef](#)]
38. Yalçın, F.; Muderrisoğlu, H. Tako-tsubo cardiomyopathy may be associated with cardiac geometric features as observed in hypertensive heart disease. *Int. J. Cardiol.* **2009**, *135*, 251–252. [[CrossRef](#)]
39. Yalçın, F.; Yalçın, H.; Abraham, T. Stress-induced regional features of left ventricle is related to pathogenesis of clinical conditions with both acute and chronic stress. *Int. J. Cardiol.* **2010**, *145*, 367–368. [[CrossRef](#)]
40. Yalçın, F.; Yalçın, H.; Abraham, T.P. Exercise hypertension should be recalled in basal septal hypertrophy as the early imaging biomarker in patients with stressed heart morphology. *Blood Press. Monit.* **2020**, *25*, 118–119. [[CrossRef](#)]
41. Tan, Y.T.; Wenzelburger, F.; Lee, E.; Heatlie, G.; Frenneaux, M.; Sanderson, J.E. Abnormal left ventricular function occurs on exercise in well-treated hypertensive subjects with normal resting echocardiography. *Heart* **2010**, *96*, 948–955. [[CrossRef](#)]
42. Yalçın, F.; Yalçın, H.; Küçükler, N.; Abraham, T.P. Quantitative left ventricular contractility analysis under stress: A new practical approach in follow-up of hypertensive patients. *J. Hum. Hypertens.* **2011**, *25*, 578–584. [[CrossRef](#)] [[PubMed](#)]
43. Yalçın, F.; Kucukler, N.; Cingolani, O.H.; Mbiyangandu, B.; Sorensen, L.; Pinheiro, A.; Abraham, M.R.; Abraham, T.P. Evolution of ventricular hypertrophy and myocardial mechanics in physiological and pathological hypertrophy. *J. Appl. Physiol.* **2019**, *126*, 354–362. [[CrossRef](#)] [[PubMed](#)]
44. Yalçın, F.; Topaloglu, C.; Kuçukler, N.; Ofgeli, M.; Abraham, T.P. Could early septal involvement in the remodeling process be related to the advance hypertensive heart disease? *IJC Heart Vasc.* **2015**, *7*, 141–145. [[CrossRef](#)] [[PubMed](#)]
45. Yalçın, F.; Kucukler, N.; Cingolani, O.; Mbiyangandu, B.; Sorensen, L.L.; Pinheiro, A.C.; Abraham, M.R.; Abraham, T.P. Intracavitary gradients in mice with early regional remodeling at the compensatory hyperactive stage prior to lv tissue dysfunction. *J. Am. Coll. Cardiol.* **2020**, *75*, 1585. [[CrossRef](#)]
46. Yalçın, F.; Abraham, R.; Abraham, T.P. Myocardial aspects in aortic stenosis and functional increased afterload conditions in patients with stressed heart morphology. *Ann. Thorac. Cardiovasc. Surg.* **2021**, *27*, 332–334. [[CrossRef](#)]
47. Yalçın, F.; Abraham, R.; Abraham, T.P. Basal septal hypertrophy: Extremely sensitive region to variety of stress stimuli and stressed heart morphology. *J. Hypertens.* **2022**, *40*, 626–627. [[CrossRef](#)]
48. Yalçın, F.; Melek, I.; Mutlu, T. Stressed heart morphology and neurologic stress score effect beyond hemodynamic stress on focal geometry. *J. Hypertens.* **2022**, *40* (Suppl S1), e79. [[CrossRef](#)]
49. Mohamed, A.A.; Arifi, A.A.; Omran, A. The basics of echocardiography. *J. Saudi Heart Assoc.* **2010**, *22*, 71–76. [[CrossRef](#)] [[PubMed](#)]
50. Nagata, Y.; Kado, Y.; Onoue, T.; Otani, K.; Nakazono, A.; Otsuji, Y.; Takeuchi, M. Impact of image quality on reliability of the measurements of left ventricular systolic function and global longitudinal strain in 2D echocardiography. *Echo Res. Pract.* **2018**, *5*, 28–39. [[CrossRef](#)]

51. Maltagliati, A.; Berti, M.; Muratori, M.; Tamborini, G.; Zavalloni, D.; Berna, G.; Pepi, M. Exercise echocardiography versus exercise electrocardiography in the diagnosis of coronary artery disease in hypertension. *Am. J. Hypertens.* **2000**, *13*, 796–801. [[CrossRef](#)]
52. Fragasso, G.; Lu, C.; Dabrowski, P.; Pagnotta, P.; Sheiban, I.; Chierchia, S.L. Comparison of stress/rest myocardial perfusion tomography, dipyridamole and dobutamine stress echocardiography for the detection of coronary disease in hypertensive patients with chest pain and positive exercise test. *J. Am. Coll. Cardiol.* **1999**, *34*, 441–447. [[CrossRef](#)]
53. Astarita, C.; Pálinskás, A.; Nicolai, E.; Maresca, F.S.; Varga, A.; Picano, E. Dipyridamole-atropine stress echocardiography versus exercise SPECT scintigraphy for detection of coronary artery disease in hypertensives with positive exercise test. *J. Hypertens.* **2001**, *19*, 495–502. [[CrossRef](#)]
54. Elhendy, A.; Geleijnse, M.L.; van Domburg, R.T.; Bax, J.J.; Nierop, P.R.; Beerens, S.A.M.; Valkema, R.; Krenning, E.P.; Ibrahim, M.M.; Roelandt, J.R.T.C. Comparison of dobutamine stress echocardiography and technetium-99m sestamibi single-photon emission tomography for the diagnosis of coronary artery disease in hypertensive patients with and without left ventricular hypertrophy. *Eur. J. Nucl. Med. Mol. Imaging* **1997**, *25*, 69–78. [[CrossRef](#)]
55. Shin, J.-H.; Shiota, T.; Kim, Y.-J.; Kwan, J.; Qin, J.X.; Eto, Y.; Rodriguez, L.; Thomas, J.D. False-positive exercise echocardiograms: Impact of sex and blood pressure response. *Am. Heart J.* **2003**, *146*, 914–919. [[CrossRef](#)]
56. Sonaglioni, A.; Nicolosi, G.L.; Rigamonti, E.; Lombardo, M.; Gensini, G.F.; Ambrosio, G. Does chest shape influence exercise stress echocardiographic results in patients with suspected coronary artery disease? *Intern. Emerg. Med.* **2022**, *17*, 101–112. [[CrossRef](#)]
57. Sonaglioni, A.; Lombardo, M.; Nicolosi, G.L.; Grasso, E.; Ambrosio, G. The wide spectrum of determinants of false-positive results on exercise stress echocardiography. *J. Cardiovasc. Med.* **2023**, *24*, 585–588. [[CrossRef](#)]
58. Tadic, M.; Cuspidi, C.; Marwick, T.H. Phenotyping the hypertensive heart. *Eur. Heart J.* **2022**, *43*, 3794–3810. [[CrossRef](#)]
59. Abuarqoub, A.; Garis, R.; Shaaban, H.; Khaddash, I.; Shamoan, F. Takotsubo cardiomyopathy with basal hypertrophy and outflow obstruction in a patient with bowel ischemia. *Int. J. Crit. Illn. Inj. Sci.* **2018**, *8*, 44. [[CrossRef](#)]
60. Azzarelli, S.; Galassi, A.R.; Amico, F.; Giacoppo, M.; Argentino, V.; Fiscella, A. Intraventricular obstruction in a patient with tako-tsubo cardiomyopathy. *Int. J. Cardiol.* **2007**, *121*, e22–e24. [[CrossRef](#)]
61. Sharkey, S.W.; Lesser, J.R.; Zenovich, A.G.; Maron, M.S.; Lindberg, J.; Longe, T.F.; Maron, B.J. Acute and reversible cardiomyopathy provoked by stress in women from the United States. *Circulation* **2005**, *111*, 472–479. [[CrossRef](#)]
62. Yalçın, F.; Shiota, T.; Odabashian, J.; Agler, D.; Greenberg, N.L.; Garcia, M.J.; Lever, H.M.; Thomas, J.D. Comparison by real-time three-dimensional echocardiography of left ventricular geometry in hypertrophic cardiomyopathy versus secondary left ventricular hypertrophy. *Am. J. Cardiol.* **2000**, *85*, 1035–1038. [[CrossRef](#)] [[PubMed](#)]
63. Korhonen, P.E.; Kautiainen, H.; Järvenpää, S.; Kantola, I. Target organ damage and cardiovascular risk factors among subjects with previously undiagnosed hypertension. *Eur. J. Prev. Cardiol.* **2014**, *21*, 980–988. [[CrossRef](#)] [[PubMed](#)]
64. Schlaich, M.P.; Kaye, D.M.; Lambert, E.; Sommerville, M.; Socratous, F.; Esler, M.D. Relation between cardiac sympathetic activity and hypertensive left ventricular hypertrophy. *Circulation* **2003**, *108*, 560–565. [[CrossRef](#)] [[PubMed](#)]
65. Holmgren, S.; Abrahamsson, T.; Almgren, O. Adrenergic innervation of coronary arteries and ventricular myocardium in the pig: Fluorescence microscopic appearance in the normal state and after ischemia. *Basic Res. Cardiol.* **1985**, *80*, 18–26. [[CrossRef](#)] [[PubMed](#)]
66. Kawano, H.; Okada, R.; Yano, K. Histological study on the distribution of autonomic nerves in the human heart. *Heart Vessel.* **2003**, *18*, 32–39. [[CrossRef](#)] [[PubMed](#)]
67. Wittstein, I.S.; Thiemann, D.R.; Lima, J.A.C.; Baughman, K.L.; Schulman, S.P.; Gerstenblith, G.; Wu, K.C.; Rade, J.J.; Bivalacqua, T.J.; Champion, H.C. Neurohumoral features of myocardial stunning due to sudden emotional stress. *N. Engl. J. Med.* **2005**, *352*, 539–548. [[CrossRef](#)] [[PubMed](#)]
68. Yalçın, F.; Abraham, M.R.; Abraham, T.P. It is time to assess left ventricular segmental remodelling in aortic stenosis. *Eur. Heart J. Cardiovasc. Imaging* **2022**, *23*, e299–e300. [[CrossRef](#)]
69. Yalçın, F.; Yalçın, H.; Küçükler, N.; Arslan, S.; Akkuş, O.; Kurtul, A.; Abraham, M.R. Basal septal hypertrophy as the early imaging biomarker for adaptive phase of remodeling prior to heart failure. *J. Clin. Med.* **2021**, *11*, 75. [[CrossRef](#)]
70. Krasnow, N. Subaortic septal bulge simulates hypertrophic cardiomyopathy by angulation of the septum with age, independent of focal hypertrophy. An echocardiographic study. *J. Am. Soc. Echocardiogr.* **1997**, *10*, 545–555. [[CrossRef](#)]
71. Guzik, B.M.; McCallum, L.; Zmudka, K.; Guzik, T.J.; Dominiczak, A.F.; Padmanabhan, S. Echocardiography predictors of survival in hypertensive patients with left ventricular hypertrophy. *Am. J. Hypertens.* **2021**, *34*, 636–644. [[CrossRef](#)]
72. Yalçın, F.; Muderrisoglu, H.; Korkmaz, M.E.; Ozin, B.; Baltali, M.; Yigit, F. The effect of dobutamine stress on left ventricular outflow tract gradients in hypertensive patients with basal septal hypertrophy. *Angiology* **2004**, *55*, 295–301. [[CrossRef](#)] [[PubMed](#)]
73. Yalçın, F.; Schindler, T.; Abraham, T.P. Hypertension should be ruled out in patients with hyperdynamic left ventricle on radionuclide myocardial perfusion imaging, diastolic dysfunction and dyspnea on exertion. *IJC Heart Vasc.* **2015**, *7*, 149–150. [[CrossRef](#)] [[PubMed](#)]
74. Yalçın, F.; Kucukler, N.; Haq, N.; Abraham, T.P. Evaluation of regional myocardial dynamics in left ventricular hypertrophy secondary to essential hypertension. *J. Am. Coll. Cardiol.* **2011**, *57*, E2000. [[CrossRef](#)]

-
75. Yalçın, F.; Çağatay, B.; Küçükler, N.; Abraham, T.P. Geometric and functional aspects in hypertension and takotsubo: Importance of basal septal hypertrophy. *Eur. J. Prev. Cardiol.* **2023**, *30*, 1996–1997. [[CrossRef](#)]
 76. Yalcin, F.; Kucukler, N.; Abraham, T.P.; Garcia, M.J. Can quantitative regional myocardial dynamics contribute to the differential diagnosis of acute stress cardiomyopathy? *Anadolu Kardiyol. Derg. Anatol. J. Cardiol.* **2012**, *12*, 71–74. [[CrossRef](#)]

Disclaimer/Publisher’s Note: The statements, opinions and data contained in all publications are solely those of the individual author(s) and contributor(s) and not of MDPI and/or the editor(s). MDPI and/or the editor(s) disclaim responsibility for any injury to people or property resulting from any ideas, methods, instructions or products referred to in the content.